

# URGENT CARING

A PEER-REVIEWED PUBLICATION

Empowering Clinicians,  
Enhancing Quality of Care

Published quarterly and includes editorials, case studies, best practices, imaging challenges, expert insights, tricks of the trade, Urgent Updates and more...



THIRD QUARTER, 2024

Volume 8, Issue 3



COLLEGE OF  
URGENT CARE  
MEDICINE



URGENT CARE  
COLLEGE OF  
PHYSICIANS

## Table of Contents

A Message from CUCM President, Cesar Mora Jaramillo, MD, FAAFP, FCUCM.....	2
<i>Clinical Thought Leaders and the Future of Urgent Care Medicine</i> .....	2
From the Editors-in-Chief .....	4
Editorial: HealthTrackRx Predictions for the 2024-2025 Respiratory Season .....	7
Member Insights: Creating a CME Eligible Education Conference.....	9
CME Eligible: Case Study: Swollen Leg on a Friday Night.....	12
CME Eligible: Images in Urgent Care .....	18
CME Eligible: Tricks of the Trade: What About Smart Rings? .....	19
DOT Exam Column.....	21
CME Eligible: EKG Challenge: Is it Really Sinus Tachycardia?.....	23
CME Eligible: Best Practice from the Urgent Care College of Physicians .....	25
CME Eligible: Q&A: What is the Role of D-Dimer in Ruling Out DVT? .....	29
Insights: Organizations Driving Innovation in Urgent Care Education .....	31
CME Eligible: Legal Lessons: Testicular Torsion—A Case with a Twist .....	31
CME Eligible: Managing Shoulder Injuries in Urgent Care: Fracture, Dislocation, and Overuse	34
<i>CME Eligible: Diagnosis and Management of Acute Otitis Media and Acute Otitis Externa for the Urgent Care Clinician</i> .....	49
Urgent Updates.....	55
<i>CME Eligible: General Urgent Care Medicine Highlights</i> .....	55
<i>CME Eligible: Urgent Updates in Pediatric Research</i> .....	58
Cause for Applause Q3 2024.....	61
Advertising in Urgent Caring.....	63



## Clinical Thought Leaders and the Future of Urgent Care Medicine

As I reflect on our recent Clinical Consortium meeting, I am filled with optimism and a renewed sense of purpose. Gathering with thought leaders from across the nation set a strategic vision for the future of Urgent Care medicine, while providing an invaluable opportunity to exchange ideas and discuss challenges. The collaborative spirit and the wealth of expertise present were truly inspiring, reaffirming our commitment to advancing the specialty of Urgent Care medicine.

One of the key themes that emerged from our discussions was the importance of developing standard Urgent Care clinical quality metrics. As a group, we must raise the bar and set quality metrics across the nation. The consortium emphasized the need for continued investment in this area. Unlike other healthcare settings, Urgent Care centers face unique challenges and opportunities, and establishing standardized metrics will enable us to consistently measure performance, identify areas for improvement and ensure the delivery of exceptional care. Our discussions highlighted the need for collaboration in defining these metrics and developing and implementing benchmarks that can drive continuous improvement and elevate the standard of care across our field.

Another critical topic discussed was the need to address burnout to support clinician success. The pressures and demands of our work can take a significant toll, leading to decreased job satisfaction and, ultimately, affecting patient care. The team will work on providing access to a clinician burnout coaching “pilot program” to our frontlines. Burnout is an area that needs attention, and we must voice the concerns driving this but also support our frontlines with resources that are proven effective.

Lastly, the Consortium underscored the importance of waste reduction in Urgent Care settings, particularly focusing on developing a process for decreasing waste for sharps and red bag disposal. Medical waste, including sharps and biohazard materials, represents a significant environmental and financial burden. Our discussions centered on best practices for minimizing this waste through the adoption of efficient disposal protocols and innovative technologies. By implementing a comprehensive waste reduction strategy, we can not only reduce costs but also lessen our environmental footprint. This initiative aligns with our commitment to sustainability and operational efficiency, ensuring that we provide safe and effective care while being mindful of our ecological impact.

It is a true honor to work with a group of brilliant people who share the same energy and vision to advance the specialty of Urgent Care. The recent Consortium meeting was a testament to the collective dedication and innovation within our field. As we move forward, let us embrace the insights and strategies shared, working together to elevate the practice of Urgent Care medicine. The future is bright, and with our combined efforts, we can continue to make significant strides in providing exceptional care to our communities. A heartfelt thank you to Dr. Lindsey Fish, Chair of the Clinical Consortium, and the entire planning team for the successful event!

Sincerely,



Cesar Mora Jaramillo, MD, FAAFP, FCUCM

## From the Editors-in-Chief

Welcome to this edition of Urgent Caring and thank you for reading. We hope you enjoy this publication and learn something to help reinforce your practice. Know someone who might be interested in reading as well? Pass it along! Medicine has always been a profession of mentorship and apprenticeship; the way we learn is from each other, so share your knowledge, encourage a colleague to join UCA, CUCM and UCCOP, and take advantage of all the member benefits and resources available.

Let's talk about advancing the specialty of Urgent Care medicine. What does that mean exactly? First, some background. In the house of medicine, there are specialties that are recognized by the American Medical Association (AMA) and the Accreditation Council for Graduate Medical Education (ACGME) (think emergency medicine, family medicine, surgery) and those that are not. Examples of these would be Urgent Care, concierge medicine and other super-specialized specialties such as fetal surgery and epilepsy medicine.

Why is Urgent Care not a specialty? Urgent Care medicine was born out of the entrepreneurial spirit of physicians from other specialties who saw the need for convenient, episodic medical care outside of primary care offices and emergency departments (ED). Most clinicians have trained in other specialties such as emergency medicine or family medicine and rarely internal medicine or surgery. As a specialty of medicine, we are in our infancy and not yet recognized as being different from any other specialty. But at this point in our development, are we really the same as family medicine or emergency medicine? Do we do anything unique or different that would make us worthy of being our own independent specialty of medicine?

Many of us would agree that we do. As primary care clinicians experience shortages and are more interested in managing chronic diseases such as hypertension and diabetes than acute illness, and emergency departments are wanting to see only emergencies, we fill the niche of "subacute" medicine. We treat those patients who need to be seen in a few hours to a few days, not necessarily immediately. We see the upper respiratory symptoms, the walking wounded, the "I just want to get this checked" that really shouldn't wait six weeks for the next primary care appointment and really shouldn't go to the ED. We are experts in the URI, the uncomplicated COVID-19, the bumps, bruises, sprains and strains, and the rashes. We are a point of access into the healthcare system for those who have no primary care. We work extended hours and weekends to see these things. Urgent Care medicine should be a specialty.

To be a recognized specialty, you need to do something no one else does. Check. You need to have a national organization representing your specialty. Check. You need to have a list of skill sets. Check. You need a journal and original research. Check. But here's where it gets tricky. You need to have a training program. Well, we have a few for new clinicians, including NPs and PAs. This will need some work. You need a board exam, which is also tricky. And you need a big organization like the AMA to get behind you.

The CUCM Advancing the Specialty Task Force is working on all these things. We are working on solidifying training programs, shoring up our standards and scope of practice, figuring out the board exam issue, fostering original research, speaking with the national PA and NP organizations to develop CAQs and applying to the AMA for Specialty Services Society recognition. This application is the first step to becoming a full member and having a delegate for Urgent Care medicine within the AMA.



[www.urgentcarecollege.org](http://www.urgentcarecollege.org)



[www.uccop.org](http://www.uccop.org)

Why do we need this? Organization is power. When we do these things, we say, “We are here to stay. We have a commitment to certain standards. We want to be the best clinicians we can be.” Having a voice in the AMA gives us access to the most powerful medical organization in the country which opens the door to lobbying for better reimbursement and a voice with the payers. Being independent puts us in demand and people recognize what we do as important. It gives us a voice with CMS and other organizations. And it elevates us from the “doc in the box up the street” to a bona fide medical practice we can be proud of.

How can you help? Small steps. Join the AMA using the link below. We need at least 20% of our physician members to be AMA members. Become a fellow in the College. The more of us who are recognized as experts in our field the better. Join a UCA or CUCM committee. Write something for this publication or the Journal of Urgent Care Medicine (JUCM). Does your Urgent Care have a training program? Email us so we can work together! Plan to go to the annual UCA chapter meetings in the fall and the Urgent Care Convention each spring. We implore you to join us and get involved.

Together we can advance the specialty of Urgent Care medicine!

Links:

[AMA Membership, Join or Renew](#)

[CUCM Fellowship Information](#)

[Urgent Care Association](#)

[Urgent Caring Publication](#)

[Journal Of Urgent Care Medicine](#)



Tracey Quail Davidoff, MD, FCUCM



Cesar Mora Jaramillo, MD, FAAFP, FCUCM

### *Designation Statement*

The Urgent Care Association (UCA) designates this enduring material activity for a maximum of 3 *AMA PRA Category 1 Credit(s)*<sup>™</sup>. Physicians should claim credits only commensurate with the extent of their participation in the activity. Credits may be claimed for one year from the date of release of this issue.

### *Accreditation Statement*

This activity has been planned and implemented in accordance with the accreditation requirement and policies of the Accreditation Council for Continuing Medical Education (ACCME) through Urgent Care Association and the College of Urgent Care Medicine. UCA is accredited by the ACCME to provide continuing medical education for physicians.

### *Financial Disclosures*

**List of persons involved in educational content: speakers, reviewers, planners and authors that have relevant financial relationship(s) with ineligible companies to disclose are:**

Jennifer Carlquist has disclosed a relationship as a consultant with Zoll.

*All relationships listed have been mitigated by peer review and disclosure.*

All planners: Cesar Mora Jaramillo, MD, FAAFP, FCUCM; Tracey Davidoff, MD, FCUCM; Laurel Stoimenoff, PT; Melodie Turk, MHA; and Marley Haus have no ineligible relationships to disclose

All other authors of CME eligible content have no relevant financial relationships to disclose.

## Editorial: HealthTrackRx Predictions for the 2024-2025 Respiratory Season

**Janie French, PhD**

The 2024-2025 respiratory season has kicked off with intensity as SARS-CoV-2 (COVID-19) infections surge to levels not seen in over a year. In response to this significant development, the HealthTrackRx team has utilized last year's positivity data to make critical predictions for the upcoming respiratory season.

### SARS-CoV-2 (COVID-19)

Last respiratory season, peak positivity for COVID-19 infections occurred during the summer, with a smaller but still significant rise in cases during January.

**Prediction 1:** We predict that infections caused by COVID-19 this winter will peak again in January.

**Prediction 2:** COVID-19 will have a maximum positivity rate of 12%, a lower positivity rate than the summer peak of 15.9%.

### Enterovirus D68

Enterovirus D68 is unusual because it circulates only every other year, typically peaking in August. This virus can be particularly serious due to its association with acute flaccid myelitis. The last year it circulated was 2022, when it peaked in August and trailed off by late October.

**Prediction 3:** We predict that there will be a circulation of Enterovirus D68 this year.

**Prediction 4:** We expect this virus to peak at over 8% positivity near the end of August.

**Prediction 5:** EVD68 positivity will trail back down to nearly 0% positivity by late October.

### Influenza

In the 2023-2024 season, influenza positivity first rose above 2% the week of October 16. It peaked at 15.3% during the week of December 25 and slowly trailed off, returning to less than 2% positivity during the week of April 29. The slow trailing off appeared primarily caused by a surge in Influenza B virus cases, while Influenza A virus infections caused the early peak. In the southern hemisphere, influenza virus infections in Australia show positivity increasing in the typical time frame and at a level higher than the previous year. These cases were also primarily caused by influenza A virus ([link](#)).

**Prediction 6:** We predict that influenza cases will rise in the U.S. starting in mid-October and peak in late December to early January.

**Prediction 7:** The influenza A virus will primarily cause these cases and reach a maximum positivity of around 17%.

### Respiratory Syncytial Virus (RSV)

Australia also witnessed an increase in RSV cases this year compared to the prior season. During the 2023-2024 respiratory season, HealthTrackRx saw a maximum RSV positivity of 8.3%, which occurred at the end of November.

**Prediction 7:** Based on the data, we predict that the U.S. will see a larger peak of RSV this year, reaching a maximum positivity of 10%.



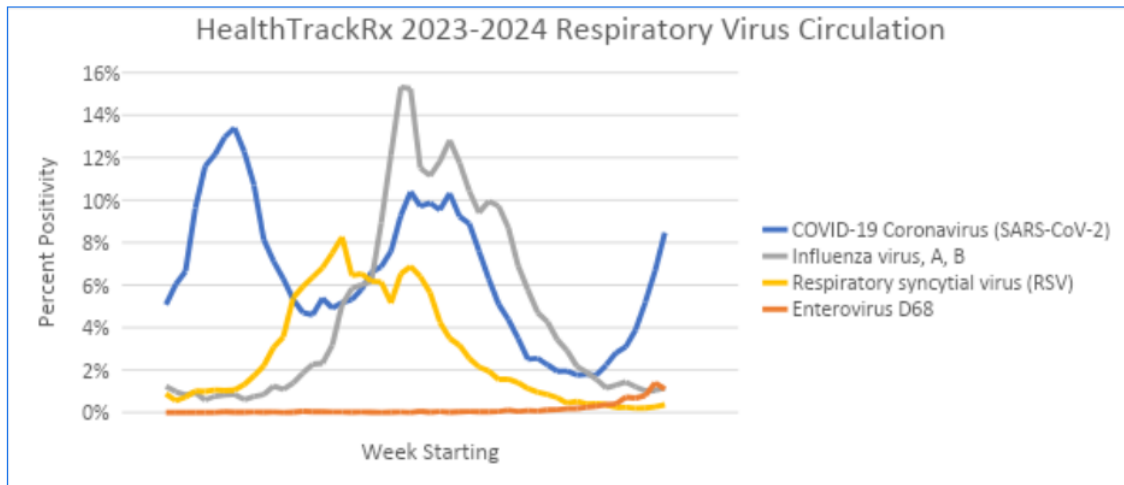
[www.urgentcarecollege.org](http://www.urgentcarecollege.org)



[www.uccop.org](http://www.uccop.org)

**Prediction 8:** We also expect that the timing will be like the typical circulation patterns of RSV, with positivity starting to increase in September and peaking in early November.

Understanding respiratory virus circulation is crucial for supporting better patient care by identifying periods when patients are at an increased risk of infection from viruses that cause severe symptoms. Follow along with us this respiratory season as we share up-to-date respiratory trends every two weeks. The illustration below reflects our data from the 2023-24 season.



HealthTrackRx 2023-2024 Respiratory Virus Circulation

This article shows observed trends in HealthTrackRx testing-positivity data. It does not convey medical advice and is provided for informational purposes only. Individuals experiencing respiratory symptoms should consult with their healthcare clinician.

## Member Insights: Creating a CME Eligible Education Conference

### Heather Zamarron, PA-C, MPAS

On September 22, 2023, I stood in front of 60 fellow APPCs with butterflies in my stomach to welcome them to our first annual Urgent Care Educational Conference. My employer, a local Urgent Care company, tasked me with organizing a free two-day conference with these goals in mind: educating, recruiting, forming relationships with local clinicians in the community and marketing our business. After the conference's success, I believe this is something that can be used by other Urgent Care businesses and create a win-win.

My medical director, an emergency medicine physician, noticed a trend of patients being referred to the ER from local Urgent Care centers with lacerations, abscesses and other minor complaints that they could have handled in house but lacked the training to do so. In this post-pandemic world of medicine, Urgent Care has become a stepping stone for new graduates to gain experience instead of a destination for APCs. Coupled with staffing shortages, this phenomenon has increased inexperience in the Urgent Care setting. This motivated us to sponsor an educational conference.

Although I was hired to use my emergency medicine background to train and educate our new providers, we recognized the problem was more systemic, and we wanted to provide this education to more than just our clinicians.

Recognizing that the closest conferences to our area are 4–5-hour drives, we made our conference accessible to all local clinicians for free, including CME credit. Our area has several hospital-owned and privately-owned Urgent Care centers. Additionally, many surrounding rural communities staff their Emergency Departments and Family Medicine clinics with APCs, so we knew we would potentially have a large audience. After pricing a few hotel conference centers, we were fortunate that the local Physician Assistant school offered us their state-of-the-art facilities free of charge if we allowed their students to attend. Our Urgent Care organization covered the remainder of the expenses, including marketing, food and beverage, an evening reception, CME and conference swag. The total cost was about \$10,000.

Our goal was to educate local APCs on the fundamental topics of Urgent Care medicine. The finalized list included:

- Undifferentiated abdominal pain
- Geriatrics
- Neurology
- Chest pain
- EKG interpretation
- Upper and lower extremity X-rays
- Ethics
- Respiratory complaints
- Pediatrics
- Rashes

After thoughtful discussion, we decided on physicians to provide the lectures and APCs to run our hands-on workshops. This lineup allowed us to build relationships with key referral sources in our community, ensuring dynamic lectures and interdisciplinary cooperation.

Most of the lectures were from Emergency Medicine physicians, whom our Urgent Care clinicians communicate with when sending patients to a higher level of care, presented most of the lectures. We also had lectures from a local cardiologist and pediatrician, building our local referral base. We were also pleased to line up an MD/JD to provide our ethics lecture.

We used the PA school's equipment (and our ingenuity) to run procedural skills workshops. We focused on skills that readily translate to Urgent Care: suturing, IV/blood draw, splinting, I&D and EKG interpretation. Veteran Urgent Care and Emergency Department APCs ran the skills lab.

Getting CME approval was the most time-consuming and challenging part of organizing the conference. We chose AAPA for CME approval since Nurse Practitioners and Physician Assistants could earn Category 1 CME credits for the event. The application process through AAPA is quite extensive and requires several components, which include non-disclosure letters from all the lecturers and workshop leaders, the conference schedule, learning objectives for each topic, sample marketing materials, a sample evaluation form for each lecture and a sample of the CME award certificate attendees would receive. Additionally, AAPA emphasizes the inclusion of Physician Assistants in the planning and organization of the conference. Fortunately, I was the primary organizer, and several PAs facilitated the workshops.

We offered the conference to APCs and students free of charge. Our motivation was not financial. We are passionate about educating clinicians on urgent and emergency medical conditions. We also wanted to develop more personal relationships with the local medical community. Our clinicians are now more comfortable contacting any of the event's speakers for a transfer or consultation. The experience also allowed our administrative team to meet students and clinicians who may one day wish to seek employment with us.

Organizing anything for the first time will humble you and teach you important lessons. Here are just a few things we will improve at the 2nd Annual UC Educational Conference (already scheduled for this fall):

1. Alphabetize the check-in list: Although small, this oversight led to confusion and delays for our registration volunteers.
2. Get a photo release signed: We wanted to post all the great content we recorded from the conference but forgot to get individuals to sign a photo release. This year, we will add this as a part of the registration process.
3. Enhance mixer: Our biggest failure was the mixer which we held at a remote site on the evening of the first day. We hoped to interact with the attendees in a more personal setting, but few people attended. We have several ideas for improvement this year, including better advertising of the mixer event, hosting it at the lecture site and holding it immediately after the lectures.
4. Downtime slideshow: We overlooked having a slideshow playing during breaks where we could have marketed the mixer, displayed the QR codes for CME credit evaluation forms and improved aesthetics.
5. Expand marketing efforts: We had 60 attendees with minimal marketing: primarily radio ads, email, and word of mouth. This year, we plan to use social media and digital ads, utilize local APP societies and expand our email marketing list to grow our audience.

6. Content meetings: We loved the lectures our speakers gave but noticed some overlap. We will now hold meetings to discuss topics and outlines before giving the speakers their creative freedom.
7. Print outlines: Several attendees requested this, and although we provided a notebook for the avid notetakers, we will print outlines this year.

We received positive feedback from attendees, speakers, the PA School and our community. Teaching the next generation of clinicians benefits our patients, community and business. I hope our story inspires you to host an educational conference in your local community. If you would like more information on the lessons we learned, including advice on obtaining CME certification, feel free to contact me at [info@BusinessIsTheBestMedicine.com](mailto:info@BusinessIsTheBestMedicine.com).

Heather is a PA with Emergency Department and Urgent Care experience, currently working at a private Urgent Care in Texas.

Heather writes about the business of medicine at <http://www.BusinessIsTheBestMedicine.com>.



## CME Eligible: Case Study: Swollen Leg on a Friday Night

### Tatiana Havryliuk, MD

Key words: deep vein thrombosis, DVT, calf pain, leg swelling, point-of-care ultrasound, POCUS, bedside ultrasound

Note: The case in this report is hypothetical. The images provided are that of an actual de-identified patient.

#### **Introduction:**

This case report describes the management of a 52-year-old male presenting with left calf pain after a transcontinental flight, highlighting the utility of point-of-care ultrasound (POCUS) in Urgent Care settings. Recent literature suggests the growing importance of POCUS for timely diagnosis when conventional imaging is unavailable, particularly for conditions like deep vein thrombosis (DVT).

#### **Patient Information:**

A 52-year-old male with a history of hypertension presented with left calf pain persisting for three days. Pain was constant, non-radiating and worsened with movement and walking. The patient recently traveled from L.A. to N.Y., a six-hour flight. He denied any injury, recent surgeries, history of pulmonary embolism or DVT, and was not experiencing any chest pain or dyspnea. He has no significant family history. His hypertension is managed with hydrochlorothiazide with good control.

#### **Clinical Findings:**

Physical examination revealed mild tenderness in the left calf and popliteal region without swelling, erythema or warmth. The remainder of the exam was unremarkable. His vitals were within normal limits.

#### **Timeline:**

- Day 1: Onset of calf pain post-flight.
- Day 3: Presentation to Urgent Care.
- Day 3: POCUS performed.
- Day 6: D-dimer result available.

#### **Diagnostic Assessment:**

The patient's risk for a DVT was determined to be low, based on his Wells score of 0. [1] POCUS of left lower extremity was performed showing full compressibility of proximal leg veins, thus ruling out a proximal DVT (**Figure 1**). The popliteal region was further assessed with POCUS that showed absence of Baker's cyst. D-dimer was sent, and negative results were available 72 hours after patient's visit to Urgent Care.

#### **Therapeutic Interventions:**

The patient was advised to perform gentle calf stretches, remain well hydrated and take ibuprofen as needed. The presumed diagnosis of muscle strain was made.

#### **Follow-up and Outcomes:**

The D-dimer test was negative. Upon follow-up, the patient reported resolution of symptoms. No adverse events were reported.

## Discussion

POCUS allowed for immediate decision-making, avoiding unnecessary diagnostic delays.[2] Although DVT could have been ruled out by obtaining a D-dimer alone in this low-risk scenario, patient's satisfaction and availability of prompt follow-up ultrasound in case of positive D-dimer results are important to consider.

### *Evidence-Based DVT Workup*

The workup of a patient with a possible lower extremity DVT starts with calculating a Wells score. If the score falls into low to moderate-risk category (-2 to 2), then high-sensitivity D-dimer test is indicated. If the D-dimer is negative, workup can be stopped as those patients have <1% risk of having a DVT. [1, 4] If the D-dimer is positive, either whole-leg (WLUS) or proximal-leg ultrasound (PLUS) should be performed. If the ultrasound is negative, DVT is ruled out. If ultrasound is positive, anticoagulation should be initiated.

If high-sensitive D-dimer test is not available in a “timely” manner, whole-leg or proximal-leg ultrasound is indicated. If the ultrasound is negative, the DVT is ruled out in low-risk patients, however if only proximal-leg ultrasound was done on a moderate-risk patient, a repeat ultrasound should be performed.

All patients who are high-risk for a DVT (Wells score >2) should receive an ultrasound. High-sensitivity D-dimer could be used to further risk stratify the patients. For example, if D-dimer is positive but the ultrasound is negative, a repeat ultrasound should be done in one week. However, if ultrasound is negative and D-dimer is negative, a repeat ultrasound is not necessary.

Refer to **Figure 2** for a sample clinical pathway for a DVT rule-out in Urgent Care setting.

### *2-Point vs. 3-Point Proximal Leg Compression Ultrasound*

POCUS DVT scan typically includes compression of proximal deep vasculature in two regions (inguinal area (common femoral vein, saphenofemoral vein junction, confluence of deep femoral and femoral veins) and popliteal area (popliteal vein and junctions with calf veins) or three regions (add isolated femoral vein compression). It is referred to as “2-point” or “3-point” scan depending on how many regions are included in the exam. Typically, calf veins are not fully assessed at the point of care. One study found that 3-point ultrasound adds additional sensitivity for DVT in case of an isolated femoral vein clot is present [5]. However, a 2018 meta-analysis found no significant difference between 2-point and 3-point scans with sensitivity of 91% and 90%, respectively [6].

### *Whole Leg Ultrasound (WLUS) vs Proximal Leg Ultrasound (PLUS)*

Proximal leg compression POCUS has been shown to have high sensitivity and correlation with a formal vascular study (duplex or triplex with Doppler ultrasound). A study done on hospitalists showed 100% sensitivity and 95.8% specificity when using formal radiology vascular scan as the gold standard. [7] ED meta-analysis found 96% sensitivity and specificity. [8]

Note that WLUS and PLUS are not interchangeable. For example, PLUS is sufficient in a patient with low-risk Wells score whose D-dimer is positive. However, moderate-risk patients with a positive D-dimer or high-risk patients should get either a WLUS or 2 PLUS exams 5-7 days apart.

### *Other Important Considerations*

When deciding if POCUS DVT scan is indicated consider the following:

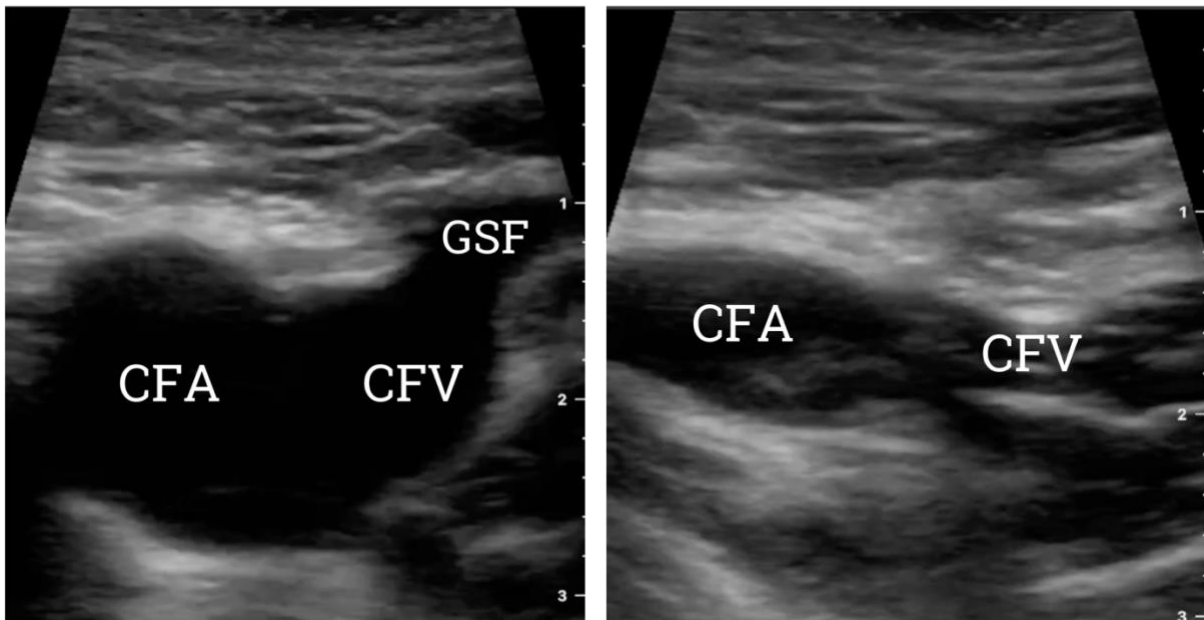
1. **Patient experience:** Will performing POCUS improve patient's experience by obtaining bedside imaging to guide treatment? Ninety-four percent of the patients receiving POCUS during primary care visit reported improved quality of care. [9] Will your patient be more reassured if POCUS is negative? Would they appreciate the cost and time saved associated with avoiding a visit to the Emergency Department (ED)?
2. **Cost savings:** Average cost for a visit to the ED for a primary care complaint is \$2,000 according to 2018 United Health Group report. [10] The 2024 nationwide Medicare global physician fee for performing unilateral lower extremity vascular scan is \$116. [11] Thus, performing POCUS in the center and avoiding referral to the ED would on average save greater than \$1,800.
3. **High-sensitivity D-dimer availability:** What is the turn-around time for the high-sensitivity D-dimer? If it's longer than 24 hours, POCUS might be the safest approach to start appropriate treatment sooner.
4. **Formal vascular study availability:** How likely is your patient to get a formal study within 24 hours? Consider weekend and holiday schedule.
5. **Patient adherence:** How likely is your patient to follow through with the imaging plan? If there is a concern that the patient might not follow through with imaging, POCUS is essential in avoiding potentially disastrous outcomes such as missed DVT and pulmonary embolism.
6. **What is your differential diagnosis, and would POCUS be useful in evaluating for potential pathology?** POCUS could be instrumental in diagnosing Baker's cyst, hematoma, or muscle tear.

Literature indicates POCUS as a reliable tool for excluding DVT in low-risk and moderate-risk patients. The combination of low Wells score and negative D-dimer provided a strong negative predictive value for DVT. POCUS in Urgent Care can expedite management, reduce healthcare costs, and improve patient experience.

#### **Patient Perspective:**

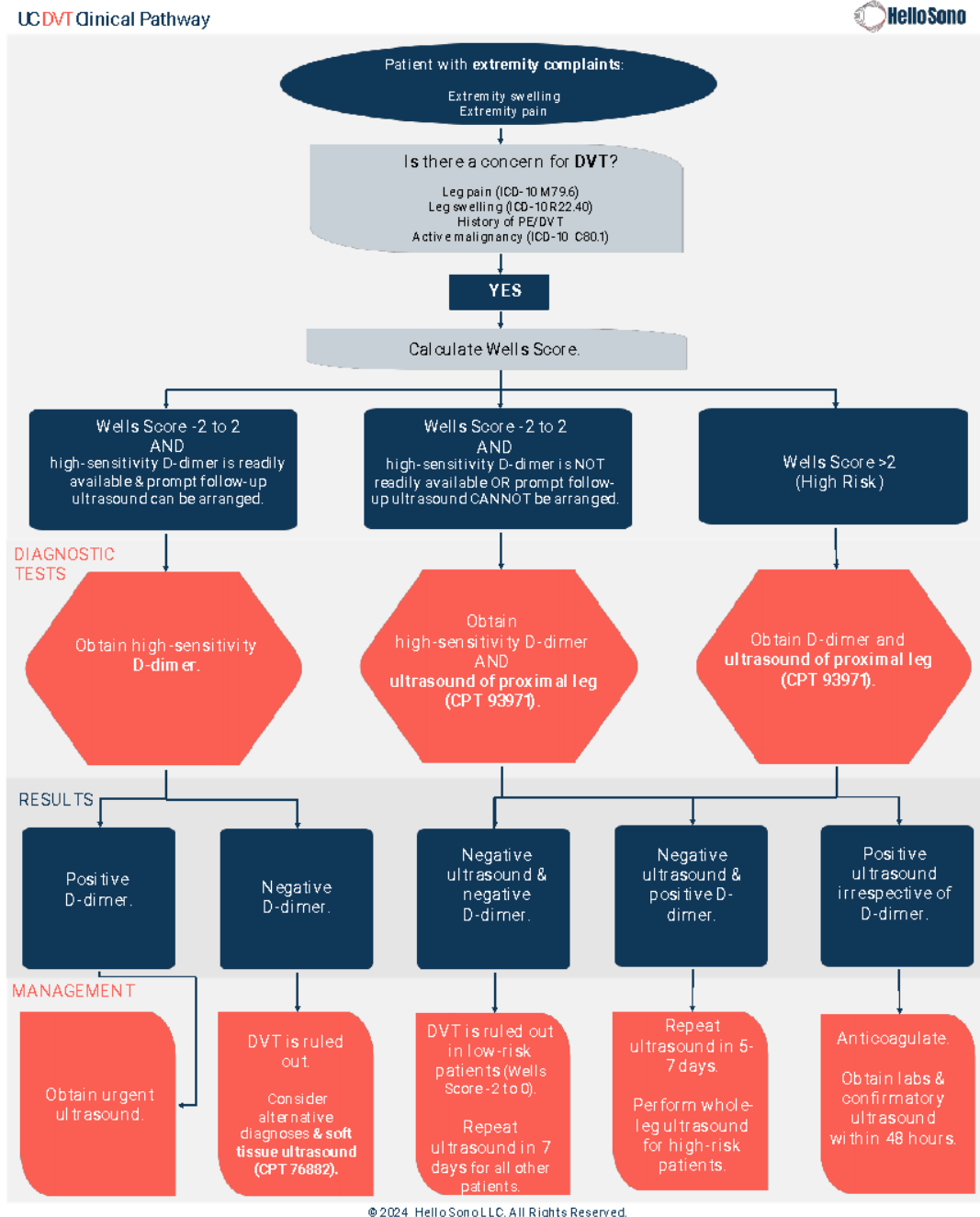
The patient appreciated the prompt assessment, reassurance, cost savings and avoiding a visit to an imaging center and the ED.

**Figure 1: Sample image of a normal POCUS exam showing full compression of the right saphenofemoral junction (SFJ).**



This figure demonstrates the junction of right Common Femoral Vein (CFV) and right Great Saphenous Vein (GSV), known as saphenofemoral junction (SFJ). Note the location of the Common Femoral Artery (CFA) lateral to the veins. On the left panel, no force is being applied on the transducer, and GSF, CFV, and CFA are all visualized on the right with force being applied and the venous structures are completely collapsed with the walls of the vessel touching, while the CFA is not. This indicates absence of a clot in the vein.

Figure 2: Sample Clinical Pathway for a DVT Rule-Out in Urgent Care



Reproduced with permission from Hello Sono Clinical Pathways.

**About the Author:**

Dr. Havryliuk is an emergency physician with over 15 years of clinical POCUS experience, past Emergency Ultrasound Director at Brooklyn Hospital in N.Y., and founder of Hello Sono. She is on the mission to empower clinicians with POCUS to take better and more efficient care of their patients.

LinkedIn: <https://www.linkedin.com/in/tatiana-havryliuk-md/>

Email: [tatiana@hellosono.com](mailto:tatiana@hellosono.com)

References:

1. MDCalc. Wells' Criteria for DVT. Accessed: August 25, 2024. [Online] Available: <https://www.mdcalc.com/calc/362/wells-criteria-dvt>
2. Rice JA, Brewer J, Speaks T, Choi C, Lahsaei P, Romito BT. The POCUS Consult: How Point of Care Ultrasound Helps Guide Medical Decision Making. *Int J Gen Med*. 2021 Dec 15;14:9789-9806. doi: 10.2147/IJGM.S339476.
3. Kearon C, de Wit K, Parpia S, Schulman S, Spencer FA, Sharma S, Afilato M, Kahn SR, Le Gal G, Shivakumar S, Bates SM, Wu C, Lazo-Langner A, D'Aragon F, Deshaies JF, Spadafora L, Julian JA. Diagnosis of deep vein thrombosis with D-dimer adjusted to clinical probability: prospective diagnostic management study. *BMJ*. 2022 Feb 15;376:e067378. doi: 10.1136/bmj-2021-067378.
4. Lim W, Le Gal G, Bates SM, Righini M, Haramati LB, Lang E, Kline JA, Chasteen S, Snyder M, Patel P, Bhatt M, Patel P, Braun C, Begum H, Wiercioch W, Schünemann HJ, Mustafa RA. American Society of Hematology 2018 guidelines for management of venous thromboembolism: diagnosis of venous thromboembolism. *Blood Adv*. 2018 Nov 27;2(22):3226-3256. doi: 10.1182/bloodadvances.2018024828.
5. Zuker-Herman R, Ayalon Dangur I, Berant R, Sitt EC, Baskin L, Shaya Y, Shiber S. Comparison between two-point and three-point compression ultrasound for the diagnosis of deep vein thrombosis. *J Thromb Thrombolysis*. 2018 Jan;45(1):99-105. doi: 10.1007/s11239-017-1595-9.
6. Lee JH, Lee SH, Yun SJ. Comparison of 2-point and 3-point point-of-care ultrasound techniques for deep vein thrombosis at the emergency department: A meta-analysis. *Medicine (Baltimore)*. 2019 May;98(22):e15791. doi: 10.1097/MD.00000000000015791.
7. Fischer EA, Kinnear B, Sall D, Kelleher M, Sanchez O, Mathews B, Schnobrich D, Olson APJ. Hospitalist-Operated Compression Ultrasonography: a Point-of-Care Ultrasound Study (HOCUS-POCUS). *J Gen Intern Med*. 2019 Oct;34(10):2062-2067. doi: 10.1007/s11606-019-05120-5.
8. Pomero F, Dentali F, Borretta V, Bonzini M, Melchio R, Douketis JD, Fenoglio LM. Accuracy of emergency physician-performed ultrasonography in the diagnosis of deep-vein thrombosis: a systematic review and meta-analysis. *Thromb Haemost*. 2013 Jan;109(1):137-45. doi: 10.1160/TH12-07-0473.
9. Andersen CA, Brodersen J, Rudbæk TR, Jensen MB. Patients' experiences of the use of point-of-care ultrasound in general practice - a cross-sectional study. *BMC Fam Pract*. 2021 Jun 18;22(1):116. doi: 10.1186/s12875-021-01459-z.
10. UnitedHealth Group. (2019). *The high cost of avoidable hospital emergency department visits*. UnitedHealth Group. Accessed: August 25, 2024. [Online] Available: <https://www.unitedhealthgroup.com/content/dam/UHG/PDF/2019/UHG-Avoidable-ED-Visits.pdf>
11. "2024 Medicare Fees for Diagnostic and Procedural POCUS for Urgent Care Centers." Accessed: August 25, 2024. [Online] Available: <https://www.hellosono.com/downloadables-1/urgent-care-2024-fees-pocus-exams>



## CME Eligible: Images in Urgent Care

Tracey Q. Davidoff, MD, FCUCM

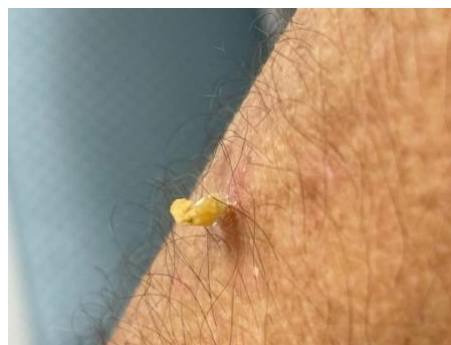

An 87-year-old male presents to Urgent Care with a skin lesion he would like to get checked out. The patient states it's been there for months and is getting bigger. It is annoying but not painful or itchy. He can't see his primary doctor for six weeks and is concerned it may be cancer. You find a yellowish lesion that is taller than it is wide, about 5 mm in diameter on the extensor surface of the mid left forearm.

Consider this image:

What is the most likely diagnosis of this growth?

- A. Skin tag
- B. Squamous cell carcinoma
- C. Cutaneous horn
- D. Viral wart
- E. Seborrheic keratosis



This lesion is a cutaneous horn. Cutaneous horns are keratinized protrusions from the surface of the skin that resemble animal “horns.” Although relatively uncommon, they can appear on the face, arms, or other sun-exposed areas of the body in older persons. Unlike animal horns, they do not have a bony center and are composed of layered keratinized cells.

Most of these growths are benign, but they may be premalignant forms of actinic keratosis, squamous cell carcinomas, basal cell carcinomas and other more rare malignancies. Discoloration at the base may be more likely to be related to a malignant diagnosis.

Cutaneous horns may be removed with excision, cryotherapy or laser ablation. Due to the possibility, although rare, of malignancy, a complete excisional biopsy is recommended with the sample sent for pathologic diagnosis. If this is not possible in your Urgent Care center, referral to dermatology for definitive care is recommended.

Source: Thiers BH, Strat N, Snyder AN, et al. Cutaneous Horn. [Updated 2024 Feb 29]. In: StatPearls [Internet]. Treasure Island (FL): StatPearls Publishing; 2024 Jan-. Available from: <https://www.ncbi.nlm.nih.gov/books/NBK563280/>



## CME Eligible: Tricks of the Trade: What About Smart Rings?

**Tracey Q. Davidoff, MD, FCUCM**  
**“MacGyver in Medicine”**

Patients frequently present to the Urgent Care center with finger or hand injuries with rings adorning their fingers. These rings need to be removed in a timely fashion before swelling sets in. Many patients either do not think of this or are wearing rings that they either do not wish to remove or have been unable to remove for a long time.

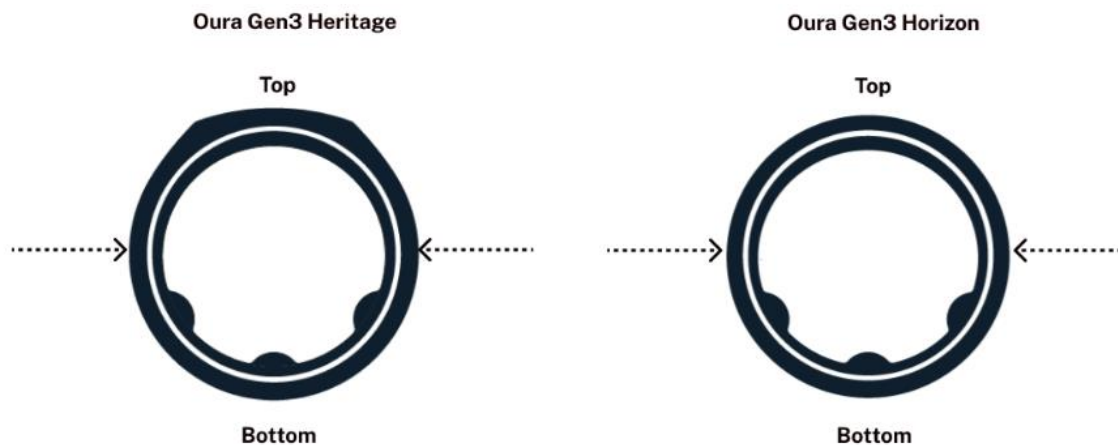
One of the latest wearable technologies is the “smart ring.” Devices that connect to your smartphone wirelessly through Bluetooth, smart rings monitor a variety of things including sleep habits, heart rate, exercise and oxygen levels. Some even detect COVID-19 or can be used for electronic payment. But what happens when the finger is injured or the patient has difficulty removing the ring?

Smart rings have electronic sensors and rechargeable batteries. If these items are damaged, obviously the ring is not functional. But can there be harm to the patient? The answer is yes. Theoretically, damage to the electronics could cause a shock, but more concerning, damage to the battery could cause burns to the skin.

According to the Oura website, the leading manufacturer of smart rings, every attempt should be made to remove the ring without cutting it. Standard removal techniques such as lubrication, elevation, ice, and compression should be attempted prior to cutting the ring. If this fails, the ring will need to be cut in two places to remove it. Standard ring cutters may or may not be effective, and a battery-operated device may be required.

Oura recommends the following steps to remove their rings:

1. Orient the ring so the sensors are on the palm side of the finger.
2. Mark two cut locations on either side of the ring (at 3 and 9 o'clock) with a pen, marker, or tape.
3. Rotate the ring to provide access to one of the cut locations.
4. Using a ring cutter, wire cutter, or similar tool, cut the ring in the marked location.
5. Rotate the ring if needed and cut the other location.



Source: [Oura Ring. Smart Ring for Fitness, Stress, Sleep & Health.](#)

Other brands may have similar methods. A review of their websites requires you to call the company to determine the best method of removal of the ring. We recommend contacting them for further information on a case-by-case basis.



COLLEGE OF  
URGENT CARE  
MEDICINE

[www.urgentcarecollege.org](http://www.urgentcarecollege.org)



URGENT CARE  
COLLEGE OF  
PHYSICIANS

[www.uccop.org](http://www.uccop.org)

**Rick Nunez, MD**

This is the inaugural edition of the DOT Exam Column in which we will explore issues and controversies related to DOT physical exams. I thought I would start with an introduction to DOT exams for those clinics and clinicians unfamiliar with them or are considering adding this service.

Commercial motor vehicle drivers must undergo a DOT physical examination to operate a vehicle in interstate commerce. Only clinicians who are registered with the National Registry of Certified Medical Examiners may offer such exams. For a clinician to obtain NRCME certification, s/he must complete an accredited training course and then pass the NRCME certification examination.

There are several million CMV drivers in the U.S., and they all require regular DOT physical exams. It is easy to see that providing this service can be an important source of revenue for Urgent Care practices – not only as a standalone source of income but as a key part of an overall occupational medicine practice.

For individual providers, having NRCME certification makes the provider more attractive to Urgent Care practices. NRCME certification is valid for 10 years, at which time the provider must recertify. NRCME certification is a federal certification, so if a center hires an NRCME certified clinician from another state, that clinician can begin performing DOT exams immediately as the certification is valid throughout the U.S.

The price charged by UC centers for a DOT exam ranges from \$55 to \$250 (usually rural areas) but typically runs in the \$90 - \$120 range. There is virtually no overhead to get started – as soon as the center’s clinicians have obtained NRCME certification, the center can begin offering them. In addition to a standard physical exam, a DOT exam includes a urine dipstick and a vision test with a Snellen chart. So, as you can see, there is minimal outlay required.

Once your Urgent Care is ready to offer DOT exams, marketing efforts will determine your success in attracting drivers. Obviously, contacting local employers with whom your center has an established relationship to let them know about your new service is key. Targeted Google Ad campaigns can be very effective in attracting DOT exam traffic, as is posting your Urgent Care on FindMyDOTExam.com. Assign an appropriate staff member to extensively reach out to local businesses. Many more employers require DOT exams for their employees than might be apparent initially. For example, FedEx drivers need to have DOT exams even if they are driving locally because the origin of the packages they are transporting means the drivers are participating in interstate commerce. In addition, many employers who do not employ interstate commercial drivers want their employees to undergo physical exams that meet the DOT exam standard.

The key to creating a sustained, successful DOT exam business is to develop a reputation for consistently appropriate DOT exam certification decisions. For example, if your center is certifying drivers who are not properly medically qualified, this puts the employer at great risk if an accident occurs. Conversely, if your center is too conservative and disqualifies drivers who can safely operate a commercial motor vehicle, then the employer is losing valuable productivity from its drivers. Employers recognize which centers certify their employees appropriately and will keep sending their drivers to those centers that make appropriate certification decisions.

*If you have any questions regarding the DOT exam or obtaining NRCME certification, feel free to email at [mail@EMedHome.com](mailto:mail@EMedHome.com).*

***Rick Nunez, MD, is medical editor for [easyDOTexam.com](http://easyDOTexam.com) and the NRCME training at [EMedHome.com](http://EMedHome.com).***



COLLEGE OF  
URGENT CARE  
MEDICINE

[www.urgentcarecollege.org](http://www.urgentcarecollege.org)



URGENT CARE  
COLLEGE OF  
PHYSICIANS

[www.uccop.org](http://www.uccop.org)




## CME Eligible: EKG Challenge: Is it Really Sinus Tachycardia?

### Jennifer Carlquist, PA-C, ER CAQ

Founder of Cardiology Made Easy

[www.conqueringcardiology.com](http://www.conqueringcardiology.com)



A 28-year-old male presented to the ER for palpitations. This started after he drank a large, caffeinated beverage and then went to play sports in the hot sun. He felt like his heart was racing, so he went home from the game early. He did have a glass of wine that night and the palpitations returned. He denied chest pain or dyspnea. He did feel as though he would pass out when he stood up.

Exam: Well dressed, well nourished, thin framed

HEENT: No exophthalmos, no nystagmus

CV: Tachycardic, regular, no murmur, no click

RR: Normal

Extremities: no edema

His pertinent labs included:

TSH 2.4 uIU/L

Drug screen negative

HS Trop 23-22 (ng/L)

Cr 0.8 mg/dL

K 4.1 (mmol/l)

Mag 2.0 (mg, dL)

ProBNP 928 (pg/mL)

His CXR showed bilateral trace effusions.

He was admitted for sinus tachycardia and suspected heart failure. He was given 40 mg furosemide IV and seen by the cardiologist.



COLLEGE OF  
URGENT CARE  
MEDICINE

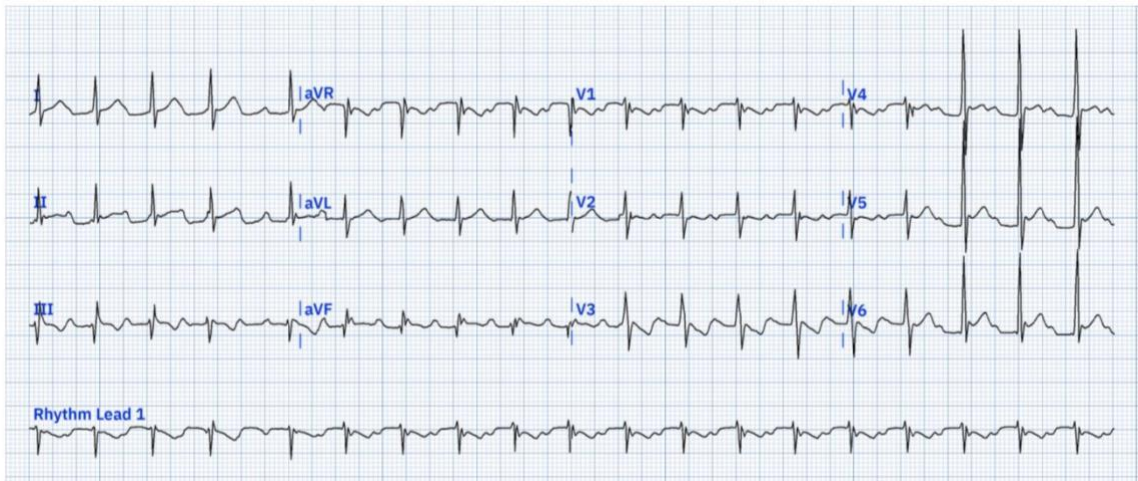
[www.urgentcarecollege.org](http://www.urgentcarecollege.org)



URGENT CARE  
COLLEGE OF  
PHYSICIANS

[www.uccop.org](http://www.uccop.org)

Here is his EKG:



His echo showed a mildly reduced ejection fraction of 46-50% but normal right ventricular size and no valvular disease. His heart rate persisted over 100 bpm during his admission and his orthostatic vital signs taken after the furosemide were positive. The lightheadedness on standing persisted.

**Question: Was this really sinus tachycardia?**

There was a lot of evidence pointing to that it could be. He was volume depleted from the hot day. He did drink caffeine which could have elevated his heart rate. But it wasn't sinus tachycardia despite the machine's interpretation. Something just didn't quite fit. The rhythm in this case is a 2:1 atrial flutter.

**What is the secret weapon to sort it out?**

The Bix rule is just that. Looking at V1 there is a visible P wave situated halfway between the R and R that points to atrial flutter. There is also an assumption that there is likely a P wave buried in the QRS as well.

The patient's reduced ejection fraction was most likely tachycardia mediated. The patient made a full recovery after a transesophageal echocardiogram with DC cardioversion. He was referred to Electrophysiology for consideration of ablation.

**Take home points:**

It is important to look at the EKG ourselves and not trust the machine's interpretation. The machine will rarely pick up 2:1 atrial flutter. The astute clinician will forgo the machine reading and interpret the EKG themselves. The other key in his case is that he had a mixed picture because he was also volume depleted from the heat.

Reference:

Nilolic G, Cardiac Conundrum: The Bix Rule. *Heart and Lung*, 37:4, July/August 2008, 321-2/



## CME Eligible: Best Practice from the Urgent Care College of Physicians



URGENT CARE  
COLLEGE OF  
PHYSICIANS



COLLEGE OF  
URGENT CARE  
MEDICINE

Clinical Practice Guideline: Nosebleed (Epistaxis)  
A review of this guideline from an Urgent Care Perspective

Date Reviewed	08.03.2024
Subject	Epistaxis Management in Urgent Care
Patient Population	<p>Individuals aged <math>\geq 3</math> years with a nosebleed might present as a patient with bleeding from the nostril, nasal cavity or nasopharynx that is sufficient to warrant medical advice or care. This includes bleeding that is severe, persistent, and/or recurrent, as well as bleeding that impacts a patient's quality of life. The distribution is bimodal distribution with more nosebleeds in children and the elderly.</p> <p>Populations excluded from this guideline review include -</p> <ul style="list-style-type: none"> <li>• Children <math>&lt;3</math> years as they rarely get nosebleeds</li> <li>• Nasal or nasopharyngeal tumors</li> <li>• Vascular malformations</li> <li>• Diagnosed bleeding disorder</li> <li>• Recent facial trauma</li> <li>• Recent sinus or nasal surgery in the past 30 days</li> </ul> <p>The above groups of conditions require treatment of the causative factors.</p>
Rationale	<p>As in other acute care settings such as the Emergency Departments, epistaxis is a complaint that presents to Urgent Care centers as well. Clinicians and teams working in Urgent Care should be able to assess such patients, identify emergent situations that need further evaluation in the emergency room, reasonably identify the resource of the nosebleed and provide either initial or definitive management along with recommendations on appropriate follow-up after discharge from the Urgent Care center.</p>
Introduction	<p>Epistaxis is a common problem that occurs in at least 60% of the patients in the U.S. and of these about 6% seek medical attention. The majority of nosebleeds are self-limited.</p> <p>Bleeding is most common in the anterior septum at the Kiesselbach's plexus (Figure 1) and accounts for 90% of the nosebleeds.</p> <p>Posterior nosebleeds account for 5% to 10% and are more common in older patients and are more difficult to control.</p>



COLLEGE OF  
URGENT CARE  
MEDICINE

[www.urgentcarecollege.org](http://www.urgentcarecollege.org)



URGENT CARE  
COLLEGE OF  
PHYSICIANS

[www.uccop.org](http://www.uccop.org)

	<p>Most nosebleeds are spontaneous. Risk factors for nosebleeds include:</p> <ul style="list-style-type: none"> <li>• Hypertension</li> <li>• Clotting defects: anticoagulation, thrombocytopenia, hereditary hemorrhagic telangiectasia</li> <li>• Systemic illnesses: hematologic, hepatic, renal, genetic, cardiovascular diseases</li> <li>• Any cause of nasal mucosal inflammation or hyperemia, such as allergic rhinitis, viral rhinitis, bacterial rhinosinusitis, dust, or chemicals</li> </ul>
Evidence based guideline	<p>I. Assessing Stability</p> <p>At the time of initial contact, the clinician should distinguish the nosebleed patient who requires prompt management from the patient who does not. ABCs should be evaluated like any other urgent/emergent case. Specific actions include:</p> <ul style="list-style-type: none"> <li>• ABCs: Assess for airway compromise from bleeding into the oropharynx and airway, hemodynamic instability due to blood loss, tachycardia, syncope, orthostatic hypotension.</li> <li>• If any of the above concerns are present, initial stabilization should be the next step while an emergent referral to the ED is being arranged.</li> <li>• Severe bleeding should be considered based on the following: <ul style="list-style-type: none"> <li>• Bleeding duration &gt;30 minutes over a 24-hour period</li> <li>• &gt;3 recent episodes of nosebleed</li> <li>• Prior transfusions or hospitalization from nosebleed</li> </ul> </li> </ul> <p>II. Controlling the Bleed</p> <p>Anterior Nosebleed:</p> <p><b>1. Nasal Compression:</b></p> <ul style="list-style-type: none"> <li>• Apply firm sustained compression to the lower third of the nose, with or without the assistance of the patient or caregiver, for five minutes or longer.</li> <li>• Vasoconstrictors such as Oxymetazoline can be used prior to applying pressure. Options include sprays or intranasal insertion of cotton impregnated with medication. Other options include epinephrine 1:1000, but clinicians should be aware of the adverse effects of systemic epinephrine absorption (elevated blood pressure and tachycardia).</li> <li>• If a prominent vessel is suspected as the source of bleeding, direct nasal cautery can be applied. Silver nitrate sticks are the most commonly used method. Blind cauterization is not recommended due to the potential excessive destruction of the nasal mucosa.</li> </ul> <p>If bleeding is not controlled with the above conservative measures, next steps of Nasal Packing should be performed.</p> <p><b>2. Anterior Nasal Packing:</b></p> <ul style="list-style-type: none"> <li>• Recommended in case of failure of conservative treatment outlined above.</li> </ul> <p>Non-resorbable Packing:</p>

	<ul style="list-style-type: none"> <li>• In Urgent Care settings usually includes Rhino Rocket, Rapid Rhino, Merocel or Ribbon Gauze.</li> </ul> <p>Resorbable Packing:</p> <ul style="list-style-type: none"> <li>• Urgent Care settings usually include Surgicel, Surgifoam.</li> <li>• Usually recommended in bleeding disorders, anticoagulation, vascular abnormalities such as HHT when insertion of non-resorbable packing can result in mucosal trauma and additional bleeding.</li> </ul> <p>Equipment needed:</p> <ul style="list-style-type: none"> <li>• Headlight for visibility</li> <li>• Nasal specula for direct visualization of the nostril</li> <li>• Forceps to help place the packing material</li> <li>• Antibiotic ointment to provide lubrication</li> </ul> <p>Procedure:</p> <ul style="list-style-type: none"> <li>• Ask patient to blow to clear any clots</li> <li>• Pack the nare that is bleeding profusely</li> <li>• Progress packing posteriorly, not superiorly</li> </ul> <p>Duration of Packing: Packing duration typically ranges from 48h hours to 72 hours.</p> <p>Oral Antibiotics:</p> <ul style="list-style-type: none"> <li>• Use to prevent infection or toxic shock syndrome is controversial. Individual risks and benefits should be assessed.</li> </ul> <p>Posterior Nosebleed:</p> <ul style="list-style-type: none"> <li>• Usually, severe bleeding needs control in the OR, or endovascularly with interventional radiology. Needs transfer to the ED from Urgent Care.</li> </ul> <p>III. Patient Education</p> <ul style="list-style-type: none"> <li>• Appropriate instructions regarding post-procedure care, follow-up for packing removal, complications/signs and symptoms that require immediate reassessment should be provided.</li> <li>• Educate patients regarding preventive measures. <ul style="list-style-type: none"> <li>• Avoid digital trauma or nose picking.</li> <li>• Use moisturizers and lubricants such as nasal saline, gels, ointments, air humidifiers.</li> </ul> </li> </ul>
Summary	<p>Just as in the Emergency Department, nosebleed patients present to Urgent Care centers as well. Urgent Care clinicians (UCCs) should educate themselves regarding the etiology, presentations, diagnosis and management of nosebleeds. Continued education is needed for UCCs to maintain fresh knowledge on the procedures of nasal packing. UCCs should also be aware of the complication of hemodynamic instability, be able to identify these patients and triage them appropriately.</p>
References	<p>Otolaryngology–Head and Neck Surgery. 2020, Vol. 162(1S) S1–S38. American Academy of Otolaryngology–Head and Neck. Surgery Foundation 2020 DOI: 10.1177/0194599819890327. <a href="http://otojournal.org">http://otojournal.org</a> <a href="https://aao-hnsfjournals.onlinelibrary.wiley.com/doi/epdf/10.1177/0194599819890327">https://aao-hnsfjournals.onlinelibrary.wiley.com/doi/epdf/10.1177/0194599819890327</a></p>

	Womack JP, Kropa J, Stabile MJ. Epistaxis: Outpatient management. American Family Physician. August 15, 2018. Accessed September 7, 2024. <a href="https://www.aafp.org/pubs/afp/issues/2018/0815/p240.html">https://www.aafp.org/pubs/afp/issues/2018/0815/p240.html</a> .
Reviewers	Jasmeet Singh Bhogal, MD, MBA, FCUCM
Attachments (flow charts, graphics, tables, etc.)	N/A



## CME Eligible: Q&A: What is the Role of D-Dimer in Ruling Out DVT?

**Cesar Mora Jaramillo, MD, FAAFP, FCUCM**

What is the Role of D-Dimer in ruling out Deep Venous Thrombosis (DVT)?

Urgent Care clinicians often encounter clinical scenarios when a patient is suspected of having a DVT. It is crucial for clinicians to be familiar with the clinical signs and symptoms of DVT and the diagnostic testing options. The consequences of missing the diagnosis of DVT can be fatal.

D-dimer is one of the commonly used methods to exclude DVT. This test should not be used as a stand-alone test, but rather should be used in conjunction with risk stratification (Wells score) and/or ultrasonography.<sup>1</sup>

When DVT is suspected, the next step is to determine the clinical pretest probability of the patient. If the clinical pretest probability is low, a negative D-dimer test can exclude a DVT without the need for further testing. But if the clinical pretest probability is moderate or high, ultrasound imaging is the recommended test without measurement of D-dimer.<sup>2,3</sup>

D-dimer has a high sensitivity and poor specificity when ruling out acute DVT. Hence, a positive result does not diagnose a DVT because it can be found in patients with certain conditions and the risk of false positives increases with age. Thus, after a positive result, an ultrasound should be ordered to evaluate for DVT. Clinicians should be aware of cutoff values and what type of assay (high sensitivity or moderate sensitivity) is being used in their Urgent Care.

ACEP and other medical organizations support this strategy. However, ACEP also recommends that in patients with a low clinical probability for lower extremity DVT, the following test results could be used to exclude a DVT:<sup>4</sup>

- 1) a negative quantitative D-dimer assay result (turbidimetric or ELISA) for exclusion of proximal and distal lower extremity DVT
- 2) a negative whole blood D-dimer assay result in conjunction with Wells scoring system and
- 3) a negative whole blood D-dimer assay result for the exclusion of proximal lower extremity DVT

For patients with moderate or high clinical pretest probability for DVT, the use of D-dimer as a diagnostic method for ruling in DVT is not recommended.

### References:

1. Frost SD, Brotman DJ, Michota FA. Rational use of D-dimer measurement to exclude acute venous thromboembolic disease. *Mayo Clin Proc.* 2003 Nov;78(11):1385-91. doi: 10.4065/78.11.1385. PMID: 14601697.
2. Kearon C, de Wit K, Parpia S, Schulman S, Spencer F A, Sharma S et al. Diagnosis of deep vein thrombosis with D-dimer adjusted to clinical probability: prospective diagnostic management study *BMJ* 2022; 376 :e067378 doi:10.1136/bmj-2021-067378
3. Wells PS, Anderson DR, Bormanis J, et al. Value of assessment of pretest probability of deep-vein thrombosis in clinical management. *Lancet.* 1997;350(9094):1795-1798. (Prospective study; 593 patients) DOI: [10.1016/S0140-6736\(97\)08140-3](https://doi.org/10.1016/S0140-6736(97)08140-3)



COLLEGE OF  
URGENT CARE  
MEDICINE

[www.urgentcarecollege.org](http://www.urgentcarecollege.org)



URGENT CARE  
COLLEGE OF  
PHYSICIANS

[www.uccop.org](http://www.uccop.org)

4. American College of Emergency Physicians ACEP Clinical Policies Committee, ACEP Clinical Policies Subcommittee on Suspected Lower-Extremity Deep Venous Thrombosis. Clinical policy: critical issues in the evaluation and management of adult patients presenting with suspected lower-extremity deep venous thrombosis. *Ann Emerg Med.* 2003;42(1):124-135. (Clinical policy) DOI: [10.1067/mem.2003.181](https://doi.org/10.1067/mem.2003.181)



COLLEGE OF  
URGENT CARE  
MEDICINE

[www.urgentcarecollege.org](http://www.urgentcarecollege.org)



URGENT CARE  
COLLEGE OF  
PHYSICIANS

[www.uccop.org](http://www.uccop.org)

# Insights: Organizations Driving Innovation in Urgent Care Education



## CME Eligible: Legal Lessons: Testicular Torsion—A Case with a Twist

**Kelly Heidepriem, MD**  
Hippo Education

Gastroenteritis is a common Urgent Care diagnosis, but clinicians tend to default to it because they lack a better explanation for a patient's GI symptoms. Don't fall into the same trap as a fellow Urgent Care clinician from N.Y., who missed a case of testicular torsion masquerading as a benign GI complaint.

### Patient Presentation and Legal Case

The case in question involves a 12-year-old boy who visited an Urgent Care center with his mother, complaining of epigastric abdominal pain. The patient was diagnosed with gastroenteritis and pharyngitis. Notably, there was no genitourinary exam documented, nor was there mention of whether the child stated they had testicular pain. However, within 24 hours, he was diagnosed with testicular torsion in the emergency room.

The crux of the legal complaint was the allegation that the Urgent Care clinician failed to examine the genitourinary (GU) area adequately and subsequently failed to order an ultrasound and make the diagnosis. The lawsuit highlighted the physical injuries suffered by the patient, including testicular torsion, removal of the affected testicle and associated psychological distress. The settlement reached in the case totaled \$299,000.

### Medical Overview of Testicular Torsion

Diagnosing testicular torsion presents several challenges, particularly in cases with atypical symptoms or presentations. While testicular pain is a hallmark symptom, it may not always be present, leading to potential misdiagnosis or delayed treatment. Moreover, relying solely on physical examination findings can be inconclusive, as testicles can appear normal early in the disease process, and the presence/absence of cremasteric reflex is unreliable.

It occurs in approximately 4.5 per 100,000 males under the age of 25. Testicular salvage rates decline significantly beyond the first 12 hours, with only 54.0% survival from 13 to 24 hours and 18.1% survival beyond 24 hours. This emphasizes the critical importance of prompt recognition and intervention to maximize patient outcomes.

Tools like the Twist Score have been developed to aid diagnosis, although they may not definitively exclude torsion. Additionally, the high variability in clinical presentation underscores the importance of maintaining a high index of suspicion, especially in patients with abdominal pain or nausea.

### **Malpractice Data**

In a study by Glerum et al. looking at closed pediatric malpractice claims, testicular torsion represented 4% of all claims, 5.5% of paid claims, and, when filed, was 41.4% likely to result in a payment to a plaintiff. The average indemnity was \$253,756, with average defense fees of \$36,896. Claims related to male genitalia disorders, including testicular torsion, rank among the most common in pediatric and adolescent populations.

### **Conclusion**

In our discussion, Matt Delaney and I highlight the high malpractice risk and impact on patient livelihood associated with testicular torsion. We stress that nearly every testicular pain case that presents to Urgent Care should undergo an ultrasound, or at the very least, your notes should document a thorough conversation with the patient about your recommendations to do so. We also highlight how easy this can be to miss in a patient who you think is old enough to tell you they have testicular pain, how we need to be asking every pediatric patient with abdominal pain if they're having testicular pain and checking the younger pediatric patients if you're not sure if they're reliable.





# AIRSUPRA<sup>®</sup>

(albuterol 90 mcg/budesonide 80 mcg)  
Inhalation Aerosol



DISCOVER AIRSUPRA AT  
[airsupraHCP.com](https://airsupraHCP.com)



AIRSUPRA is a registered trademark of the AstraZeneca group of companies.  
©2024 AstraZeneca. All rights reserved. US-89813 Last Updated 5/24



COLLEGE OF  
URGENT CARE  
MEDICINE

[www.urgentcarecollege.org](http://www.urgentcarecollege.org)



URGENT CARE  
COLLEGE OF  
PHYSICIANS

[www.uccop.org](http://www.uccop.org)



## CME Eligible: Managing Shoulder Injuries in Urgent Care: Fracture, Dislocation, and Overuse

Excerpted from: Velagapudi M., Wilson, M., Ring, H. Managing shoulder injuries in the Urgent Care: fracture, dislocation, and overuse. *Evidence-Based Urgent Care*. 2024 July;3(7):1-35. Reprinted with permission of EB Medicine.

### Shoulder Fractures

#### Clavicle Fractures

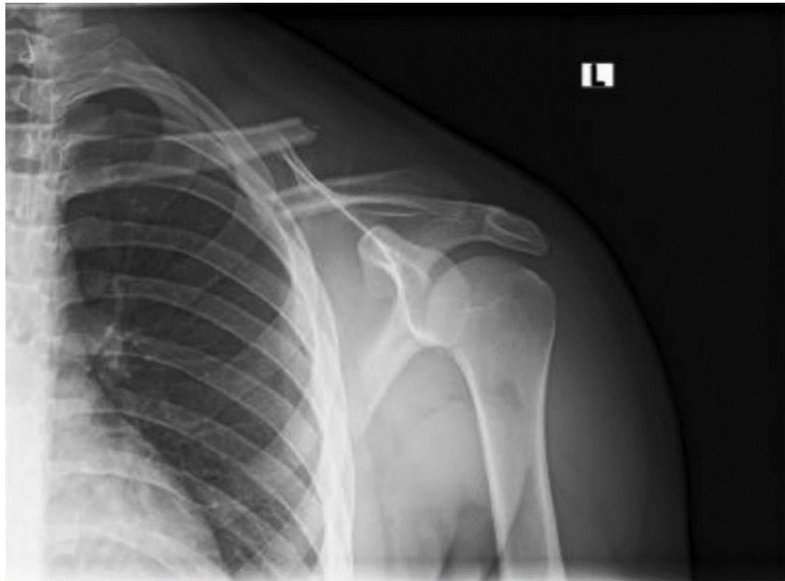Clavicle fractures comprise 44%-60% of all shoulder fractures. The clavicle is the most commonly fractured bone in children.<sup>14,50</sup> These fractures can be grossly divided and classified into three distinct anatomical sites. Type I fractures (the most common, up to 80%) occur within the middle third of the clavicle. Type II fractures represent involvement of the lateral third, and Type III fractures (the least common, up to 5%) indicate involvement of the medial third of the clavicle.<sup>14,51</sup>

Typically, clavicle fractures can be managed with outpatient orthopedic follow-up.<sup>19</sup> Conservatively treated fractures unite in nearly 97% of cases. Very low-quality evidence from two trials comparing figure-of-eight bandaging with an arm sling found no statistically significant difference in outcome or time to union between the two groups.<sup>52,53</sup> A third, retrospective investigation of 71 patients noted no difference in outcomes between an arm sling, collar and cuff, or figure-of-eight bandaging.<sup>13</sup>

Operative intervention is typically reserved for open injuries; injuries with significant skin tenting, which may cause necrosis; fracture in high-functioning athletes; intra-articular fractures involving the sternoclavicular joint or acromioclavicular joint; and fractures in which the initial shortening is >20 mm (a characteristic associated with high nonunion rates if treated conservatively).<sup>51</sup> **(See Figure 8)** Injuries presenting with an open fracture, signs of neurovascular compromise, or an association with other significant injuries requiring further trauma evaluation should be assessed in an Emergency Department (ED). The fracture should be immobilized prior to the patient leaving the Urgent Care center. More recently, there has been a trend toward increased rate of operative intervention, particularly in midshaft and displaced fractures.<sup>54</sup> Improved functional outcomes have been demonstrated in these patients, as well as lower rates of pain, nonunion, instability and cosmetic satisfaction.<sup>51</sup> Surgical treatment may also provide a faster recovery, allowing earlier return to work or play.<sup>54</sup>



**Figure 8. Type 1 (Middle Third) Clavicle Fracture on X-Ray**



Note shortening of >20 mm, which would require orthopedic consultation in the Emergency Department for possible operative intervention. Image courtesy of James Kovacs, DO.

Complications of clavicle fractures include malunion, shoulder deformity, nonunion and infections.<sup>14</sup> Pseudarthrosis has been reported in 5% of patients, with incidence significantly increased in cases where displacement is more severe.<sup>53</sup> Traumatic osteoarthritis of the acromioclavicular joint is reported in 6% of patients following lateral clavicle fracture.<sup>55</sup>

### Scapula Fractures

Isolated scapular fractures are uncommon, as a great deal of force is required to fracture the scapula. This typically occurs in the setting of multisystem trauma following a motor vehicle crash. In an observational study of 113 patients, Ada et al reported 61% of scapular fractures were caused by motor vehicle-pedestrian collisions.<sup>56</sup>

Fractures of the scapula are classified according to their anatomic location. Type I fractures involve the acromion process, scapular spine or coracoid process. Type II fractures involve the scapular neck. Type III fractures are intra-articular fractures of the glenoid fossa. Type IV fractures involve the body of the scapula.<sup>56</sup> All fractures should be immobilized, and the patient referred to an ED so CT can be performed to quantify the deformity and evaluate for other significant injuries.<sup>9</sup>

Up to 90% of scapula fractures are nondisplaced. Treatment for nondisplaced isolated scapula fractures requires sling and swathe, with orthopedic follow-up. Nondisplaced or minimally displaced scapula fractures tend to heal well, with good return of function and range of motion without surgical fixation.<sup>19,57</sup> Traditional treatment of scapular fractures with even moderate displacement has been with benign neglect, with the hope of minimizing functional compromise. However, as understanding of the scapula's role in the shoulder complex has continued to evolve and as surgical techniques for internal fixation have advanced, surgeons are increasingly electing to operatively fixate scapular fractures.<sup>9</sup>

Glenohumeral joint disruption, marked displacement or angulation or associated neurovascular injury are indications for open reduction.<sup>19</sup> However, these indications need to be placed in the context of other ipsilateral injuries as well as patient comorbidities and activity level.<sup>9</sup>

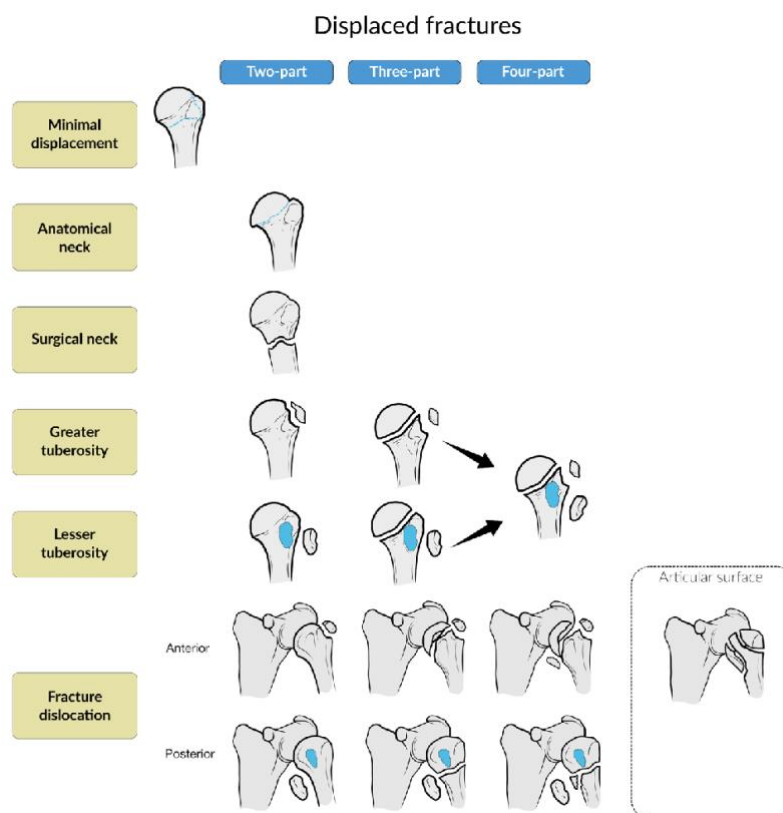
Progressive deformity of the scapular fracture during the early postinjury phase is a concern, and serial upright radiographs should be obtained on a weekly basis for up to three weeks if nonoperative management is to be undertaken.<sup>9</sup> Vigilance is also required for signs of a delayed pneumothorax following a scapular fracture, and patients should be counseled to obtain evaluation for worsening pleuritic chest pain or shortness of breath. Delayed complications also include adhesive capsulitis and rotator cuff dysfunction.<sup>58</sup> Appropriate orthopedic follow-up and early mobilization can help to mitigate these later developments.

### Proximal Humerus Fractures

Proximal humerus fractures—fractures that are at and proximal to the surgical neck—are most common in the elderly, with more than 75% occurring in patients aged >65 years.<sup>19</sup> When elderly patients fall on an outstretched arm, the weakened tensile strength of their bone and surrounding ligaments, compared to that of younger patients, results in more frequent proximal humerus fractures.

The Neer classification is the most frequently used classification system for proximal humerus fractures, dividing the proximal humerus into four parts: (1) the humeral head, (2) the humeral shaft, (3) the greater tuberosity, and (4) the lesser tuberosity. The Neer system is based on the relationship of these fracture segments, leading to four major categories of fracture: (1) minimal displacement, (2) 2-part displacement, (3) 3-part displacement, or (4) 4-part displacement.<sup>45</sup> **(See Figure 9)**

**Figure 9. Neer Classification of Proximal Humerus Fractures**



[www.ebmedicine.net](http://www.ebmedicine.net)

Nondisplaced or minimally displaced and stable proximal humerus fractures are treated nonoperatively with sling and analgesia. The 2-part, 3-part, and 4-part fractures require rapid orthopedic follow-up regarding potential early surgical management.<sup>19</sup> All fracture-dislocations or fractures with signs of neurovascular compromise should be immobilized then referred to the ED for emergent evaluation by an orthopedic surgeon. For patients who do not require emergency evaluation, passive joint mobilization of proximal humeral fracture offers a better chance for a more rapid recovery of overall shoulder functional status than does classic 3-week immobilization followed by physiotherapy.<sup>50</sup> Physical therapy should be initiated within three days. All proximal humerus fractures require orthopedic follow-up to monitor progress and healing.

In a literature review spanning 13 years, quality of life was evaluated in elderly patients following nonsurgical and surgical interventions such as open-reduction and internal fixation or reverse total shoulder arthroplasty for proximal humeral fractures. Five dimensions, including mobility, self-care, performing usual activities, pain or discomfort and anxiety or depression, were analyzed. The most significant deterrent to quality of life was pain. Overall, there was no clinical difference in quality of life between patients who had surgical versus nonoperative interventions.<sup>60</sup>

One of the most devastating complications of proximal humerus fracture is avascular necrosis of the humeral head. The highest rate of avascular necrosis (up to 90%) occurs with 4-part fractures, and it is also a concern with anatomical neck fractures.<sup>61</sup> Early mobilization and physical therapy can prevent the development of rotator cuff syndromes and adhesive capsulitis.

A summary of management and disposition strategies for fractures is provided in **Table 4**.

**Table 4. Management and Disposition of Shoulder Fractures**

Injury	Management	Important Considerations
Clavicle fracture	Sling and outpatient referral	Significant skin tenting, initial shortening >20 mm, or intra-articular involvement (lateral or medial) require immobilization then refer to ED for urgent orthopedic consultation and operative intervention
Scapula fracture	Sling/swathe, ED referral	Rarely found in isolation; will require immobilization then ED evaluation for additional occult thoracic injury
Proximal humerus fracture	Sling, outpatient referral vs ED evaluation	Nondisplaced and stable fractures may be treated nonoperatively; multipart fractures typically require surgery and should be immobilized with rapid orthopedic follow-up; fractures with signs of neurovascular compromise should be referred to the ED

Abbreviation: ED, emergency department.

[www.ebmedicine.net](http://www.ebmedicine.net)

## Shoulder Joint Dislocations

### Sternoclavicular Joint Dislocation

Overall, sternoclavicular joint dislocations are uncommon, accounting for <1% of shoulder girdle injuries.<sup>4</sup> Most of these injuries are seen in high-impact trauma, are associated with more serious or life-threatening injuries and will likely be directed to the ED. Arthritis may also contribute to this condition. Anterior dislocation is most common, with posterior dislocations representing only 3% to 5% of these dislocations.<sup>3,62</sup> An X-ray of anterior sternoclavicular joint dislocation can be seen in **Figure 10**.

Figure 10. Right Anterior Sternoclavicular Joint Dislocation on X-Ray

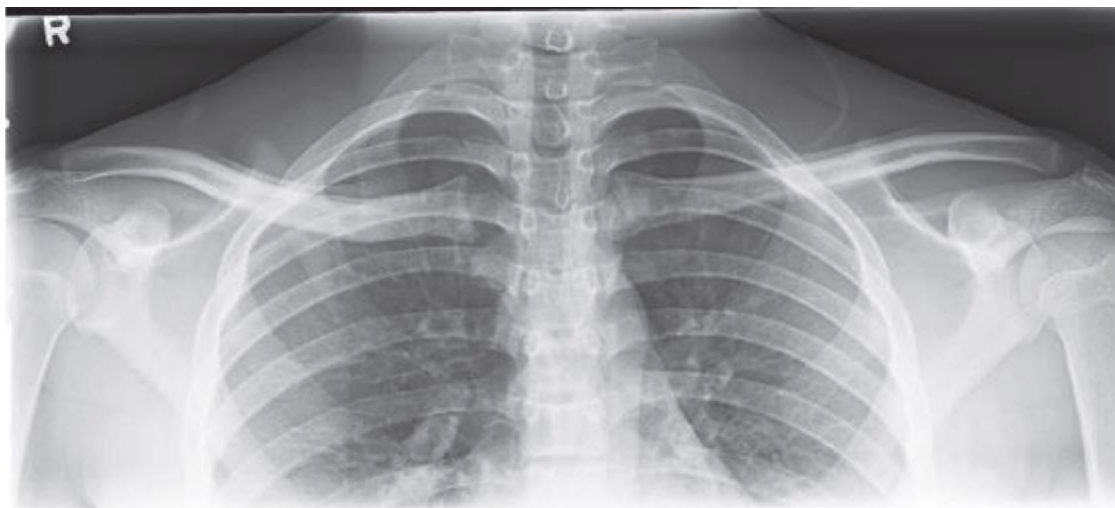


Image courtesy of James Kovacs, DO

[www.ebmedicine.net](http://www.ebmedicine.net)

#### Anterior Sternoclavicular Joint Dislocation

Most anterior dislocations are managed simply with immobilization, with or without closed reduction, but should be evaluated in an ED for further orthopedic evaluation. Redislocation has been found to occur in 21% to 96% of cases, which raises the question of whether simple closed reduction without ligament reconstruction is sufficient.<sup>63</sup> Complete dislocation injuries are more likely to be associated with persistent pain, and they should generally undergo closed reduction.<sup>64</sup>

#### Posterior Sternoclavicular Joint Dislocation

Posterior sternoclavicular joint dislocation is a true emergency, requiring evaluation in an ED for emergent orthopedic and cardiothoracic surgery consultation since life-threatening injuries can result. The medial clavicle sits anterior to important structures that can be compromised following reduction including the trachea, innominate artery and vein, and thoracic duct.<sup>65</sup> Posterior dislocations tend to be stable once reduced, and excellent postoperative outcomes have been demonstrated with open reductions.<sup>15</sup>

#### Acromioclavicular Joint Injuries (Shoulder Separation)

Injuries to the acromioclavicular joint should be suspected whenever patients complain of pain centering on or around the acromion, and particularly when the mechanism suggests a direct blow to the shoulder in the setting of an adducted upper extremity. This could be from falling or impacting a stationary object or person, as in football or soccer. The radiographic classification of acromioclavicular joint injuries includes six types, as described by Rockwood. Rockwood type III injuries (**see Figure 12**) are, by far, the most common presentation seen in EDs.<sup>66</sup>

**Figure 12. Acromioclavicular Joint Dislocation, Rockwood Type III, on X-Ray**

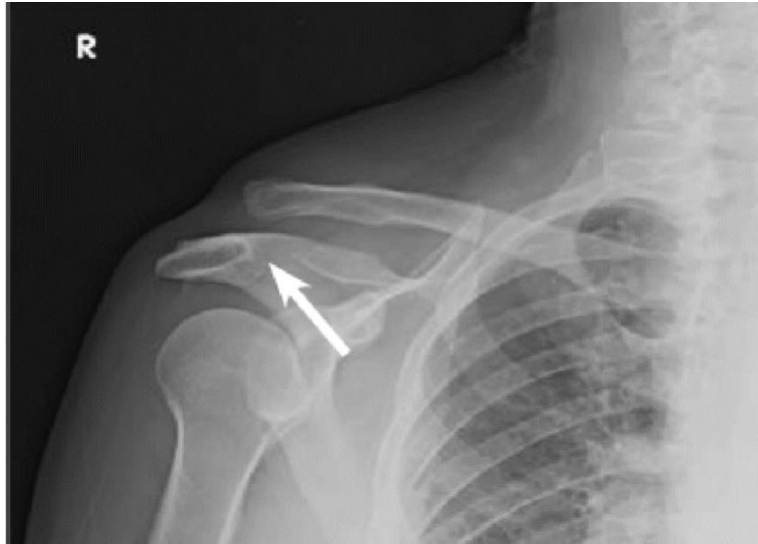

Image courtesy of James Kovacs, DO

[www.ebmedicine.net](http://www.ebmedicine.net)

Despite the prevalence of acromioclavicular joint dislocation, there is a lack of consensus regarding its diagnosis and treatment.<sup>67</sup> There is a consensus in the literature that type I and II injuries should be managed conservatively, without surgery. Sling immobilization and other symptomatic treatment of pain are usually all that are necessary for these dislocations.<sup>19,68</sup> Low-grade dislocations are appropriate for outpatient orthopedic follow-up. Most patients have satisfactory results and can return to sporting activities.<sup>69</sup>

The treatment of type III injuries is controversial. While improved radiographic findings have been demonstrated with surgical compared to conservative treatment, it is unclear whether clinically relevant outcomes are improved.<sup>70</sup> At this time, it is recommended to pursue expedient orthopedic surgical follow-up for type III and higher injuries. Types IV, V, and VI acromioclavicular joint dislocations all require early surgical treatment.<sup>68,69</sup>

Radiographic stress views can help differentiate type I from type II injuries, but they do not typically affect the treatment so are not necessary in Urgent Care. Acromioclavicular joint injuries generally heal well, with limited complications. In rare cases with severe trauma to the joint, however, brachial plexus injuries can occur.<sup>16</sup> Patients should be informed of signs of delayed neuropraxia and cautioned to present to the ED in the event of new motor or sensory deficit.

### Glenohumeral Joint Dislocations

#### *Anterior Glenohumeral Joint Dislocation*

Anterior glenohumeral joint dislocation is the most common large joint dislocation in the body. Upwards of 90% of glenohumeral dislocations are anterior. Anterior dislocations are described in relation to the anatomic location of the dislocated humeral head: subclavicular, subglenoid, intrathoracic and the most common: subcoracoid. Radiographic evaluation usually shows a dislocation in the AP view, with the humeral head medialized and inferiorly displaced.<sup>8,41</sup> **(See Figure 13.)**

**Figure 13. Anterior Subcoracoid Glenohumeral Dislocation on X-Ray**

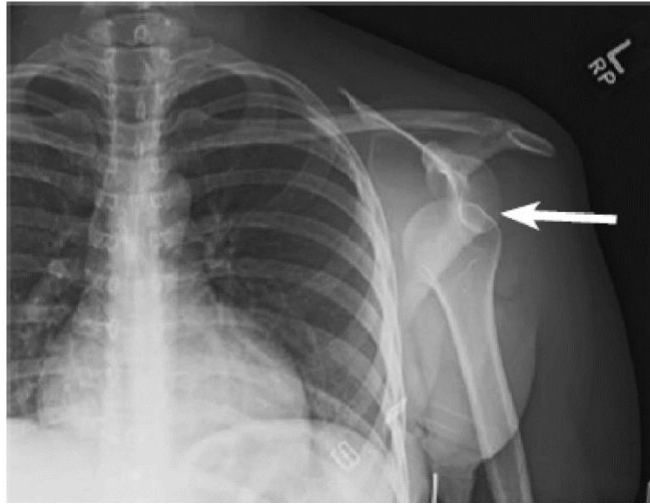


Image courtesy of James Kovacs, DO [www.ebmedicine.net](http://www.ebmedicine.net)

The most common bony injuries associated with anterior dislocation are Bankart lesions and Hill-Sachs lesions. During an anterior dislocation, the humeral head is forced anteriorly out of the glenoid socket, potentially causing damage to the anterior capsule and labrum of the glenoid rim (Bankart lesion). Bankart lesions can be bony injuries (when the glenoid rim is fractured); however, they can also involve only cartilage. This is typically diagnosed on MRI and may be a source of chronic pain not visible on plain radiographs. As the final, posterior part of the head is forced out of the joint, it can collide with the anterior aspect of the glenoid rim, leading to a compression fracture of the posterior aspect of the humeral head, known as a Hill-Sachs lesion.<sup>66,71</sup> **(See Figure 14.)** Hill-Sachs lesions have been reported in about 15% of anterior dislocations and are readily visualized on plain radiographs.<sup>66,72,73</sup> Defects larger than 25% of the humeral articular surface often require surgical intervention.<sup>66</sup>

Figure 14. Anterior Subglenoid Glenohumeral Dislocation with Hill-Sachs Deformity of the Humeral Head on X-Ray

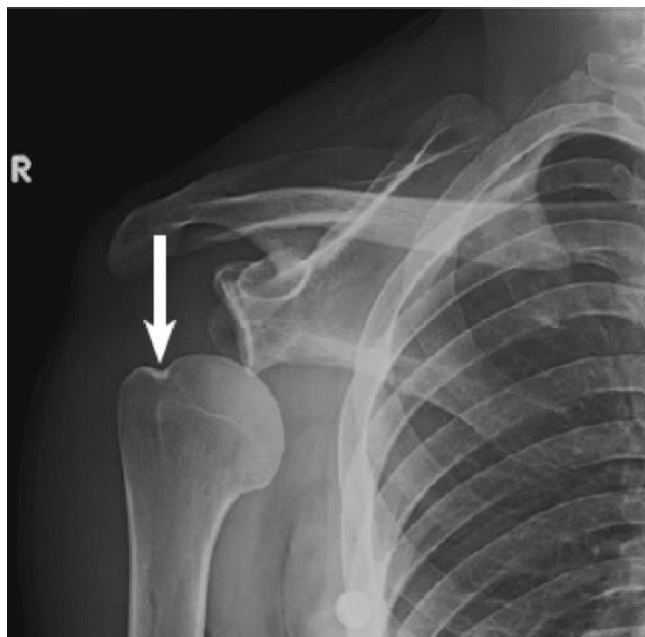


Image courtesy of James Kovacs, DO [www.ebmedicine.net](http://www.ebmedicine.net)

Concomitant fracture of the humeral shaft represents a population at high risk for neurovascular damage. A prospective study with extensive electrophysiological assessment found that 45% of patients with fracture-dislocations also sustained nerve damage.<sup>74</sup>

#### *Posterior Glenohumeral Joint Dislocations*

Posterior dislocations account for 2% to 5% of all glenohumeral joint dislocations.<sup>23</sup> Diagnosis can be difficult; thus, missed posterior shoulder dislocations are frequent, with missed or delayed diagnoses in up to 79% of patients.<sup>23,75</sup> Such difficulty has led to posterior dislocations being labeled a “diagnostic trap” by multiple authors.<sup>47</sup> An example of the posterior shoulder dislocation seen from the scapular “Y” view is demonstrated in **Figure 15**.

**Figure 15. Scapular “Y” View of Posterior Shoulder Dislocation on X-Ray**

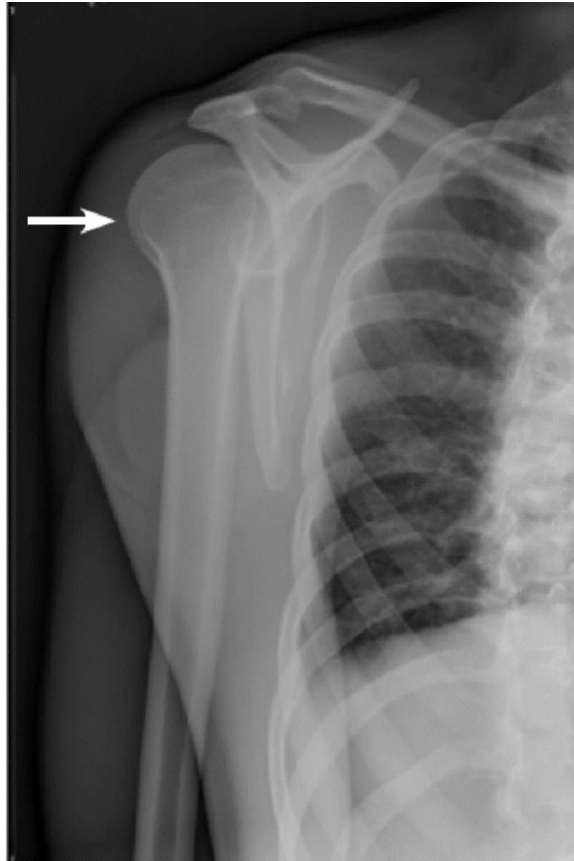

Image courtesy of James Kovacs, DO [www.ebmedicine.net](http://www.ebmedicine.net)

Posterior shoulder dislocations rarely occur in isolation and associated bony or soft-tissue injuries are nearly universal. They are also extremely difficult to reduce without sedation. Thus, evaluation in an ED is necessary. Impaction fractures of the humeral head (reverse Hill-Sachs lesions, seen in **Figure 16**), posterior labro-capsular lesions (reverse Bankart lesions), rotator cuff tears and humeral neck or tuberosity fractures almost always complete the scenario.<sup>17,76</sup> The axillary view X-ray and/or the inability to fully externally rotate the glenohumeral joint aid in the diagnosis of posterior glenohumeral dislocations.

**Figure 16. Axillary View of Posterior Glenohumeral Dislocation with Reverse Hill-Sachs Lesion on X-Ray**

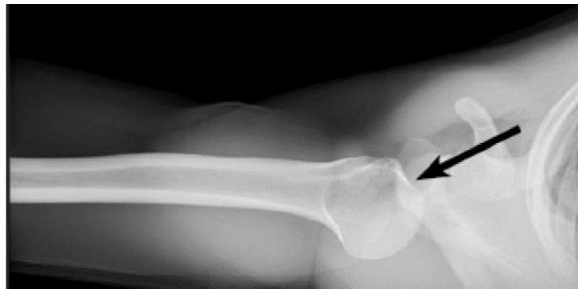

Image courtesy of James Kovacs, DO [www.ebmedicine.net](http://www.ebmedicine.net)

### *Inferior Glenohumeral Joint Dislocations (Luxatio Erecta)*

**Inferior dislocation of the shoulder constitutes only 0.5% of all shoulder dislocations.<sup>2</sup> Figure 17 shows an example of inferior dislocation.** Most inferior dislocations result from forceful hyperabduction of the shoulder (the indirect mechanism), such as a fall from a height suddenly arrested by grabbing with an extended arm. This violent force levers the proximal shaft of the humerus over the acromion and the humeral head comes to rest below the glenoid in abduction.<sup>2</sup> The less frequently described mechanism of action involves axillary loading on a fully abducted arm, driving the humeral head through the weak inferior glenohumeral ligaments and joint capsule. This etiology—the direct mechanism—is often associated with fractures of the greater tuberosity and tears of the rotator cuff.<sup>2</sup>

**Figure 17. Inferior Glenohumeral Dislocation on X-Ray**

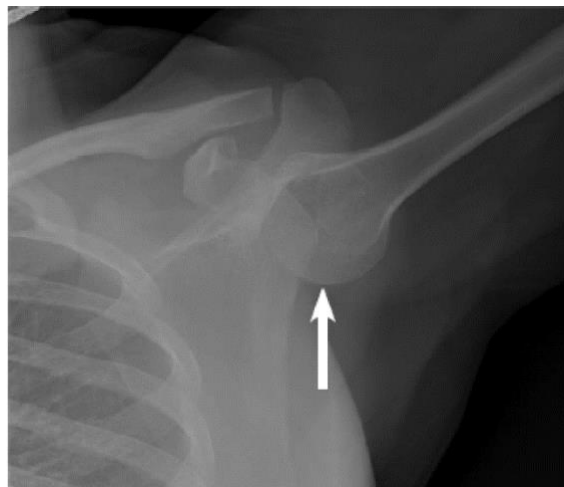

Image courtesy of James Kovacs, DO [www.ebmedicine.net](http://www.ebmedicine.net)

Approximately 80% of complications stemming from inferior shoulder dislocation are related to tears of the rotator cuff or a fracture of the greater tuberosity.<sup>77</sup> Neurological involvement is also common, with the axillary nerve being the most commonly affected. Nerve injuries have been reported in as many as 40% of cases, however, they generally resolve over weeks to months.<sup>1,2</sup> Disposition of inferior, anterior and posterior shoulder dislocations are summarized in **Table 5**.

**Table 5. Management and Disposition of Shoulder Joint Dislocations**

Injury	Management	Important Considerations
Sternoclavicular joint dislocation	<ul style="list-style-type: none"> <li>• Immobilization then evaluation in ED</li> </ul>	<ul style="list-style-type: none"> <li>• Maintain high suspicion for posterior sternoclavicular joint dislocation</li> <li>• CT angiography with surgical consultation is usually necessary</li> <li>• Neurovascular or airway compromise can result from reduction due to location of vital structures</li> </ul>
Acromioclavicular joint dislocation	<ul style="list-style-type: none"> <li>• Types I-II: sling, outpatient orthopedic referral</li> <li>• Types III-VI: sling, expedient orthopedic follow up</li> </ul>	<ul style="list-style-type: none"> <li>• Management of type III injuries is controversial; expedient orthopedic follow-up is indicated for all high-grade injuries</li> </ul>
Anterior glenohumeral dislocation	<ul style="list-style-type: none"> <li>• Consider reduction attempt using relaxation maneuvers</li> <li>• Sling post reduction</li> <li>• Evaluation and treatment in ED unless able to successfully reduce</li> </ul>	<ul style="list-style-type: none"> <li>• Immobilize in external rotation</li> <li>• Young and first-time dislocators particularly need expedient orthopedic follow-up, as surgical intervention can reduce recurrence</li> </ul>
All other glenohumeral dislocations	<ul style="list-style-type: none"> <li>• Send to ED for orthopedic consult to evaluate for reduction and CT scan</li> </ul>	<ul style="list-style-type: none"> <li>• Procedural sedation is often needed for reduction due to muscle spasms and high level of pain<sup>78</sup></li> <li>• Delayed presentation may require surgical repair</li> </ul>

Abbreviations: CT, computed tomography; ED, emergency department.

[www.ebmedicine.net](http://www.ebmedicine.net)

### Risk Management Pitfalls in Shoulder Injuries

**1. “We were busy, and I easily reduced the shoulder dislocation. I have no idea what the neuro exam was, but I doubt it was abnormal, despite what the lawyer says.”** The axillary nerve is the most commonly injured nervous structure, with up to 55% incidence with anterior glenohumeral dislocations. Decreased deltoid strength and loss of sensation over the lateral shoulder are common findings. Although rare, vascular injuries are more commonly seen in older patients.

**2. “The shoulder was easily reduced, so the humeral head compression fracture couldn’t have been caused by me.”** Hill-Sachs lesions have been reported in 15% of anterior dislocations and are readily visualized on plain radiographs. An MRI is typically needed to visualize a Bankart lesion. Pre- and post-reduction radiographs are recommended to confirm the presence or absence of associated fractures.

**3. “I never give an orthopedic referral to my patients with an uncomplicated shoulder reduction without evidence of any fracture. Who would have guessed she had a rotator cuff injury?”** All dislocations should be followed up after one or two weeks, for a clinical assessment in the outpatient setting. Orthopedic referral and shoulder MRI are recommended for all young, active first-time traumatic dislocators. Rotator cuff injuries and recurrent dislocations are higher in this subgroup.

**4. “The AP shoulder radiograph looked normal, and I thought the pain was from the trauma; I can’t believe there was a dislocation.”** Three views are required to assess the shoulder after trauma: AP projection, axillary view and scapular “Y” view. Posterior dislocations may be missed with an incomplete imaging series. The AP view may reveal the light bulb or rim sign in a posterior shoulder dislocation, while the axillary view reveals posterior positioning of the humeral head in relation to the glenoid rim.

**5. “The patient had a midshaft clavicle fracture; I thought immobilization and follow-up with his primary physician was all that was needed.”** Operative intervention is typically reserved for open injuries, injuries with significant skin tenting, intra-articular fractures, or fractures in which the initial shortening is >20 mm. Recent evidence shows a trend towards more operative intervention for midshaft clavicle fractures.

**6. “This patient was ‘speared’ in the chest while playing football. Even though he had significant pain at the sternoclavicular joint, the X-rays looked normal, so I discharged him.”** Plain films should not be used alone to exclude a posterior sternoclavicular joint dislocation, and CT is the definitive study when this diagnosis is suspected. The proximity of the great vessels, brachial plexus and other mediastinal structures compounds the potential severity of the injury.

**7. “The elderly lady complained of shoulder pain, but the shoulder films looked normal, so I gave her acetaminophen and sent her home. I can’t believe she had a myocardial infarction.”** The astute provider should always consider non-orthopedic causes of shoulder pain, such as cardiac, pulmonary or intra-abdominal pathology.

**8. “I always place my patients with a shoulder contusion in a sling for two weeks until primary care follow-up; it’s unfortunate he developed a frozen shoulder.”** Minimizing the length of immobilization, when possible, should be an outpatient treatment goal to avoid adhesive capsulitis. Emphasis on initiating stretching via “fingers walking up the wall” and pendulum exercises should be started as early as possible.

**9. “I relocate all anterior shoulder dislocations using Kocher technique and never had a problem until this one.”** While once a traditionally taught first-line method for emergency glenohumeral reduction, the Kocher method has fallen out of favor due to reports of iatrogenic subscapularis injury, spiral fractures of the humeral neck, and even axillary vein rupture and death. When appropriate, other techniques such as the Cunningham or Davos relaxation maneuvers should be strongly considered. The Kocher method should be avoided.

## References

1. Groh GI, Wirth MA, Rockwood CA. Results of treatment of luxatio erecta (inferior shoulder dislocation). *J Shoulder Elbow Surg.* 2010;19(3):423-426. **(Retrospective review; 16 patients)**
2. Cift H, Soylemez S, Demiroglu M, et al. Rare inferior shoulder dislocation (luxatio erecta). *Case Rep Orthop.* 2015;2015:1-3. **(Case series; 4 patients)**
3. Chaudhry S. Pediatric posterior sternoclavicular joint injuries. *J Am Acad Orthop Surg.* 2015;23(8):468-475. **(Review article)**
4. Cope R, Riddervold HO, Shore JL, et al. Dislocations of the sternoclavicular joint: anatomic basis, etiologies, and radiologic diagnosis. *J Orthop Trauma.* 1991;5(3):379-384. **(Case series; 3 patients)**
8. Riebel GD, McCabe JB. Anterior shoulder dislocation: a review of reduction techniques. *Am J Emerg Med.* 1991;9(2):180-188. **(Review article)**
9. Cole PA, Freeman G, Dubin JR. Scapula fractures. *Curr Rev Musculoskelet Med.* 2013;6(1):79-87. **(Review article)**
13. De Giorgi S, Notarnicola A, Tafuri S, et al. Conservative treatment of fractures of the clavicle. *BMC Res Notes.* 2011;4(1):333. **(Retrospective cohort; 71 patients)**
14. Paladini P, Pellegrini A, Merolla G, et al. Treatment of clavicle fractures. *Transl Med UniSa.* 2012;2:47-58. **(Review article)**
15. Buckley BJ, Hayden SR. Posterior sternoclavicular dislocation. *J Emerg Med.* 2008;34(3):331-332. **(Case report)**
16. Gallagher CA, Blakeney W, Zellweger R. Acromioclavicular joint dislocation with associated brachial plexus injury. *BMJ Case Rep.* 2014;2014(may22 1):bcr2013203299-bcr2013203299. **(Case report)**
17. Patrizio L, Sabetta E. Acute posterior shoulder dislocation with reverse Hill-Sachs lesion of the epiphyseal humeral head. *ISRN Surg.* 2011;2011:1-4. **(Case report)**
18. Saseendar S, Agarwal DK, Patro DK, et al. Unusual inferior dislocation of shoulder: reduction by two-step maneuver: a case report. *J Orthop Surg Res.* 2009;4(1):40. **(Case report)**
19. Bonz J, Tinloy B. Emergency department evaluation and treatment of the shoulder and humerus. *Emerg Med Clin N Am.* 2015;33(2):297-310. **(Review article)**
- 23.\* Rouleau DM, Hebert-Davies J, Robinson CM. Acute traumatic posterior shoulder dislocation. *J Am Acad Orthop Surg.* 2014;22(3):145-152. **(Review article)**
41. Remmler M, Schaller T. Evaluation and management of the acute anterior shoulder dislocation. *J Am Acad Physician Assist.* 2010;23(8):20-24. **(Review article)**
- 45.\* Neer CS. Displaced proximal humeral fractures: part II. Treatment of three-part and four-part displacement. *J Bone Joint Surg.* 1970;52(6):1090-1103. **(Observational study; 117 patients)** PMID: [5455340](https://pubmed.ncbi.nlm.nih.gov/5455340/)

47. Mouzopoulos G. The “Mouzopoulos” sign: a radiographic sign of posterior shoulder dislocation. *Emergency Radiology*. 2010;17(4):317-320. **(Retrospective review; 14 patients)**
50. Chien M, Bulloch B, Garcia-Filion P, et al. Bedside ultrasound in the diagnosis of pediatric clavicle fractures. *Pediatr Emerg Care*. 2011;27(11):1038-1041. **(Prospective study; 58 patients)**
51. Donnelly TD, MacFarlane RJ, Nagy MT, et al. Fractures of the clavicle: an overview. *Open Orthop J*. 2013;7(1):329-333. **(Review article)**
52. Lacy K, Cooke C, Cooke P, et al. Low-cost alternative external rotation shoulder brace and review of treatment in acute shoulder dislocations. *West J Emerg Med*. 2015;16(1):114-120. **(Review article)**
- 53.\* Lenza M, Belloti JC, Andriolo RB, et al. Conservative interventions for treating middle third clavicle fractures in adolescents and adults. *Cochrane Database Syst Rev*. 2014(5):CD007121. **(Systematic review; 3 trials, 354 patients)** DOI: [10.1002/14651858.CD007121.pub3](https://doi.org/10.1002/14651858.CD007121.pub3)
54. Wright M, Della Rocca GJ. American Academy of Orthopaedic Surgeons clinical practice guideline summary on the treatment of clavicle fractures. *J Am Acad Orthop Surg*. 2023;31(18):977-983. **(Practice guidelines)**
55. Robinson CM, Cairns DA. Primary nonoperative treatment of displaced lateral fractures of the clavicle. *J Bone Joint Surg Am*. 2004;86(4):778-782. **(Observational study; 101 patients)**
56. Ada JR, Miller ME. Scapular fractures: analysis of 113 cases. *Clin Orthop Relat Res*. 1991;269:174-180. **(Observational study; 113 patients)**
57. Nekkanti S. Isolated fractures of the body of scapula. *Malays Orthop J*. 2013;7(3):24-26. **(Case series; 2 patients)**
58. Zuckerman JD, Koval KJ, Cuomo F. Fractures of the scapula. *Instructional course lectures*. 1993;42:271-281. **(Textbook of instructional lectures)**
59. Lefevre-Colau M, Babinet A, Fayad F, et al. Immediate mobilization compared with conventional immobilization for the impacted nonoperatively treated proximal humeral fracture: a randomized controlled trial. *J Bone Joint Surg Am*. 2007;89(12):2582-2590. **(Randomized clinical trial; 64 patients)**
60. Iking J, Fischhuber K, Stolberg-Stolberg J, et al. Quality of life and pain after proximal humeral fractures in the elderly: a systematic review. *Medicina*. 2023;59(10):1728. **(Systematic review; 12 studies, 712 patients)**
61. Xu J, Zhang C, Wang T. Avascular necrosis in proximal humeral fractures in patients treated with operative fixation: a meta-analysis. *J Orthop Surg Res*. 2014;9(1):31. **(Systematic review; 7 studies, 219 patients)**
62. Morell DJ, Thyagarajan DS. Sternoclavicular joint dislocation and its management: a review of the literature. *World J Orthop*. 2016;7(4):244. **(Review article)**
63. Kirkley A, Griffin S, Richards C, et al. Prospective randomized clinical trial comparing the effectiveness of immediate arthroscopic stabilization versus immobilization and rehabilitation in first traumatic anterior dislocations of the shoulder. *Arthroscopy*. 1999;15(5):507-514. **(Randomized controlled trial; 40 patients)**
64. Yeh GL, Williams GR. Conservative management of sternoclavicular injuries. *Orthop Clin North Am*. 2000;31(2):189-203. **(Review article)**
- 65.\* Deren ME, Behrens SB, Vopat BG, et al. Posterior sternoclavicular dislocations: a brief review and technique for closed management of a rare but serious injury. *Orthop Rev (Pavia)*. 2014;6(1):5245. **(Review article)**
66. Ganeshan RM, Bakr AI. Not “just” a shoulder dislocation. *BMJ*. 2016:i4062. **(Case report)**
67. Cho C-H, Hwang I, Seo J-S, et al. Reliability of the classification and treatment of dislocations of the acromioclavicular joint. *J Shoulder Elbow Surg*. 2014;23(5):665-670. **(Observational study; 10 subjects)**
68. Chillemi C, Franceschini V, Dei Giudici L, et al. Epidemiology of isolated acromioclavicular joint dislocation. *Emerg Med Int*. 2013;2013:1-5. **(Retrospective review; 108 patients)**
69. Abat F, Sarasquete J, Natera LG, et al. Biomechanical analysis of acromioclavicular joint dislocation repair using coracoclavicular suspension devices in two different configurations. *J Orthopaed Traumatol*. 2015;16(3):215-219. **(Review article)**
70. Gai Via R, Bosco F, Giustra F, et al. Acute Rockwood type III ACJ dislocation: conservative vs surgical approach. A systematic review and meta-analysis of current concepts in literature. *Injury*. 2022;53(10):3094-3101. **(Systematic review and meta-analysis)**
71. Dala-Ali B, Penna M, McConnell J, et al. Management of acute anterior shoulder dislocation. *Br J Sports Med*. 2014;48(16):1209-1215. **(Review article)**
72. Calandra JJ, Baker CL, Uribe J. The incidence of Hill-Sachs lesions in initial anterior shoulder dislocations. *Arthroscopy*. 1989;5(4):254-257. **(Observational study; 32 patients)**
73. Atef A, El-Tantawy A, Gad H, et al. Prevalence of associated injuries after anterior shoulder dislocation: a prospective study. *Int Orthop*. 2016;40(3):519-524. **(Observational study; 240 patients)**
74. De Laat E, Visser C, Coene L, et al. Nerve lesions in primary shoulder dislocations and humeral neck fractures. A prospective clinical and EMG study. *J Bone Joint Surg Br*. 1994;76-B(3):381-383. **(Prospective study; 101 patients)**
75. Bozkurt M, Can F, Dogan M, et al. Treatment of missed posterior dislocation of the shoulder by delayed open reduction and glenoid reconstruction with corticocancellous iliac bone autograft. *Arch Orthop Trauma Surg*. 2004;124(6). **(Case report)**

76. Mastrokalos DS, Panagopoulos GN, Galanopoulos IP, et al. Posterior shoulder dislocation with a reverse Hill–Sachs lesion treated with frozen femoral head bone allograft combined with osteochondral autograft transfer. *Knee Surg Sports Traumatol Arthrosc.* 2017;25(10):3285-3288. **(Case report)**
77. Sogut O, Yigit M, Karayel E, et al. Luxatio erecta humeri: hands-up dislocation. *J Emerg Med.* 2015;49(2):e53-e55. **(Case report)**



## CME Eligible: Diagnosis and Management of Acute Otitis Media and Acute Otitis Externa for the Urgent Care Clinician

Excerpted from: Siciliano, G. Diagnosis and management of acute otitis media and acute otitis externa for the Urgent Care clinician. *Evidence-Based Urgent Care*. 2024 August;3(8):1-33. Reprinted with permission of EB Medicine.

### Treatment and Disposition

#### Acute Otitis Media

In pediatrics, current evidence and treatment guidelines support considering a “watch and wait” approach regarding antibiotics in the management of AOM. Practice guidelines from the AAP recommend holding antibiotics for 48 to 72 hours in non-severe unilateral AOM in children aged >6 months or non-severe unilateral or bilateral AOM in children aged >2 years. These recommendations are limited to healthy children without severe illness.<sup>2,4</sup> This observational approach is not recommended in the adult population as there is limited data to support this practice. While this recommendation is supported by literature, consider additional factors such as vaccination status and the ability to follow up for close reassessment.

#### *Antibiotics*

When prescribing antibiotics for AOM, the choice of antibiotic is based primarily on the most likely pathogens, as well as recent antibiotic use and consideration of patient allergies. Antibiotic recommendations have not significantly changed for AOM since the most recent AAP/AAFP practice guidelines in 2013. For AOM, amoxicillin is considered the first-line therapy. In pediatrics, high-dose amoxicillin is recommended (80-90 mg/kg divided BID), as it allows for increased concentration in the middle ear and improves efficacy against penicillin-resistant *S pneumoniae*.<sup>2,6</sup> If there is no clinical improvement in 48 to 72 hours, alternative therapy should be considered.<sup>2</sup>

Amoxicillin/clavulanate or a third-generation cephalosporin would be the preferred antibiotic if a patient has been on antibiotics in the prior month, if there is concern for treatment failure, or if there are signs of severe illness.<sup>2</sup> Risk factors for treatment failure include recurrent AOM, otorrhea, TM perforation and initial treatment with second- or third-line antibiotics.<sup>27</sup> Amoxicillin/clavulanate is also preferred for empiric treatment if there is associated purulent conjunctivitis-otitis media syndrome, as *H influenzae* is typically the predominant pathogen.<sup>2,28,29</sup> Conjunctivitis-otitis syndrome is most common in patients aged <2 years and the incidence in children with bacterial conjunctivitis ranges from 32% to 73%.<sup>28</sup> Regarding AOM with TM perforation and otorrhea, there are no studies that systematically evaluate topical therapy alone.<sup>6</sup> *S pneumoniae* and *H influenzae* are still the predominant bacteria and oral antibiotics are recommended in this population.<sup>23</sup> In children with tympanostomy tubes, topical antibiotics are recommended as first-line therapy.

#### *Penicillin Allergy*

In patients with penicillin allergy, alternative options are limited. For example, clindamycin may not cover for *H influenzae* or *M catarrhalis*, and azithromycin has limited activity against *H influenzae* and *S pneumoniae*. Unfortunately, patients often do not remember the reaction they had in the past and it is unclear if they are truly allergic to penicillin. Cephalosporins are an appropriate alternative if a patient has a history of minor reaction only to penicillin or prior tolerance to cephalosporins.<sup>1</sup> Previous literature reported a high rate of cross reactivity of up to 10% with first-generation cephalosporins. More recent literature



suggests this is an overestimation and supports that the cross reactivity with second- and third-generation cephalosporins is much less (<0.1%).<sup>2</sup> Thus, it is currently recommended to consider third-generation cephalosporins in penicillin-allergic patients with a history of only minor remote reaction to penicillin. Penicillin allergy testing is also an option but should be recommended for follow-up and is not typically feasible in the Urgent Care setting. If there is a history of severe allergy such as angioedema or anaphylaxis, other options would include clindamycin or azithromycin.<sup>2,30</sup> (See Table 5)

**Table 5. Antibiotic Treatment Recommendations for Acute Otitis Media<sup>a</sup>**

Antibiotic	Adult <sup>b,c,d</sup>	Pediatric <sup>c,d</sup>	Additional Considerations
<b>Amoxicillin</b>	875 mg BID or 500 mg every 8 hours	80-90 mg/kg/day divided BID (max dose 1 g/dose)	First-line therapy
<b>Amoxicillin/clavulanate</b>	875/125 mg BID	High-dose amoxicillin component: 80-90 mg/kg/day divided BID (max dose 1 g/dose)	<ul style="list-style-type: none"> <li>• Considered first-line therapy in adults</li> <li>• Preferred if antibiotics in prior month, more severe illness, or associated conjunctivitis</li> <li>• Additional coverage for <i>H influenzae</i> and <i>M catarrhalis</i></li> </ul>
<b>Cephalosporins</b>	<ul style="list-style-type: none"> <li>• Cefdinir: 300 mg BID</li> <li>or</li> <li>• Cefuroxime: 500 mg BID</li> <li>or</li> <li>• Cefpodoxime: 200 mg BID</li> <li>or</li> <li>• Ceftriaxone: 1-2 g IV or 1 g IM once daily for 3 days</li> </ul>	<ul style="list-style-type: none"> <li>• Cefdinir: 14 mg/kg once daily</li> <li>or</li> <li>• Cefuroxime: 15 mg/kg BID</li> <li>or</li> <li>• Cefpodoxime: 5 mg/kg BID</li> <li>or</li> <li>• Ceftriaxone: 50 mg/kg IM once daily for 3 days</li> </ul>	<ul style="list-style-type: none"> <li>• Preferred if antibiotics in prior month, more severe illness, or treatment failure</li> <li>• Consider if mild penicillin allergy or prior tolerance to cephalosporins</li> </ul>
<b>Penicillin allergy</b>	<ul style="list-style-type: none"> <li>• Clindamycin: 300 mg TID</li> <li>or</li> <li>• Azithromycin: 500 mg on day 1, then 250 mg once daily for days 2-5</li> </ul>	<ul style="list-style-type: none"> <li>• Clindamycin: 10 mg/kg TID</li> <li>or</li> <li>• Azithromycin: 10 mg/kg on day 1, then 5 mg/kg once daily for days 2-5</li> </ul>	Limited coverage against <i>H influenzae</i> , <i>M catarrhalis</i> , <i>S pneumoniae</i>

<sup>a</sup>In adults, recommendations are lacking for duration of treatment; these are based on the American Academy of Pediatrics guidelines. It is reasonable to treat mild to moderately ill patients for 5 to 7 days, and more severely ill adults, with hearing loss, severe pain, high fever, significant physical findings, or immunosuppression, for 10 days. Additional source: [UpToDate.com](https://www.uptodate.com/contents/acute-otitis-media-in-adults). Acute otitis media in adults. Limb CJ, Lustig LR, Durand ML. Updated May 29, 2024. Available at: <https://www.uptodate.com/contents/acute-otitis-media-in-adults>

<sup>b</sup>Consider doxycycline or fluoroquinolone in adults with severe penicillin allergy.

<sup>c</sup>These recommendations are based on the American Academy of Pediatrics guidelines. Recommended duration of therapy is 10 days for patients <2 years. Some sources suggest a 5- to 7-day course in patients aged >2 years, depending on severity. A 5- to 7-day course is recommended for ≥6 years. Additional source: [UpToDate.com](https://www.uptodate.com/contents/acute-otitis-media-in-children-treatment). Acute otitis media in children: treatment. Pelton SI, Tähtinen P. Updated January 16, 2024. Available at: <https://www.uptodate.com/contents/acute-otitis-media-in-children-treatment>

<sup>d</sup>Additional source: Levine BJ. *EMRA Antibiotic Guide*. 21st ed. Emergency Medicine Residents' Association; 2024.

Abbreviations: BID, twice daily; IM, intramuscular injection; TID, 3 times per day.

## Disposition

Most patients with AOM will be discharged with resolution of symptoms over the course of a week and may follow up with primary care as needed. When considering discharge, a patient must be well appearing with low suspicion for acute complication that would require hospital referral. Patients should expect some improvement within 48 to 72 hours of treatment. In the pediatric population it is important to discuss close follow-up with the patient's primary care provider and give strict ED return precautions. In 2013, the AAP published a revised clinical guideline from the 2004 AAP/AAFP clinical practice guideline for the diagnosis and management of AOM in children aged 6 months to 12 years.<sup>2,5</sup> The revision included 17 action statements. Of note, this guideline focuses on otherwise healthy children and uncomplicated AOM.

## Acute Otitis Externa

## Topical Therapy

Topical antibiotics are the mainstay of treatment for AOE.<sup>15-19</sup> Topical antibiotics are recommended as first-line therapy for AOE by the American Academy of Otolaryngology–Head and Neck Surgery Foundation (AAO-HNSF). The AAO-HNSF updated their clinical practice guidelines in 2014 for the management of AOE in patients aged  $\geq 2$  years. There is a paucity of randomized controlled trials regarding treatment for AOE, but topical therapy has been shown to be highly effective.<sup>31</sup> Current evidence, however, has not shown a significant difference among options for topical therapy<sup>16,18,32</sup> with the exception of one study in which acetic acid was found to be less effective as a sole agent if treatment was needed beyond one week of therapy.<sup>31</sup> Given similar efficacy, choice of agent is determined by cost, patient adherence, the presence or absence of a TM perforation and clinician or patient preference. Potentially ototoxic medications such as neomycin and acetic acid should be avoided if there is concern for a TM perforation or a history of tympanostomy tubes. **See Table 7** for a summary of antibiotic recommendations.

**Table 7. Antibiotic Treatment Recommendations for Acute Otitis Externa<sup>16,18</sup>**

Antibiotic	Adult Dosage <sup>b</sup>	Pediatric Dosage	Additional Considerations
Polymyxin B/neomycin/hydrocortisone	4 drops QID	3 drops QID	Avoid if TM is perforated
Ofloxacin 0.3%	10 drops once daily	5 drops once daily	<ul style="list-style-type: none"> <li>Easier dosing</li> <li>Preferred if TM is perforated</li> </ul>
Ciprofloxacin/hydrocortisone	3 drops BID	3 drops BID	Additional benefit of analgesia and reducing edema. Avoid if TM is not intact (nonsterile preparation).
Ciprofloxacin/dexamethasone	4 drops BID	4 drops BID	Additional benefit of analgesia and reducing edema. May use with nonintact TM.
Acetic acid 2% or Acetic acid 2%/hydrocortisone	5 drops QID	5 drops QID	<ul style="list-style-type: none"> <li>Antiseptic</li> <li>Consider in mild cases</li> <li>Avoid if TM perforated</li> </ul>
Ciprofloxacin PO <sup>c</sup>	500 mg BID	–	For very severe illness or if history of diabetes, immunocompromised, or elderly

Abbreviations: BID, twice daily; PO, oral; QID, 4 times per day; TM, tympanic membrane.

Recommended duration of therapy for AOE is 7 to 10 days.

<sup>a</sup>Can consider cephalosporin or amoxicillin/clavulanate orally with history of severe fluoroquinolone allergy.

<sup>b</sup>Additional sources: [UpToDate.com](https://www.uptodate.com). External otitis in adults: treatment. Goguen LA, Durand ML. Updated December 1, 2023. Available at: <https://www.uptodate.com/contents/external-otitis-in-adults-treatment>; Levine BJ. *EMRA Antibiotic Guide*. 21st ed. Emergency Medicine Residents' Association; 2024. [www.ebmedicine.net](http://www.ebmedicine.net)

Topical antibiotics with corticosteroids such hydrocortisone or dexamethasone have been shown to help with analgesia and canal edema.<sup>16</sup> In uncomplicated AOE treated with topical therapy, 65% to 90% of patients improve within 7 to 10 days.<sup>17</sup> Treatment failure is considered if there is a need for additional therapy beyond two weeks.<sup>31</sup>

Both the AAO-HNSF and United Kingdom National Institute for Health and Care Excellence (NICE) guidelines recommend initial therapy of uncomplicated AOE with topical therapy.<sup>16,33</sup> Topical therapy is considered highly effective and results in high concentrations at the site of infected tissue and is considered superior to oral therapy.<sup>15,16,18</sup> There is no significant benefit of adding an oral antibiotic in addition to topical therapy in uncomplicated AOE.<sup>34</sup> Although oral therapy is not recommended in uncomplicated AOE, 20% to 40% of patients still receive oral antibiotics with or without concurrent topical therapy.<sup>16</sup> Furthermore, treatment with oral penicillin, macrolides, or cephalosporins can increase disease persistence and recurrence.<sup>16,33</sup> Oral antibiotics with pseudomonal coverage may be considered in AOE to prevent progression to severe disease

if a patient is immunocompromised, diabetic, elderly, has extension of infection outside of EAC, or is having difficulty with topical therapy.<sup>15,16</sup>

If a fungal etiology is suspected, otolaryngology referral is recommended for advanced aural toilet and acetic acid, or a topical antifungal such as clotrimazole would be appropriate.

### *Disposition*

Similarly to AOM, most patients with AOE will be discharged with expected resolution of symptoms over the course of a week. When discharging patients with topical antibiotics for AOE, it is important to review proper administration to avoid incomplete treatment or treatment failure. When administering topical antibiotics, consider having another person assist with drop administration. The patient should be lying down on their side with the affected ear up and stay in this position for at least 5 minutes after drops are administered. Consider, also, an ear wick if there is significant edema or difficulty with antibiotic administration.<sup>16</sup> Recommend to the patient who uses hearing aids to avoid their use if possible until the infection clears. It is important to tell the patient to avoid moisture or water in the ear when showering and avoid water sports for 7 to 10 days.

## **Additional Therapies for Acute Otitis Media and Acute Otitis Externa**

### Aural Toilet

Aural toilet is a general term that refers to various methods of cleaning the ear from debris and cerumen. It plays an important role in the diagnosis and management of acute otalgia, as poor visualization of the EAC or TM can lead to misdiagnosis. In AOE, removal of debris and purulent material can aid in healing and penetration of topical antibiotics.<sup>16,17</sup> There are several methods to remove debris and cerumen (ie, suction, dry mopping, irrigation, curette). It is common in the Urgent Care setting to use a curette under direct visualization or gentle irrigation to remove cerumen and improve visualization of the EAC and TM. No one method has been shown to be superior, and there is insufficient evidence regarding the effectiveness of various aural toilet methods.<sup>1,31,35</sup> Irrigation methods should be avoided if there is a TM perforation or if you are uncertain of the presence of a TM perforation. Irrigation also should be avoided if the patient is diabetic or immunocompromised, as ear lavage has been implicated as a contributing factor to MOE.<sup>16</sup> If there is difficulty with attempts to remove debris or cerumen, a TM perforation is present, or there is need for additional aural toilet for AOE management, refer the patient to otolaryngology.

### Pain Management

Pain management is essential in the management of AOM and AOE. Symptom relief is also highly associated with patient and parent satisfaction.<sup>16</sup> Acetaminophen and nonsteroidal anti-inflammatory drugs (NSAIDs) are appropriate oral options for pain relief and fever. There is some evidence that NSAIDs can significantly reduce pain in AOE.<sup>16</sup> Pain caused by AOE can be severe due to the highly sensitive periosteum in proximity to ear canal skin. Several topical antibiotic options for AOE are combined with topical corticosteroids, which have been shown to improve pain and inflammation quickly in AOE.<sup>16,18</sup> Recent literature regarding anesthetic drops has shown a reduction in pain but there is currently a lack of high-quality evidence, as such drops are potentially ototoxic and not currently recommended.<sup>1,19,36-38</sup> In severe cases of AOM or AOE, as well as complications such as mastoiditis or MOE, there may be a role for parenteral therapy for acute pain management.

### Adjunctive Therapies

Decongestants, antihistamines, and nasal steroids do not hasten the clearance of middle ear fluid and are not recommended as adjunctive therapies for AOM in pediatrics.<sup>3</sup> However, such adjuncts may be considered for symptom control in the adult population. Complementary and alternative therapies have also been used for acute otalgia. There is insufficient evidence to support the use of such therapies, but clinicians should be aware that herbal remedies, homeopathy, and nutritional supplements exist and are being used to treat acute otalgia.<sup>1,36</sup> Finally, it is important to mention the practice of “candling.” Ear candling involves placing a lit, hollow candle in the ear to create a low-level vacuum to soften and clear cerumen and debris. There is no evidence to support this practice and patients can sustain injuries from its use.<sup>16</sup>

## 5 Things That Will Change Your Practice

1. **Weigh the risks and benefits of antibiotic options for AOM in patients with a reported history of penicillin allergy.** Clarify the severity of the allergy and assess if the patient would be eligible to take a third-generation cephalosporin for treatment. Penicillin allergy testing should be recommended.
2. **Choose topical therapy for AOE over oral antibiotics in uncomplicated cases.** Where there is diagnostic uncertainty, patients are often treated for both otitis media and otitis externa. Determine severity of AOE using a thorough patient history, complete HEENT examination, and otoscopic findings.
3. **Educate patients and parents regarding proper ear care and administration of topical antibiotics.** Incorporating clear, simple discharge instructions regarding proper ear care will help patients feel more confident about their home care. Appropriate discharge instructions will help avoid treatment failure and reduce repeat visits.
4. **Know when to refer a patient to otolaryngology and when to refer to the ED.** Indications for referral to otolaryngology include recurrent episodes of illness, perforated TM, retained foreign body, persistent hearing loss, and tinnitus. Refer a patient to the ED with signs of severe disease requiring more advanced care.
5. **Consider a 48- to 72-hour observation period without antibiotics for AOM in the pediatric population.** The current recommendation by the AAP for healthy children aged >6 months without signs of severe disease is the “watch and wait” approach, which has not resulted in an increase in suppurative complications.<sup>2</sup> The risks and benefits of this option must be weighed, and a mechanism must be in place to ensure follow-up and begin antibiotics if a child fails observation. This approach has challenges in the Urgent Care setting, but a SNAP prescription may be an alternative, more feasible approach.

## References

1. Gaddey HL, Wright MT, Nelson TN. Otitis media: rapid evidence review. *Am Fam Physician*. 2019;100(6):350-356. **(Review)**
- 2.\* Lieberthal AS, Carroll AE, Chonmaitree T, et al. The diagnosis and management of acute otitis media. *Pediatrics*. 2013;131(3):e964-e999. **(Evidence-based clinical practice guideline) DOI: 10.1542/peds.2012-3488**
3. Harmes KM, Blackwood RA, Burrows HL, et al. Otitis media: Diagnosis and treatment. *Am Fam Physician*. 2013;88(7):435- 440. **(Review)**
- 4.\* Schilder AG, Chonmaitree T, Cripps AW, et al. Otitis media. *Nat Rev Dis Primers*. 2016;2(1):16063. **(Review) DOI: 10.1038/nrdp.2016.63**
5. American Academy of Pediatrics Subcommittee on Management of Acute Otitis Media. Diagnosis and management of acute otitis media. *Pediatrics*. 2004;113(5):1451-1465. **(Evidence-based clinical practice guidelines)**
6. El Feghaly RE, Nedved A, Katz SE, et al. New insights into the treatment of acute otitis media. *Expert Rev Anti Infect Ther*. 2023;21(5):523-534. **(Expert review)**
15. Jackson EA, Geer K. Acute otitis externa: Rapid evidence review. *Am Fam Physician*. 2023;107(2):145-151. **(Review)**
- 16.\* Rosenfeld RM, Schwartz SR, Cannon CR, et al. Clinical practice guideline: acute otitis externa. *Otolaryngol Head Neck Surg*. 2014;150(1 Suppl):S1-S24. **(Evidence-based clinical practice guideline) DOI: 10.1177/0194599813517083**
17. Wiegand S, Berner R, Schneider A, et al. Otitis externa. *Dtsch Arztebl Int*. 2019;116(13):224-234. **(Review)**
18. Schaefer P, Baugh RF. Acute otitis externa: an update. *Am Fam Physician*. 2012;86(11):1055-1061. **(Review)**

19. Plum AW, Wong M. An overview of acute otitis externa. *Otolaryngol Clin North Am*. 2023;56(5):891-896. **(Review)**
27. Ron DM, Ovnat Tamir S, Marom T. What are the risk factors for acute otitis media treatment failure? *Int J Pediatr Otorhinolaryngol*. 2022;158:111158. **(Retrospective, single center study; 335 patients)**
28. Hu YL, Lee PI, Hsueh PR, et al. Predominant role of Haemophilus influenzae in the association of conjunctivitis, acute otitis media, and acute bacterial paranasal sinusitis in children. *Sci Rep*. 2021;11(1):11. **(Prospective observational study; 67 patients)**
29. Sugita G, Hotomi M, Sugita R, et al. Genetic characteristics of Haemophilus influenzae and Streptococcus pneumoniae isolated from children with conjunctivitis-otitis media syndrome. *J Infect Chemother*. 2014;20(8):493-497. **(Prospective study; 110 patients)**
30. Marchisio P, Galli L, Bortone B, et al. Updated guidelines for the management of acute otitis media in children by the Italian Society of Pediatrics: treatment. *Pediatr Infect Dis J*. 2019;38(12S Suppl):S10-S21. **(Evidence-based clinical practice guidelines)**
31. Kaushik V, Malik T, Saeed SR. Interventions for acute otitis externa. *Cochrane Database Syst Rev*. 2010(1):CD004740. **(Cochrane review; 19 studies, 3382 patients)**
32. Di Traglia R, Tudor-Green B, Muzaffar J, et al. Antibiotics versus nonantibiotic treatments for acute otitis externa: a systematic review and meta-analysis. *Clin Otolaryngol*. 2023;48(6):841-862. **(Systematic review and meta-analysis; 17 studies, 10 studies in meta-analysis)**
33. Mughal Z, Swaminathan R, Al-Deerawi HB, et al. A systematic review of antibiotic prescription for acute otitis externa. *Cureus*. 2021;13(3):e14149. **(Systematic review; 7 studies, 31,650 patients)**
34. Rasheed AM, Hilal SA, Abbas AM. Is adding an oral antibiotic with the topical antibiotic steroid useful in treatment of uncomplicated acute otitis externa in immunocompetent patients? *J Popul Ther Clin Pharmacol*. 2022;29(2):e27-e32. **(Prospective comparative clinical study; 68 patients)**
35. Bhutta MF, Head K, Chong LY, et al. Aural toilet (ear cleaning) for chronic suppurative otitis media. *Cochrane Database Syst Rev*. 2020;9(9):CD013057. **(Cochrane review; 3 studies, 431 patients)**
36. Foxlee R, Johansson A, Wejfalk J, et al. Topical analgesia for acute otitis media. *Cochrane Database Syst Rev*. 2006;2006(3):CD005657. **(Cochrane review; 5 studies, 391 patients)**
37. Kara A, Buyukcam A, Sutcu M, et al. The effectiveness of topical 1% lidocaine with systemic oral analgesics for ear pain with acute otitis media. *Int J Pediatr Otorhinolaryngol*. 2022;156:111116. **(Multicenter, randomized, open label study; 184 patients)**
38. Michel O. Pain relief by analgesic eardrops: paradigm shift in the treatment of acute otitis media? *Drug Res (Stuttg)*. 2021;71(7):363-371. **(Review)**
-

# Urgent Updates



## CME Eligible: General Urgent Care Medicine Highlights

### **Benzathine Penicillin G Shortage**

In January of 2024, Pfizer announced a shortage of long acting benzathine penicillin G (Bicillin-LA) due to increased demand. The CDC recommends treating syphilis patients with doxycycline if penicillin is not available. The exception to this is pregnant women with syphilis, who should receive penicillin G. This prompted some states to announce that remaining benzathine penicillin G was to be reserved for only pregnant women, and all other patients with syphilis to be treated with doxycycline. Pfizer announced this month that benzathine penicillin G would now have more availability but predicts shortages may be expected through 2024.

The challenges in Urgent Care include availability, cost, need for refrigerated storage, and infrequent use of benzathine penicillin G. There is also a concern with doxycycline that patients may not be compliant with a full course of treatment. It is much easier to ensure treatment when it is provided in a single dose in center at the time of diagnosis. Although other medications such as ceftriaxone, doxycycline and azithromycin have been used successfully to treat syphilis, studies have only supported the use of benzathine penicillin G. For this reason, the only recommended treatment per CDC guidelines is benzathine penicillin G.

The CUCM Clinical Response Committee supports the use of benzathine penicillin G for the treatment of primary and secondary syphilis per CDC guidelines. We recommend clinics stock benzathine penicillin G if possible. If this is not feasible, or unavailable, we recommend aligning with your local public health department or other local clinic or hospital to arrange for patients to receive benzathine penicillin G in a timely fashion. Patients should be treated with doxycycline only if no other option for benzathine penicillin G exists.

For more information:

<https://www.cdc.gov/std/treatment-guidelines/p-and-s-syphilis.htm>

<https://www.cdc.gov/std/treatment/drug-notices.htm>

### **FDA Approves First Nasal Spray for Treatment of Anaphylaxis**

On August 9, the U.S. Food and Drug Administration approved neffy (epinephrine nasal spray) for the emergency treatment of allergic reactions (Type I), including those that are life-threatening (anaphylaxis), in adult and pediatric patients who weigh at least 30 kilograms (about 66 pounds). Neffy is a single dose nasal spray administered into one nostril, a second dose (using a new nasal spray to administer neffy in the same nostril) may be given if there is no improvement in symptoms or symptoms worsen. Patients may need to seek emergency medical assistance for close monitoring of the anaphylactic episode and in the event further treatment is required. **Full Access:** [CDC](#)

### **FDA Marketing Authorization Enables Increased Access to First Step of Syphilis Diagnosis**



COLLEGE OF  
URGENT CARE  
MEDICINE

[www.urgentcarecollege.org](http://www.urgentcarecollege.org)



URGENT CARE  
COLLEGE OF  
PHYSICIANS

[www.uccop.org](http://www.uccop.org)

### **First Home Antibody Test Can Inform Patients of Current or Past Infection and Lead to Confirmatory Testing with Healthcare Clinician**

On August 16<sup>th</sup>, the U.S. Food and Drug Administration granted marketing authorization to NOWDiagnostics for the first to know syphilis test. This is the first at-home, over-the-counter test to detect *Treponema pallidum* (syphilis) antibodies in human blood. Results from this type of test alone are not sufficient to diagnose syphilis infection and should be followed by additional testing to confirm a diagnosis of syphilis. **Full Access:** [FDA](#)

### **How to Prevent Heat-Related Illness in Pediatric Patients**

2024 has somehow broken more records, with the planet recording its hottest day last week in Washington, D.C. While climate change has an impact on everyone, we don't all share an equal burden of its consequences. Groups that disproportionately experience more of those negative outcomes are individuals with disabilities, the elderly, and children. **Full Access:** [MDPage](#)

### **Dengue Fever's Worrisome Surge**

While 2023 saw 4.6 million reported cases of dengue in the Americas, this year's count had already doubled, reaching 9.7 million. And that's before much of the region would have entered its highest-transmission months. But as more people travel, local cases can also climb because at least 30 US states harbor the two black-and-white mosquitoes that can easily transmit dengue from a viremic carrier to someone else. **Full Access:** [MDPage](#)

### **Are Doctors Missing Cases of H5N1 Bird Flu in People Who Drink Raw Milk?**

Raw milk from cows infected with the H5N1 bird flu has been shown to contain very high levels of the virus, making it quite risky for people to consume. Emergency Departments and healthcare professionals have received communications from health authorities to be aware of potential H5N1 infections. **Full Access:** [MDPage](#)

### **Increase in Human Parvovirus B19 Activity in the United States**

The Centers for Disease Control and Prevention (CDC) is issuing this Health Alert Network (HAN) Health Advisory to notify healthcare clinicians, public health authorities, and the public about current increases in human parvovirus B19 activity in the U.S. In the U.S., there is no routine surveillance for parvovirus B19, and it is not a notifiable condition. Recently, CDC has received reports indicating increased parvovirus B19 activity in the U.S. **Full Access:** [CDC](#)

### **Increased Oropouche Virus Activity and Associated Risk to Travelers**

The Centers for Disease Control and Prevention (CDC) is issuing this Health Alert Network (HAN) Health Advisory to notify of an increase in Oropouche virus disease in the Americas region. Between January 1 and August 1, 2024, more than 8,000 cases of Oropouche virus disease were reported, including two deaths and five cases of vertical transmission associated with fetal death or congenital abnormalities. In the U.S. and Europe in 2024, travel-associated cases have been identified in travelers returning from Cuba and Brazil. As testing and surveillance for Oropouche virus disease increase in the Americas, reports of cases from additional countries are expected. This Health Advisory advises on evaluating and testing travelers who have been in impacted areas with signs and symptoms consistent with Oropouche virus infection. **Full Access:** [CDC](#)

### **Pertussis Surveillance and Trends**

In 2024, reported cases of pertussis increased across the U.S., indicating a return to more typical trends. Preliminary data show that more than four times as many cases have been reported as of week 32, reported on August 10, 2024, compared to the same time in 2023. The number of reported cases this year is higher than what was seen at the same time in 2019, prior to the pandemic. **Full Access:** [CDC](#).



COLLEGE OF  
URGENT CARE  
MEDICINE

[www.urgentcarecollege.org](http://www.urgentcarecollege.org)



URGENT CARE  
COLLEGE OF  
PHYSICIANS

[www.uccop.org](http://www.uccop.org)



## CME Eligible: Urgent Updates in Pediatric Research

**Ivan Koay, MBChB, MRCS, FRNZCUC, MD**

Urgent Care Physician and Medical Lead Kings College Hospital Urgent Treatment Centre, London, United Kingdom

Convenor Ireland and UK Faculty of the Royal New Zealand College of Urgent Care

### **Inequalities of Antibiotic Prescribing – Does Race Play a Factor?**

Prescribing antibiotics to non-guideline recommendations is low-value care. This was a cross-sectional analysis of antibiotic prescribing of five EDs in the Baltimore/Washington metropolitan area. The rate of inappropriate acute respiratory tract infection prescribing for children was 2.5%. After adjusting for area deprivation index, sex, comorbidities, and other patient-level factors, Caucasian patients had 1.32 (95% confidence interval [CI], 1.26 to 1.38) higher relative risk of receiving an inappropriate prescription compared to African American patients.

**Editor’s Comments:** The retrospective nature of the study and its reliance on coding of conditions may bias the findings, particularly if there were systematic differences in recording by race, ethnicity, or socioeconomic level. There were a large number of patients in this study who reported race as “Other,” which may bias the findings. Urgent Care clinicians need to be aware of all factors that lead to care disparities, including with use of treatments outside best practices.

Klein E, Saheed M, Irvin N, et. al. Racial and Socioeconomic Disparities Evident in Inappropriate Antibiotic Prescribing in the Emergency Department *Ann Emerg Med.* 2024 Aug;84(2):101-110. doi: 10.1016/j.annemergmed.2023.12.003

### **Point of Care Ultrasound (POCUS) Training**

**Editor’s Comments:** Point-of-care ultrasound (POCUS) is a well-established tool that is being increasingly incorporated into the care of children presenting to the EDs. As Urgent Care clinicians consider areas of added value, leveraging the use of POCUS in UCCs can enhance the quality of service provided and in certain cases reduce unnecessary referrals to EDs. Reflection of how advanced POCUS training can be designed to meet the requirements of the present workforce is prudent. Strategic review of Urgent Care curriculums both in the U.S., Canada and worldwide that incorporates POCUS training, would also help in ensuring long-term Urgent Care service provision that fits within the wider healthcare sector. This is particularly relevant for sectors where Urgent Care isn’t recognized as a specialty presently.

Moake M., Klekowski N., Kusulas P., et. al. The Current State of Advanced Pediatric Emergency Medicine Point-of-Care Ultrasound (POCUS) Training: Exploring Recent POCUS Fellowship Application Trends and Alternate Training Models. *Pediatric Emergency Care.* <https://doi.org/10.1097/PEC.0000000000003161>

### **Our Role in Preventing Pediatric Maltreatment**

This clinical report focuses on the prevention of child maltreatment and makes recommendations to clinicians of pediatric care to integrate child maltreatment prevention opportunities.

The take home points for Urgent Care clinicians and practitioners are:



- Obtain a thorough social history, throughout a patient’s childhood, including family economic stressors and community conditions.
- Being alert to indicators of parental intimate partner violence, unhealthy substance use, and depression. Familiarize ourselves with appropriate community resources and know how to respond if a caregiver reports such problems.
- Encourage caregivers to use their own healthcare providers as a conduit to needed care. Become knowledgeable about resources in the community and, when appropriate, refer families to these resources.
- Offer practical guidance in supporting the child or adolescent to caregivers, monitor frequently for signs and symptoms of toxic stress and continued maltreatment, and recommend therapeutic interventions and mental health services.

Stirling J, Gavril A, Brennan B, et. al., American Academy of Pediatrics, Council on Child Abuse and Neglect. The Pediatrician’s Role in Preventing Child Maltreatment: Clinical Report. Pediatrics. 2024;154(2): e2024067608

## AAP RESOURCES

- Practice Tips - Screening for Basic and Social Needs and
- Connecting Families to Community Resources: <https://www.aap.org/en-us/advocacy-and-policy/aap-healthinitiatives/poverty/Pages/practice-tips.aspx>
- AAP Trauma-Informed Care Resources: [www.aap.org/tic](http://www.aap.org/tic)
- AAP Early Relational Health Resources: <https://www.aap.org/en/patient-care/early-childhood/early-relational-health/>
- Bright Futures: [Brightfutures.aap.org](http://Brightfutures.aap.org)

## **Bracing and Home Management for Distal Radius Buckle Fractures**

The authors in this study used the strict definition to define buckle fractures as unicortical fractures of the distal radius without cortical breach or fracture lucency extending to the physis seen on one or more views of the wrist. These fractures may involve the volar or dorsal cortex. “The 1-cm Rule,” also aids diagnosis of buckle fractures by discouraging the diagnosis of a buckle fracture if the most proximal cortical inflection point is less than 1 cm from the physis. The authors used commercially available removable brace devices to treat these fractures. A shared decision-making process was used between the clinician and the caregivers of children. Ninety-six percent of the children with dorsal buckle fractures were discharged from the initial acute care visit with a removable brace. There were no adverse effects from the treatment or treatment failures

**Editor’s Comments:** There is increasing evidence to support minimalist intervention and follow-up requirements for buckle fractures in the wrist. This study further justifies the ‘less is more’ approach, although clinicians should have a shared decision-making process with caregivers of patients with these injuries. Treatment of children in the UK has moved towards this approach.

Nandigam M, Chmil M, Thompsom B, et. al. Volar Distal Radius Buckle Fractures: Is Bracing and Home Management Safe? *Pediatr Emerg Care*. 2024 Aug 1;40(8): e159-e163. doi: 10.1097/PEC.0000000000003177.



# CAUSE FOR APPLAUSE



## Welcome CUCM's Newest Fellows

And finally, we would like to welcome the following new fellows of the College of Urgent Care Medicine. Fellows represent the best of us who work every day to provide the highest quality of medicine and advance the specialty of Urgent Care medicine.

**Corbin Bunnage, PA-C, FCUCM** serves as the Clinical Services Director and Managing Partner for Sterling Provider Group/ Sterling Urgent Care. Sterling Urgent Care is a multi-site, multi-state Urgent Care organization. Corbin is also a physician assistant educator at Idaho State University. He received his bachelor's degree in P.A. Studies at Idaho State and an M.S. in family and emergency medicine from A.T. Stills University in Mesa, AZ.



**Jacob Anderson, DNP, FNP-C, FCUCM** received both his bachelors and DNP degrees from the University of Utah and is also certified as a family nurse practitioner through AANP. He has been with Sterling Urgent & Family Medicine (UT, WY, and ID) since 2015 where he has served as a provider manager and preceptor for NP students around the country. He participates in research studies as the study administrator through the University of Texas while also serving in the Utah Air National Guard Commission as a Captain in 151 MDG.

Do you have interest in being recognized as a Fellow? Requirements include actively practicing as a physician, PA or NP with a solid foundation in Urgent Care and being an active member of CUCM for at least one year. Further requirements can be found [here](#). Those who achieve fellowship status will be entitled to use the initials FCUCM for as long as they remain members of the College.

We wish to thank the following organizations for their insightful contributions to this quarter's Urgent Caring:



## Advertising in Urgent Caring

### Interested in advertising in the Urgent Caring publication?

Email [corporate@urgentcareassociation.org](mailto:corporate@urgentcareassociation.org) for more information.

# URGENT CARING

A publication from the College of Urgent Care Medicine

**2,000+**

Clinical UCA member audience

**46%**

Average Click Through Rate

You provide the products and services, clinicians use the product and services – make the connection:

Advertise in the College of Urgent Care Medicine (CUCM) quarterly Urgent Caring Publication a CME publication dedicated to informing readers on clinical insights, industry updates and more.

Market within the downloadable publication to a targeted audience of more than 2,000 clinical UCA members who need your solutions and use your products daily.

**MEMBER RATE: \$600**

**NON-MEMBER RATE: \$750**

### Secure Your Date Today

Contact: [corporate@urgentcareassociation.org](mailto:corporate@urgentcareassociation.org)



[www.urgentcarecollege.org](http://www.urgentcarecollege.org)



[www.uccop.org](http://www.uccop.org)