

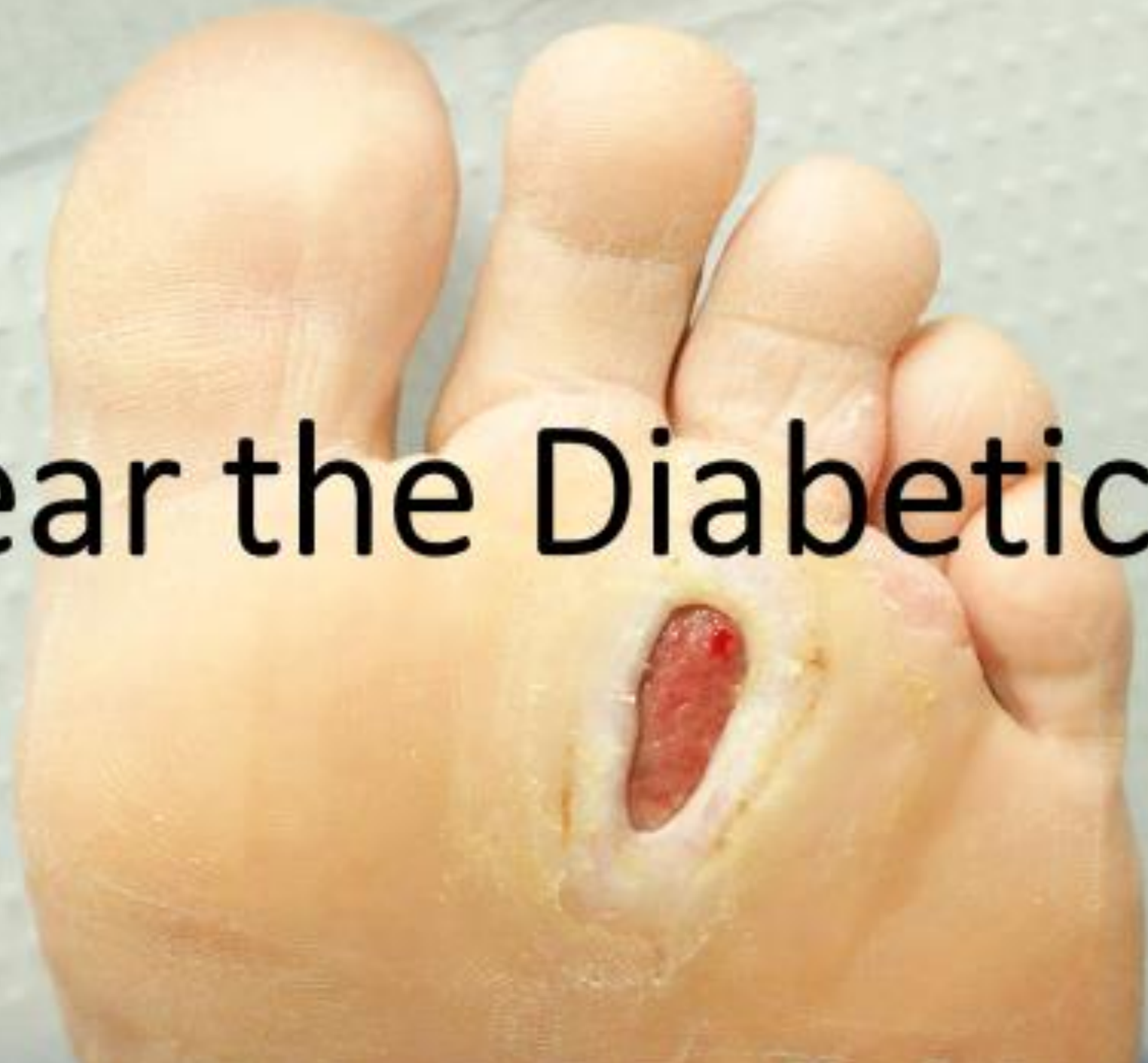Wound Care: Urgent Care Pearls & Pitfalls: Diabetic foot



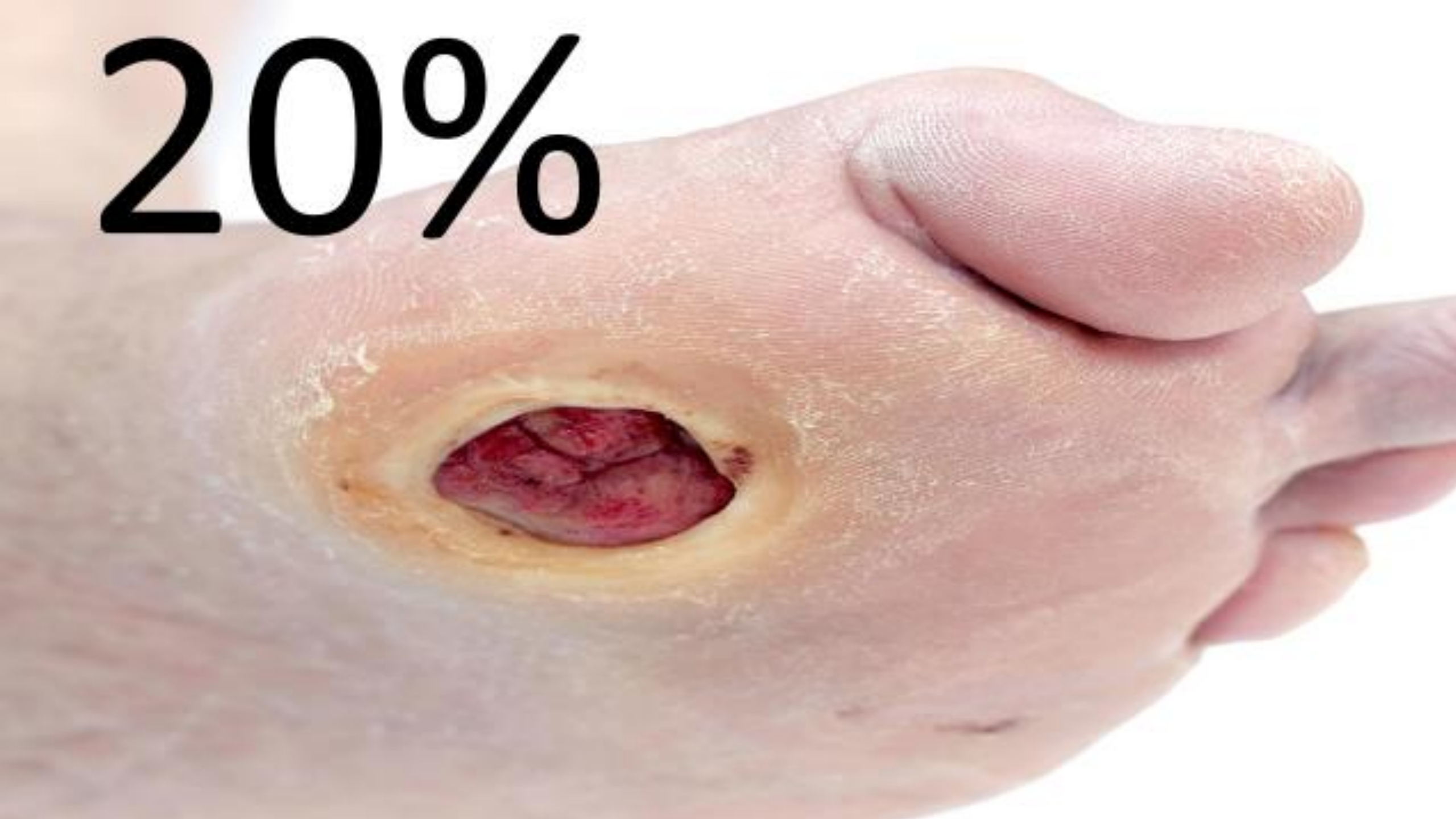
Presented by
Matt Delaney, MD
Kelly Heidepriem, MD

Presented by UCA Affiliate
HIPPO
EDUCATION

Fear the Diabetic Foot



20%



A photograph of a light-colored, rectangular gravestone with a rounded top, set in a grassy field. The number '50%' is printed in large, bold, black font across the center of the stone. The stone is mounted on a low, wide base. The background is a dense field of green grass.

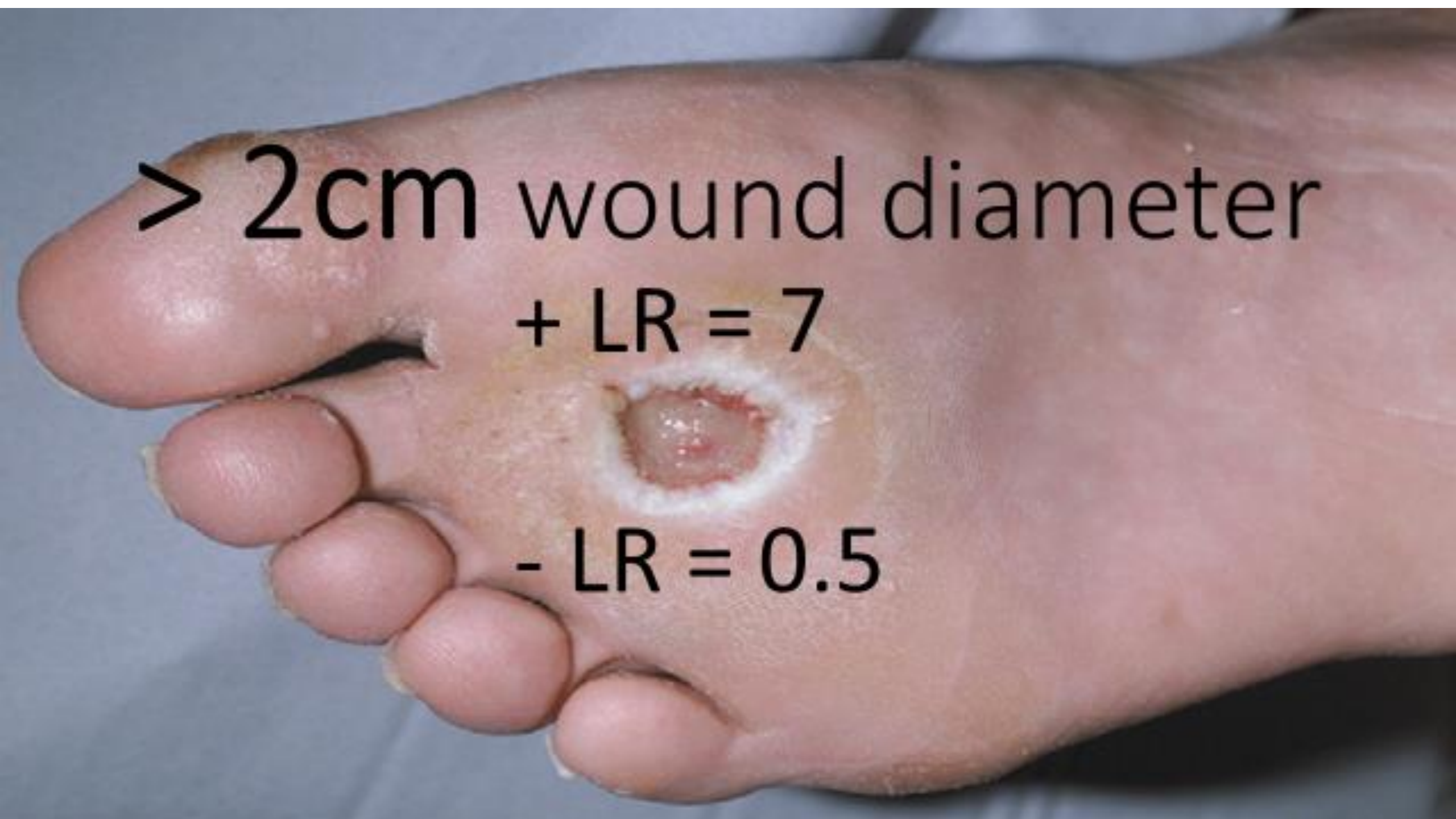50%



> 2cm wound diameter

+ LR = 7

- LR = 0.5





Probe to bone

LR: + = **6.5** - = **0.4**

ESR > 70mm/hr

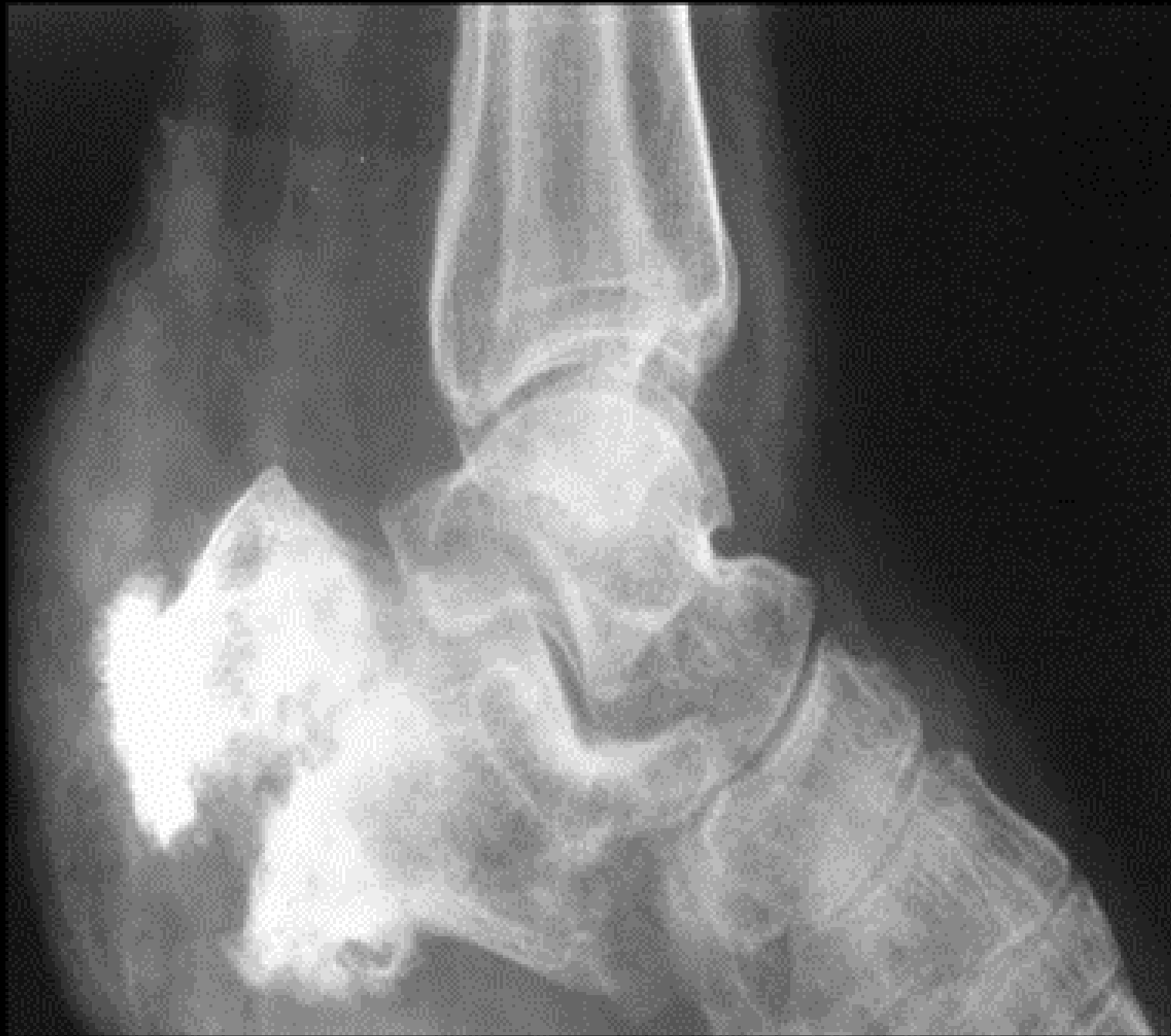

LR:

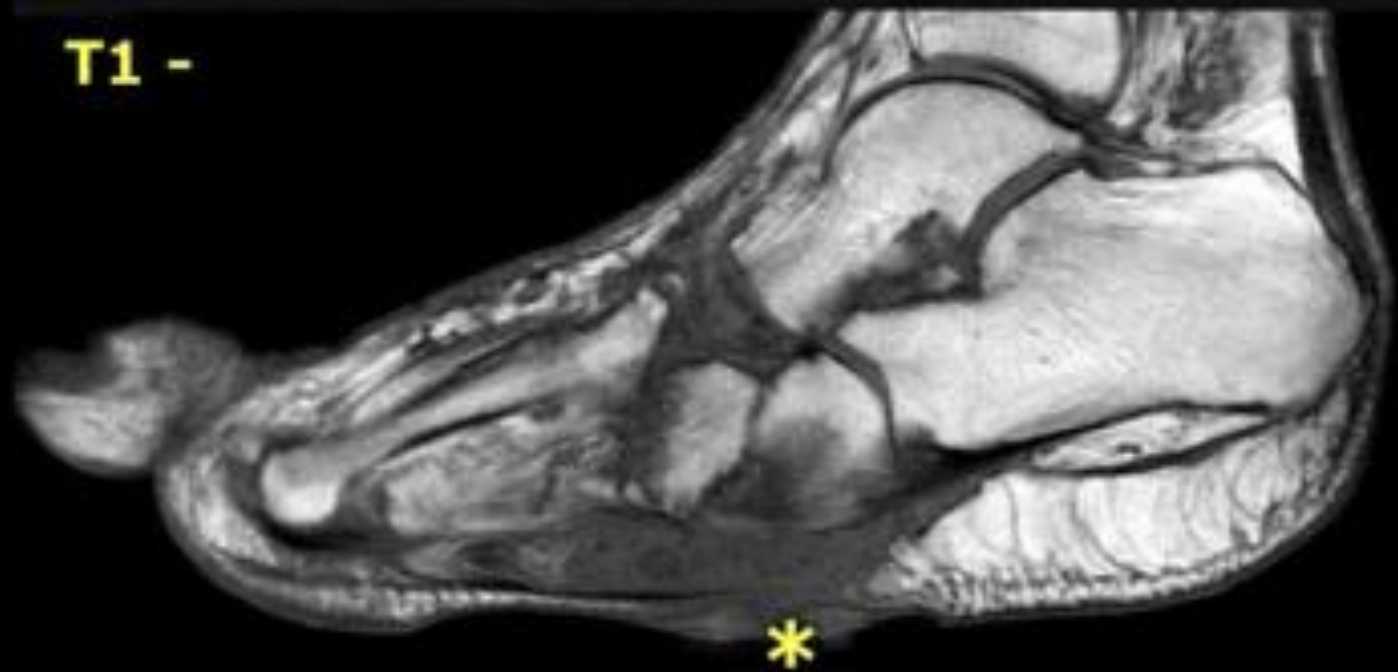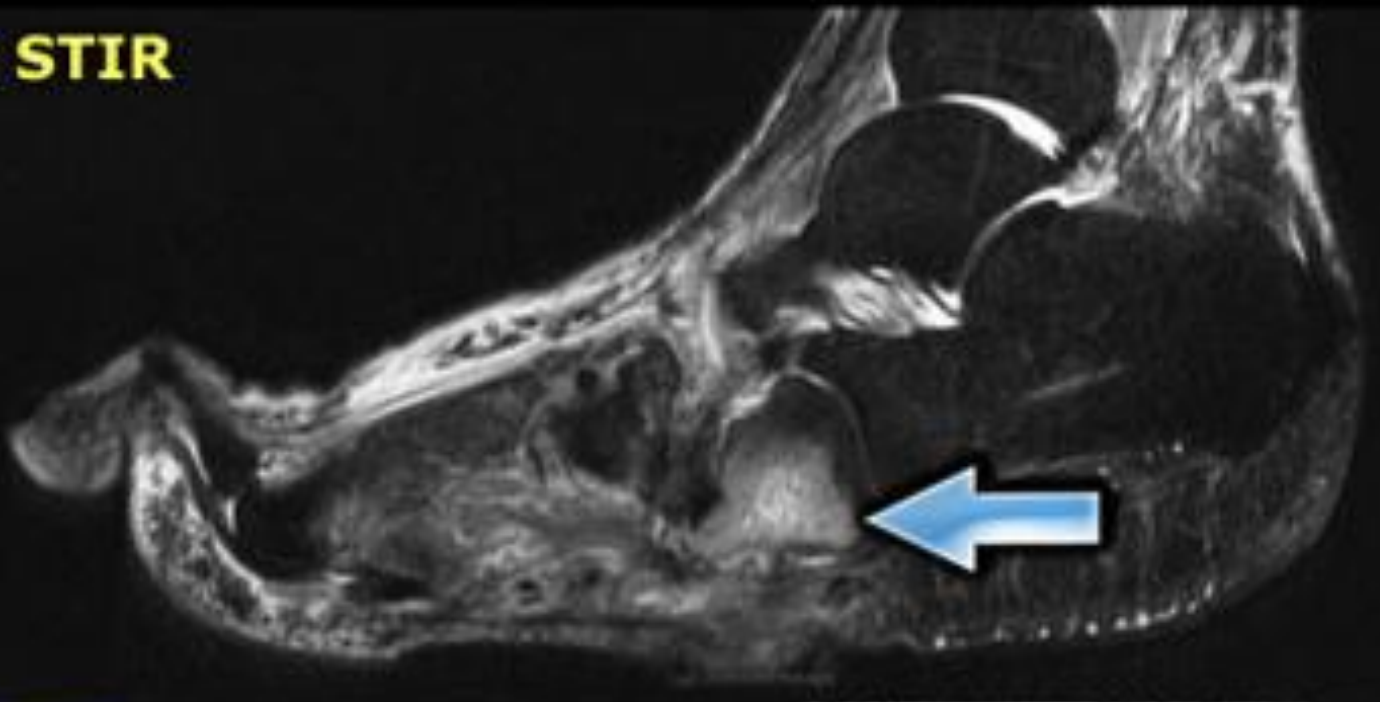
+ = 11.3

- = 0.3

LR:
+ = 2.3
- = 0.6



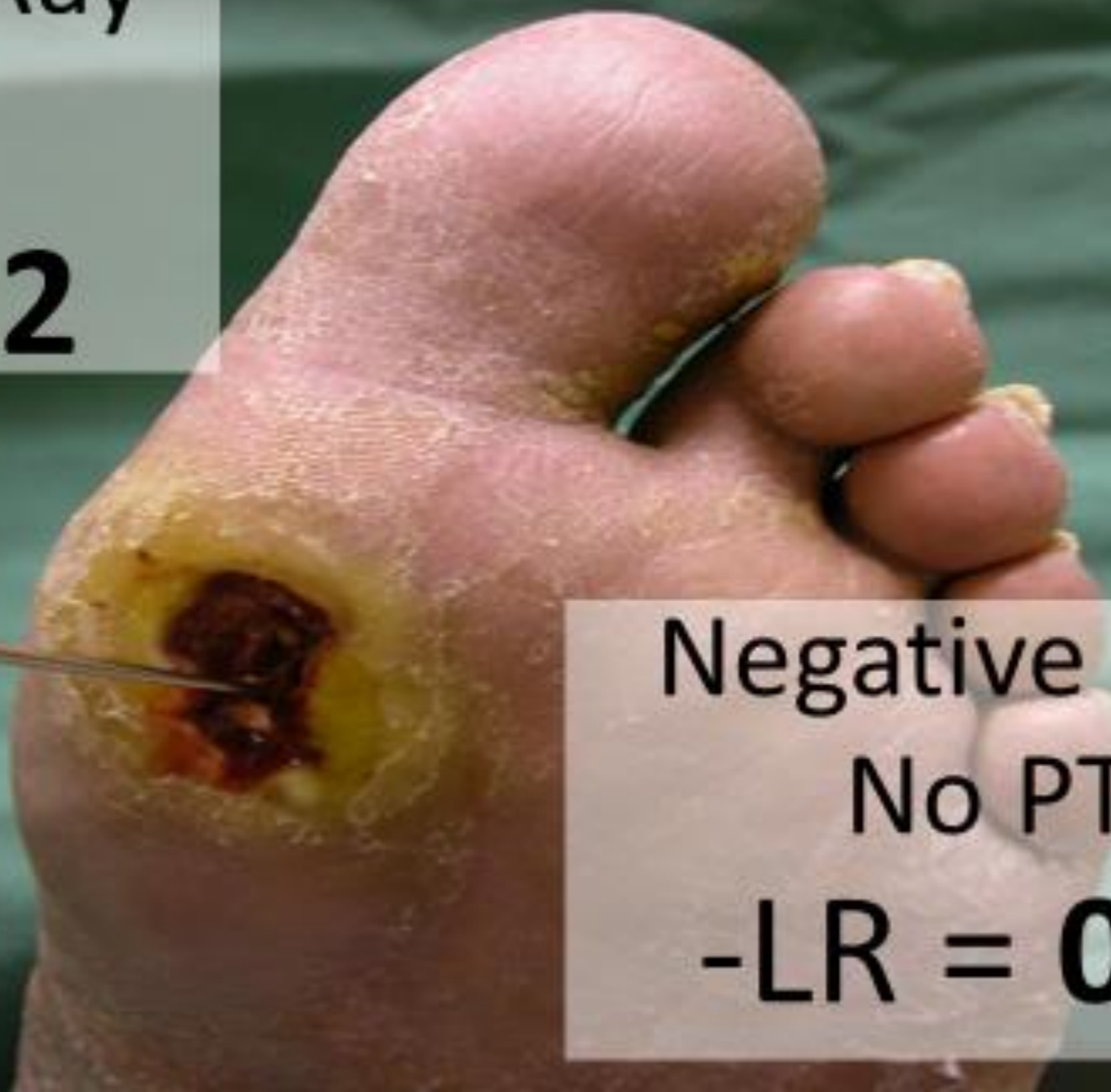LR:
+ = 3.8
- = 0.14



Positive X-Ray

+ PTB

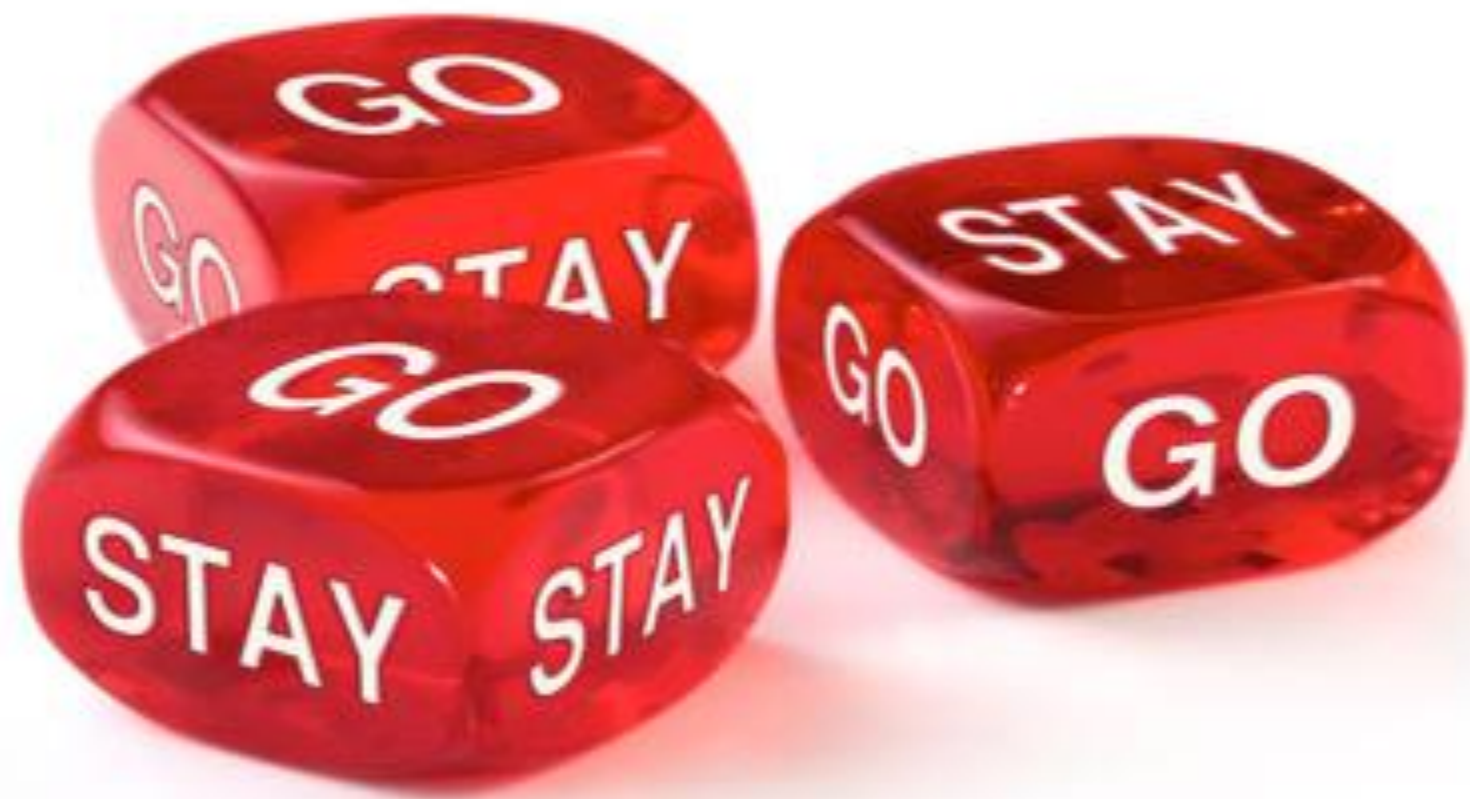+LR = **12**



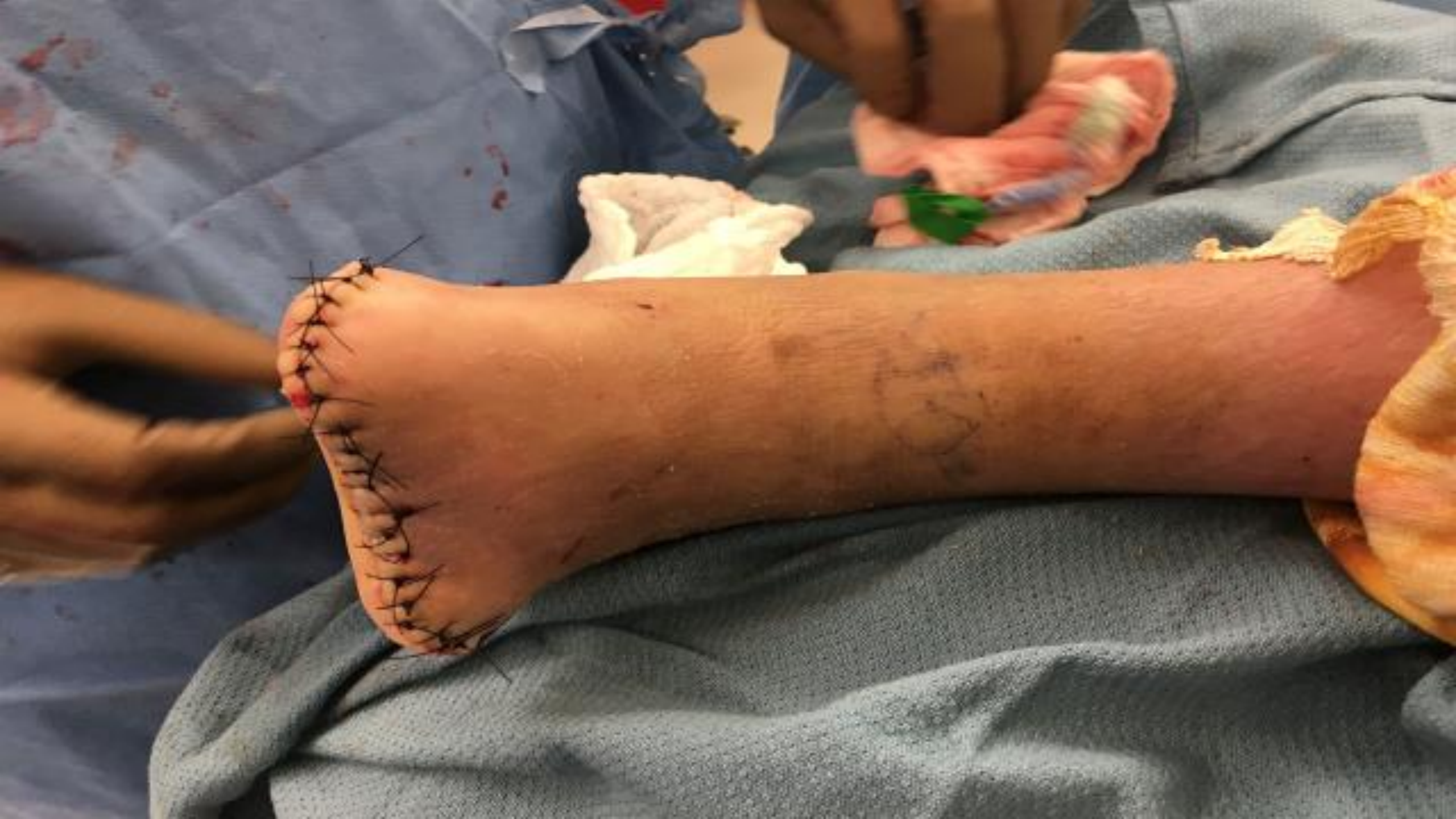Negative X-Ray

No PTB

-LR = **0.02**







Buy 10 Get 1 FREE!

