

DRIVING **CHANGE2023**  
THE URGENT CARE CONVENTION

# Proceed With Confidence: Musculoskeletal Maneuvers

Presented by:  
**Tiffany Proffitt, MD**  
**Ross Cohen, DO**

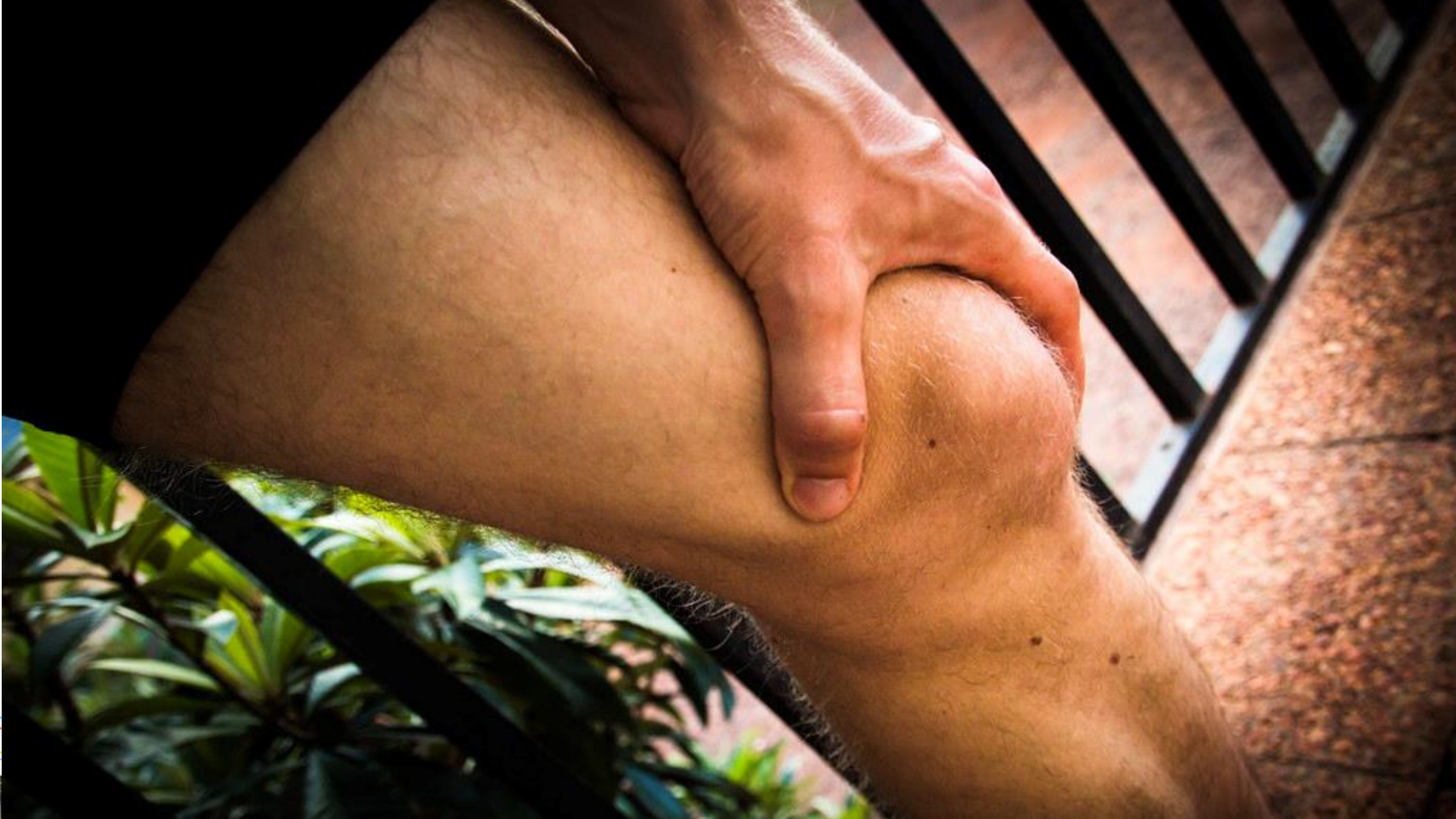Presented by UCA Affiliate

**HIPPO**  
EDUCATION

**UCA** URGENT CARE  
ASSOCIATION®

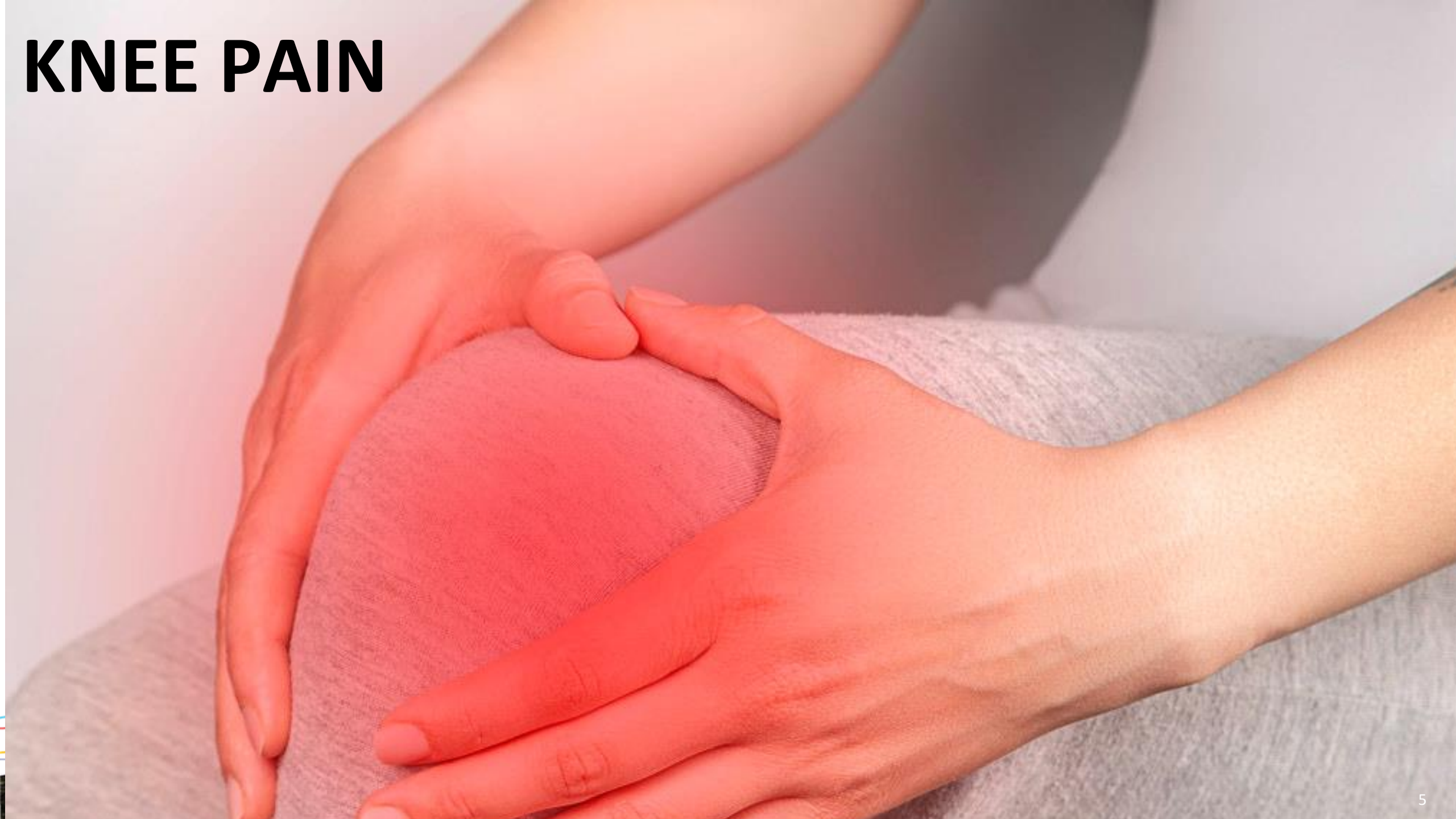

COLLEGE OF  
URGENT CARE  
MEDICINE



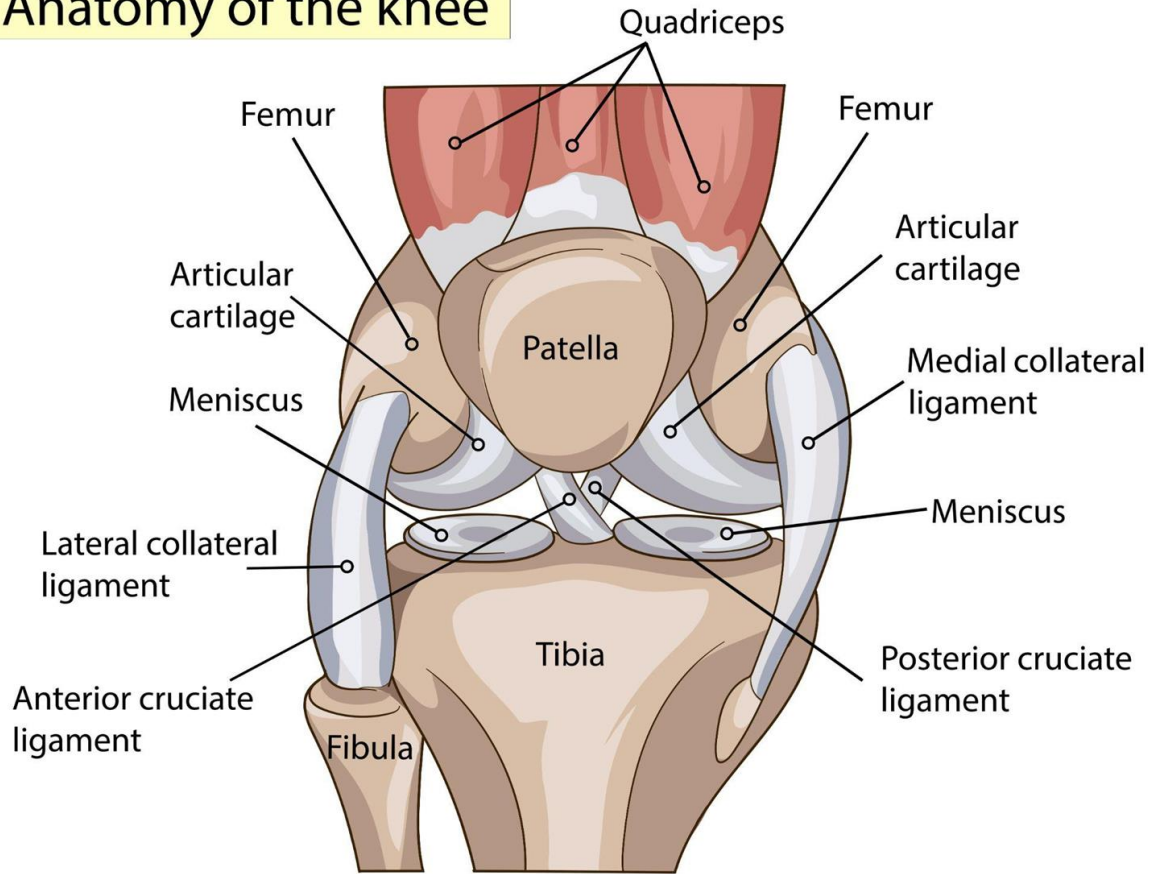


# KNEE PAIN

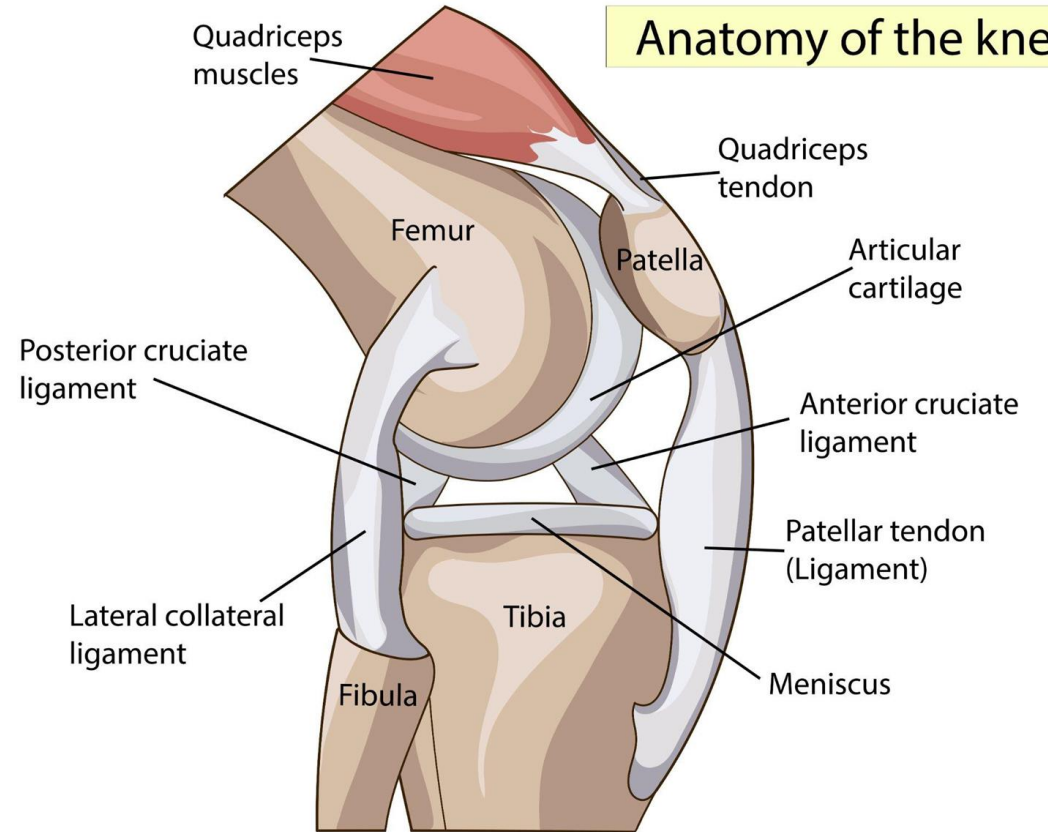


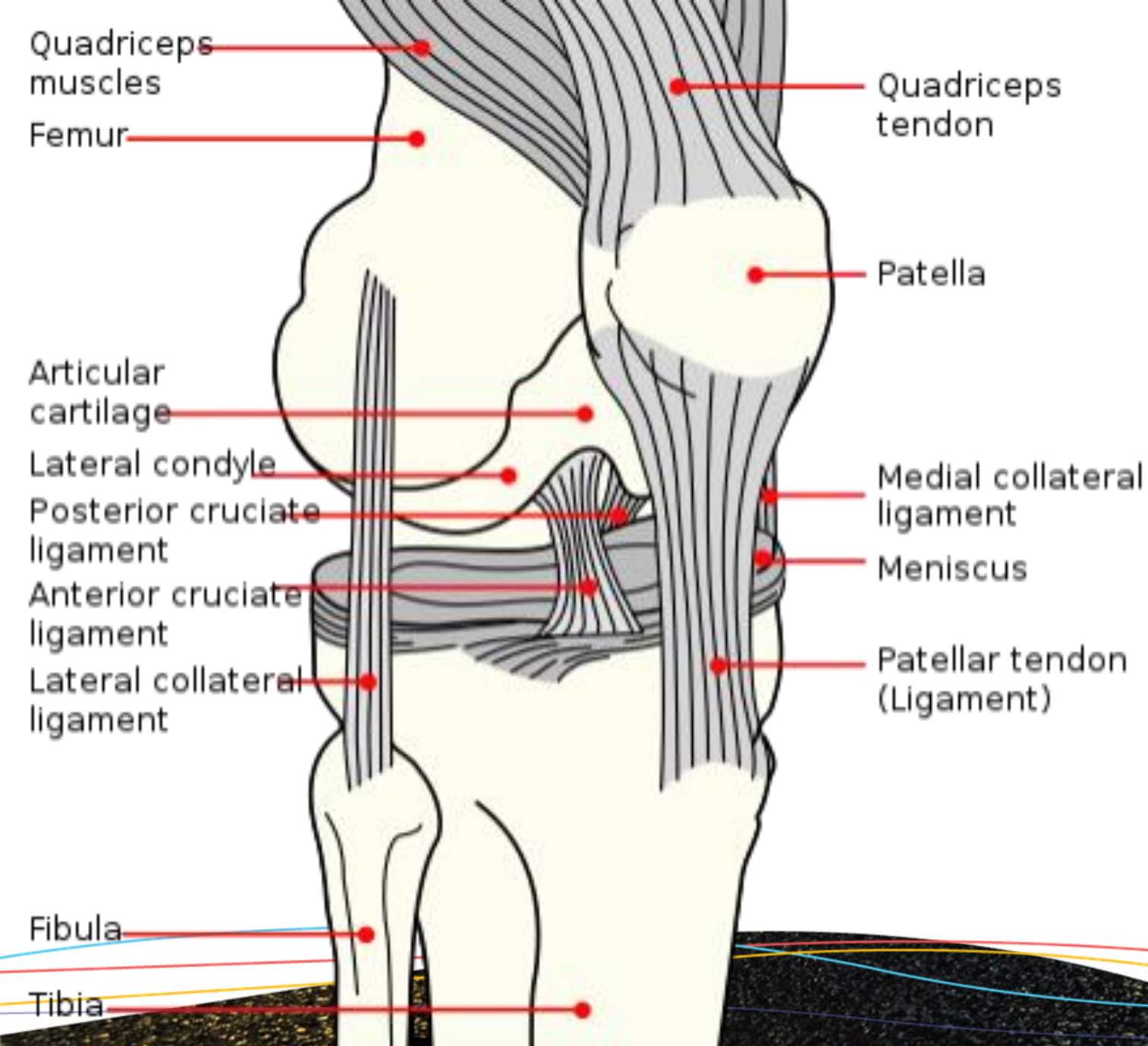
# Knee Anatomy

Anatomy of the knee



Anatomy of the knee





# Knee Anatomy

# Physical Exam



- Inspection
- Palpation
- Neurovascular
- ROM



- **Inspection**
  - Redness
  - Swelling
  - Deformity
  - Asymmetry
  - Lacerations




- **Palpation**
  - Deformity
  - Warmth
  - Tenderness
  - Effusion



# Ballotment Test

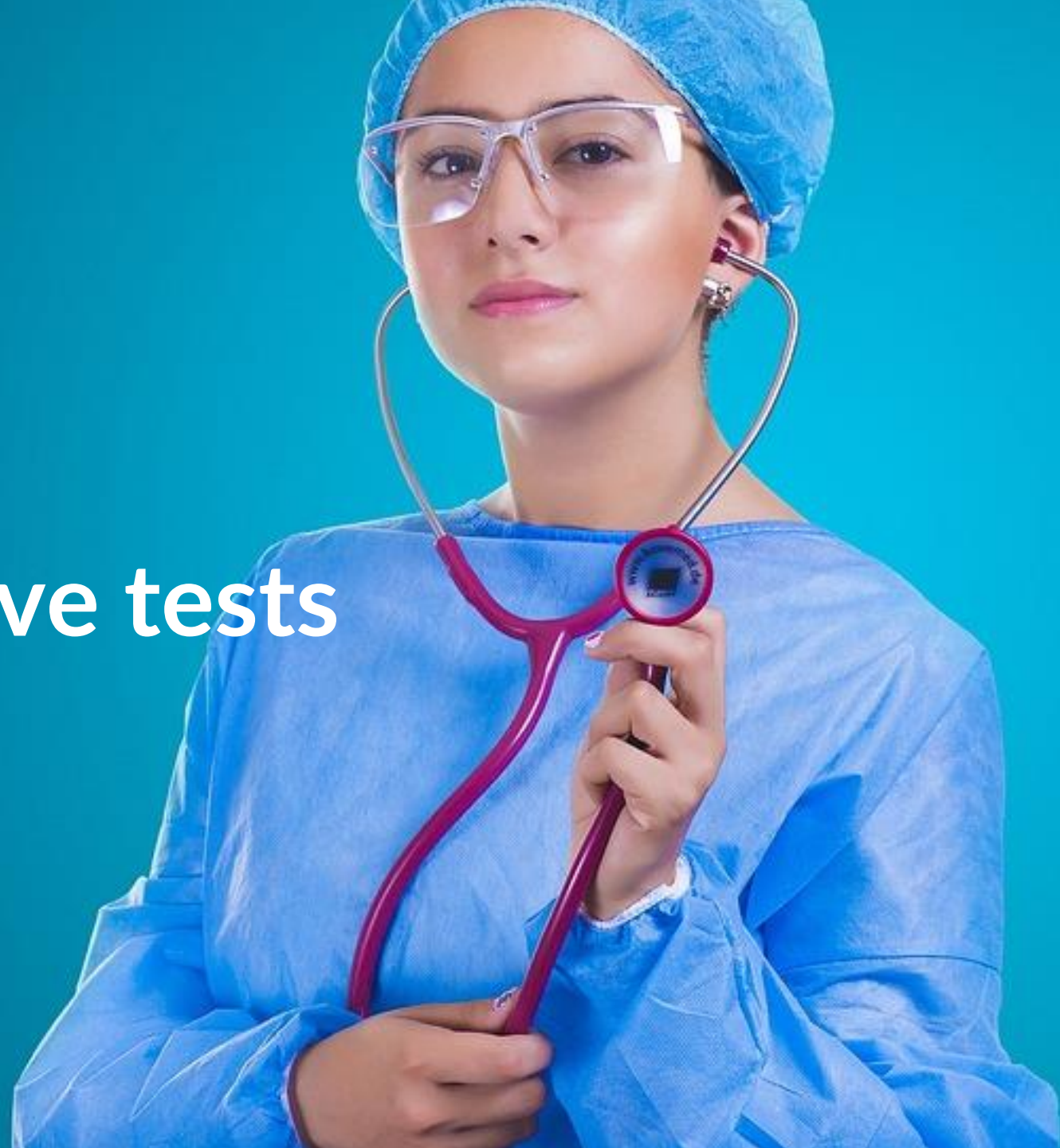DRIVING **CHANGE**2023  
THE URGENT CARE CONVENTION



- **Neurovascular**
  - **Strength**
  - **Sensation**
  - **Pulses**
  - **Reflexes**



- ROM
  - Passive
  - Active
  - Provocative tests



# Provocative Tests

## ACL/PCL

- Anterior and posterior drawer tests
- Lachman and drop Lachman

## Collateral Ligaments

- Valgus/Varus testing


## Meniscus

- McMurray Test
- Thessaly Test

# Anterior and Posterior Drawer

# Lachman and Drop Lachman

DRIVING **CHANGE**2023  
THE URGENT CARE CONVENTION



# Valgus and Varus

# McMurray

DRIVING **CHANGE**2023  
THE URGENT CARE CONVENTION

# Thessaly

DRIVING **CHANGE** 2023

# Take Home Points

- Practice
- Visualize Anatomy
- Compare to opposite side

# Patellar Dislocation

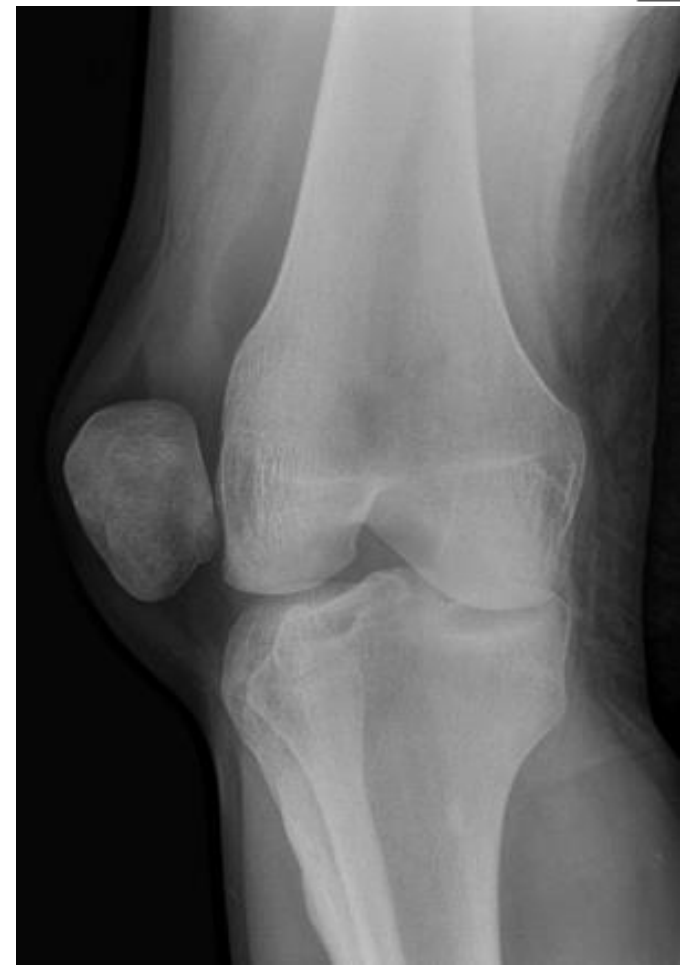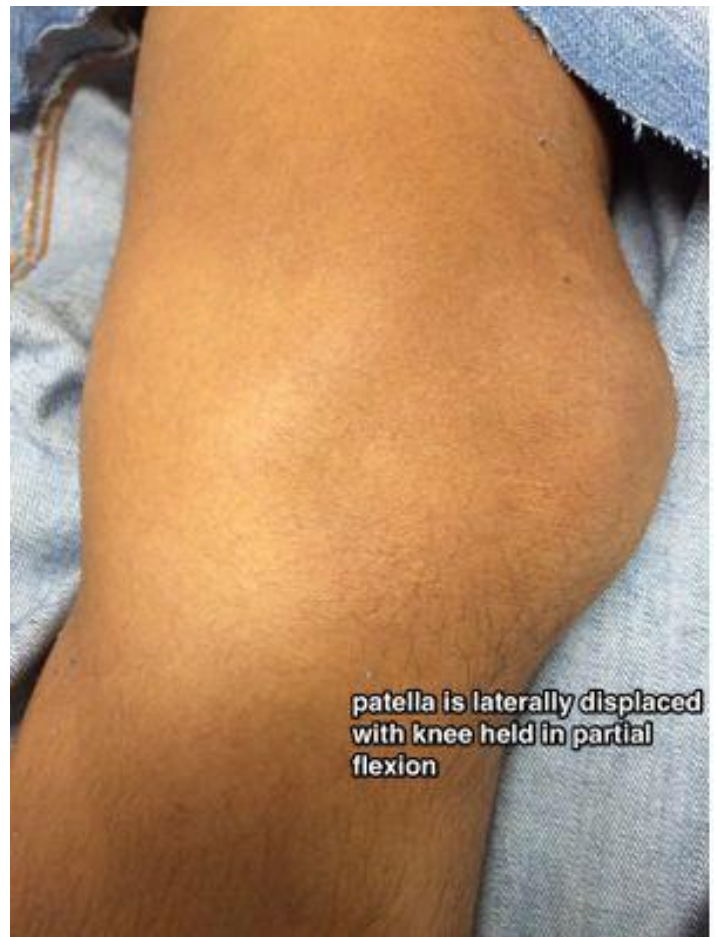
**Have YOU ever taken care  
of a patellar dislocation in  
the urgent care?**

**YES**

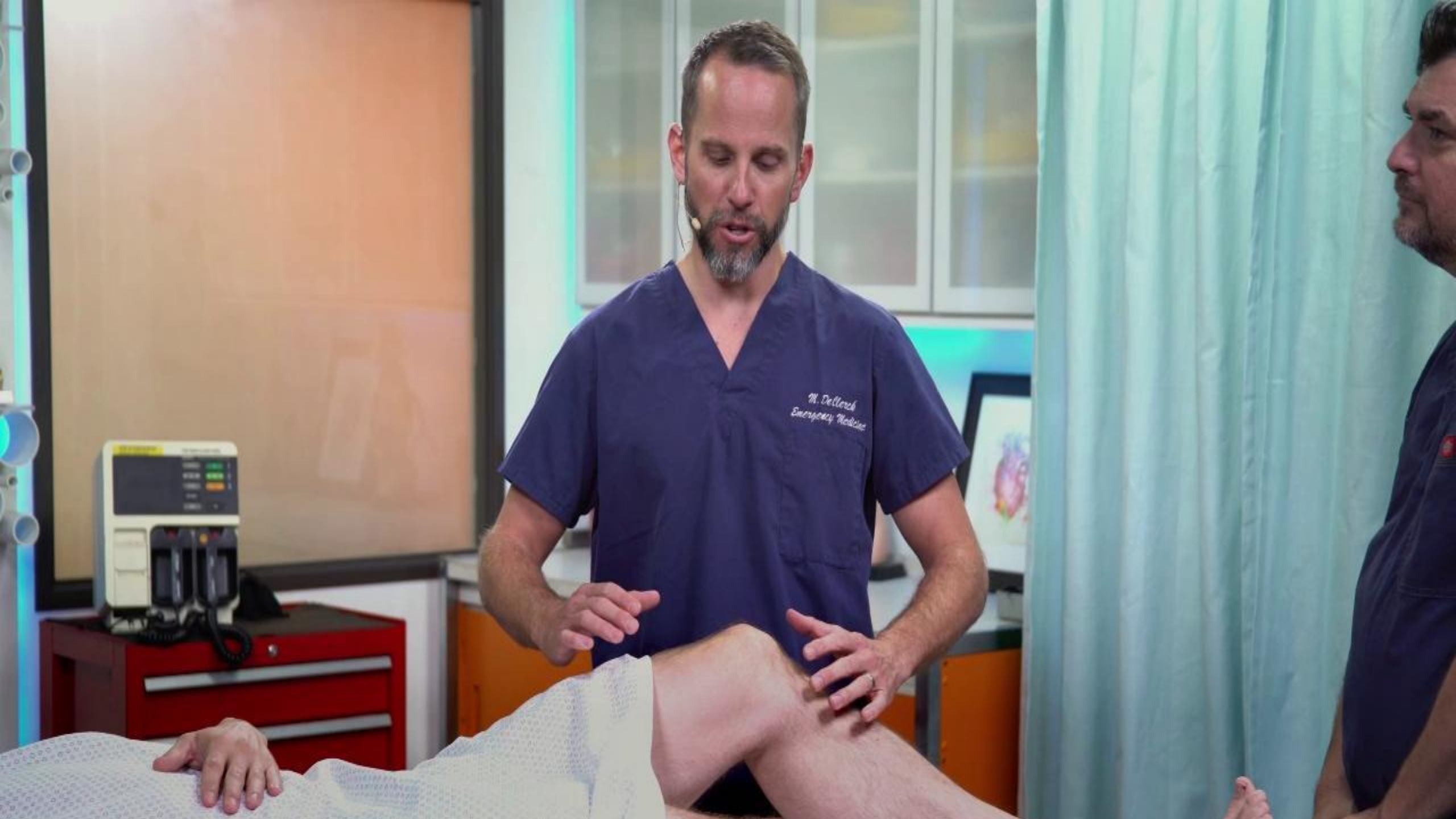**NO**



# Patellar Dislocation

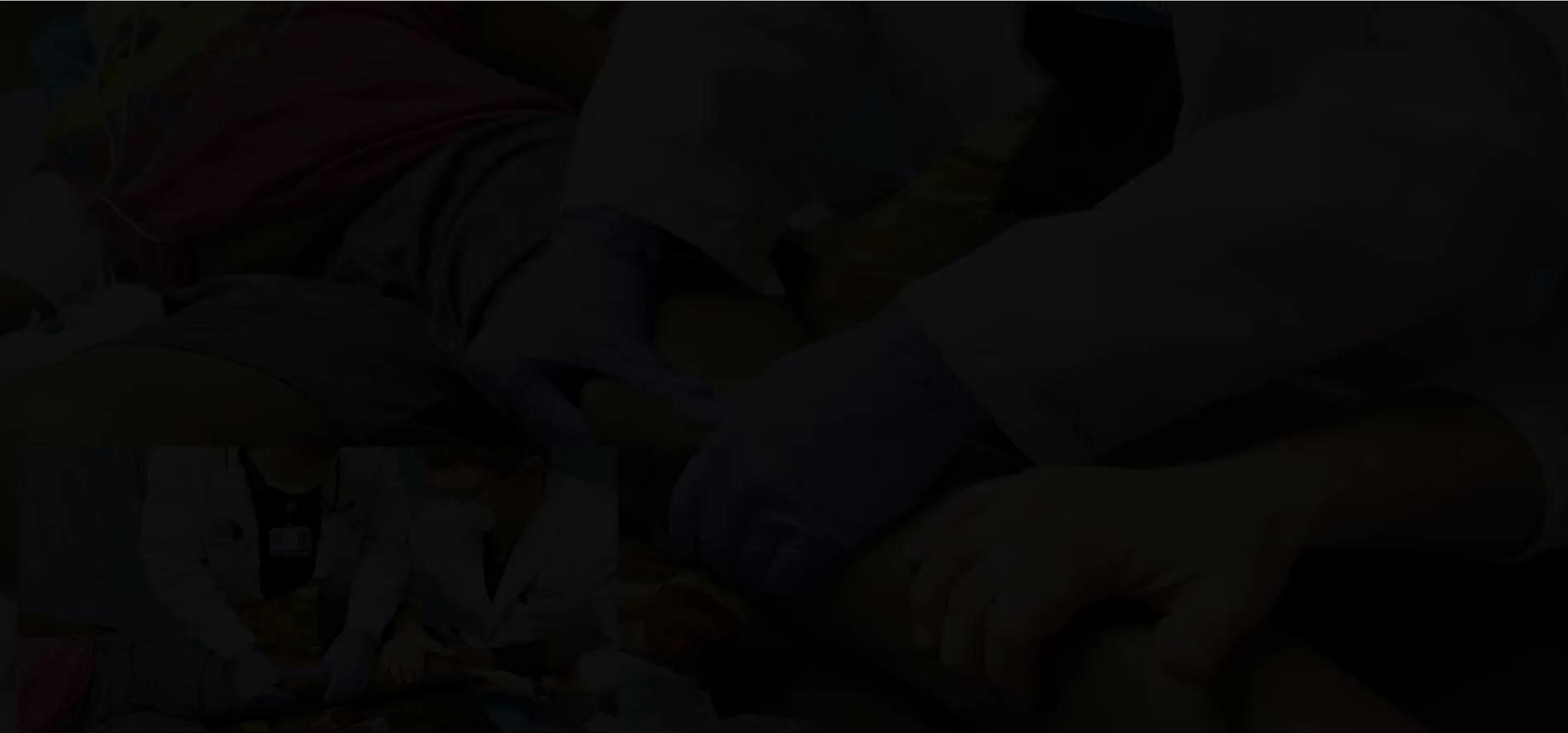

# Patellar Dislocation Procedure



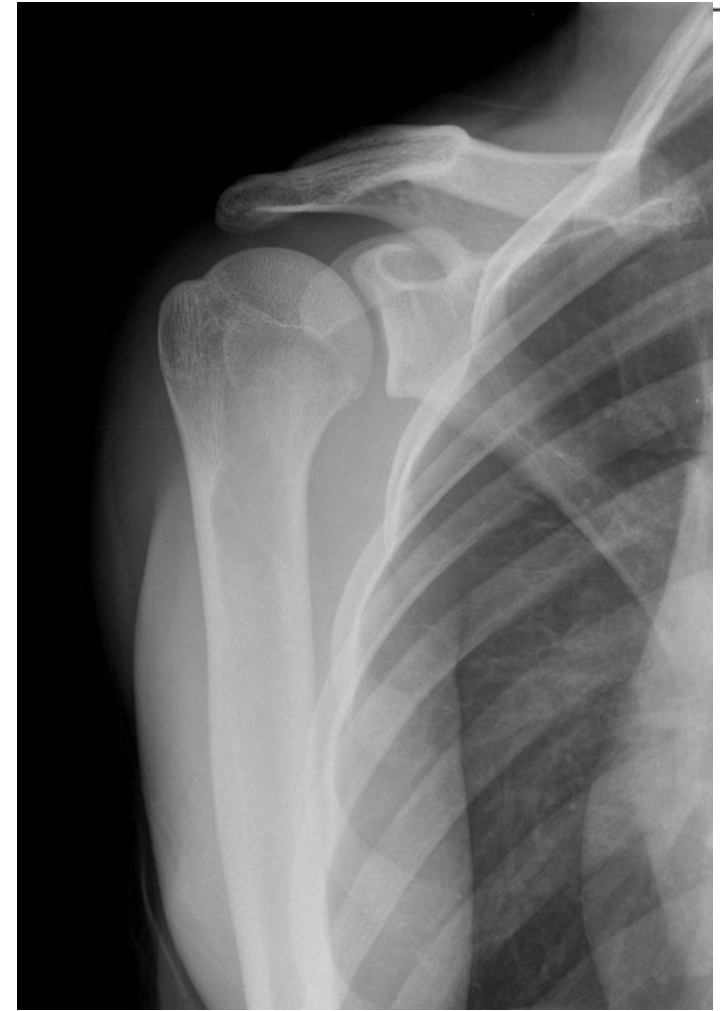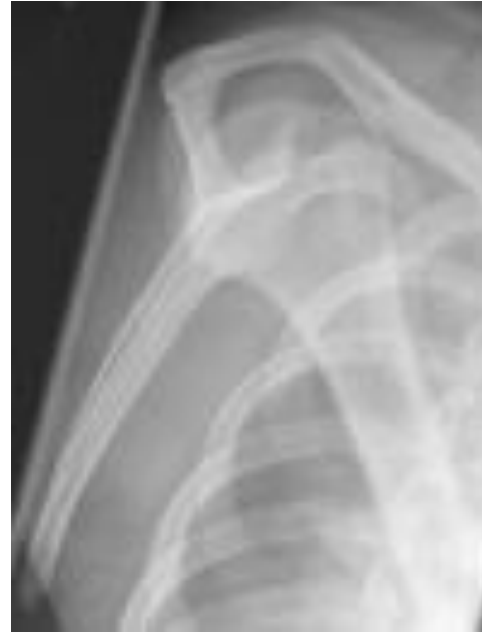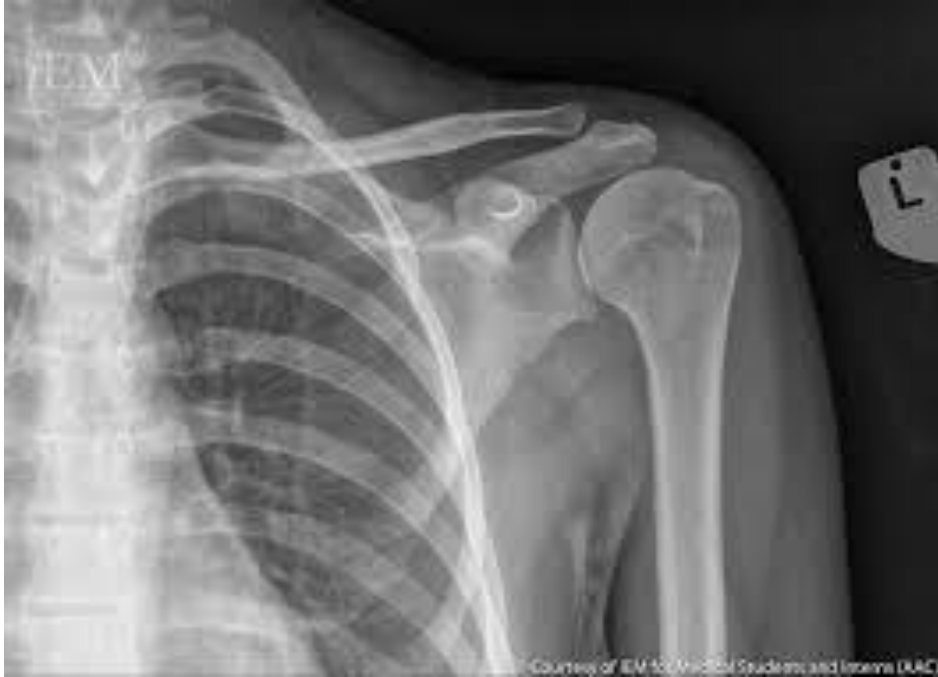# Patellar dislocation

DRIVING **CHANGE**2023  
THE URGENT CARE CONVENTION

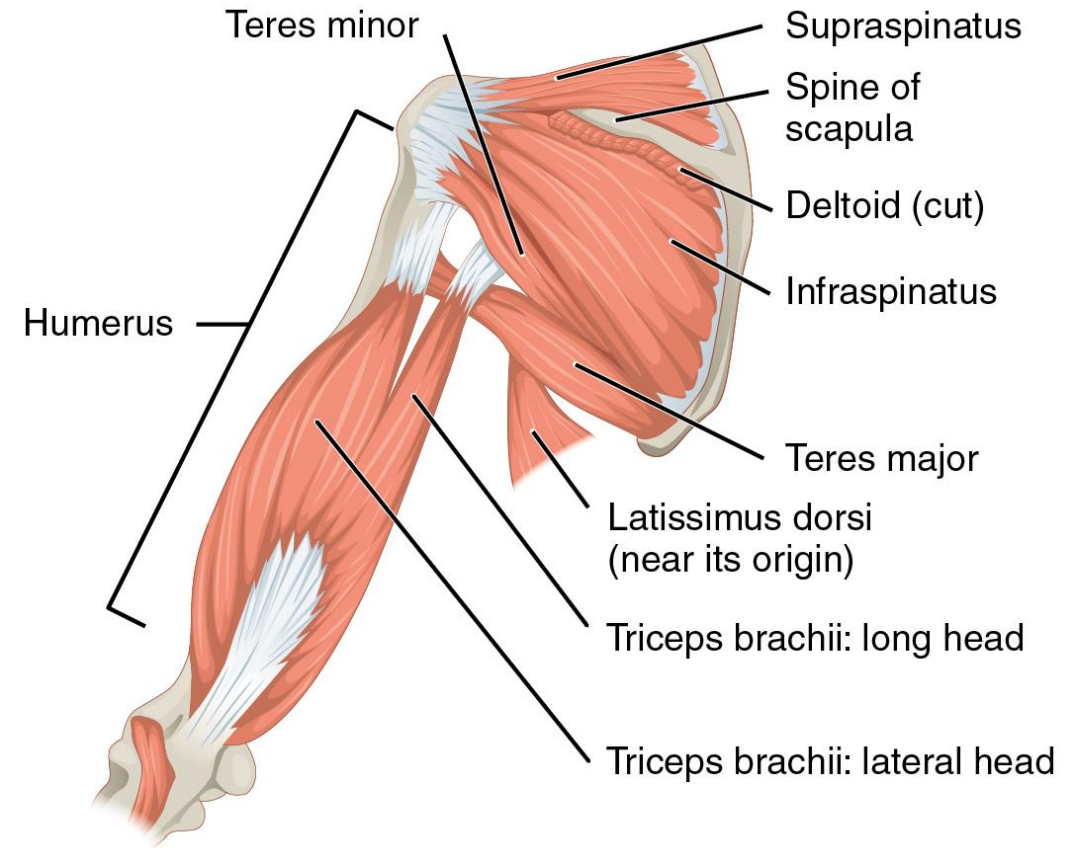
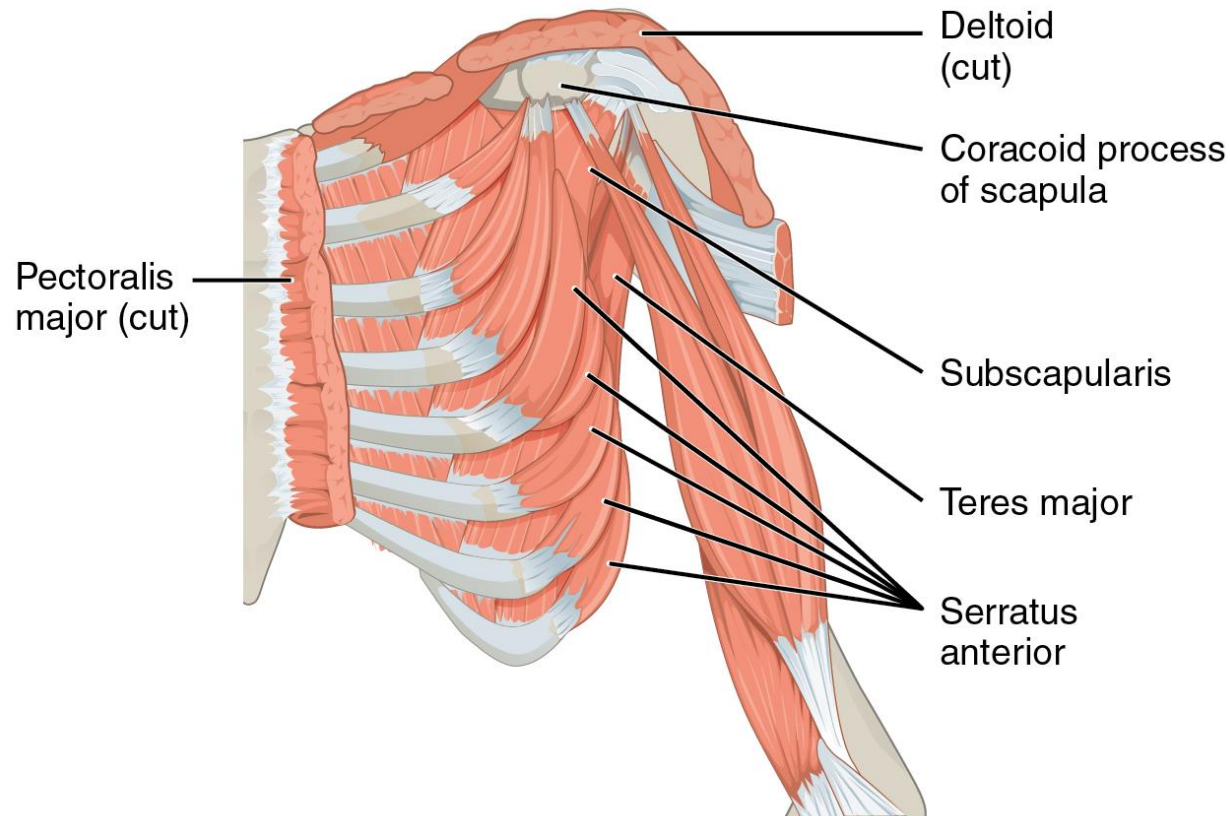


# The Shoulder

# Shoulder



# Shoulder Anatomy



# Physical Exam



- **Inspection**
- **Palpation**
- **Neurovascular**
- **ROM**



- **Inspection**
  - Redness
  - Swelling
  - Deformity
  - Asymmetry
  - Lacerations




- **Palpation**
  - Deformity
  - Warmth
  - Tenderness
  - Effusion



- **Neurovascular**
  - **Strength**
  - **Sensation**
  - **Pulses**
  - **Reflexes**



# Range of motion



- ROM
  - Passive
  - Active
  - Provocative tests



# Provocative Tests

## Impingement

- Neer - Impingement of rotator cuff/bursa
- Hawkins

## Supraspinatus weakness/Impingement

- Jobe's/Empty Can

## Infraspinatus and Subscapularis

- Internal/External Rotation

## Subscapularis

- Lift Off Test

## Labrum Injury

- O'Brien Test

## AC Joint Pathology

- Cross Arm ADDuction Test

# Impingement - Neer

# Impingement - Hawkins

# Supraspinatus weakness/Impingement Job's/empty can

# Infraspinatus and Subscapularis Internal/External Rotation

# Subscapularis - Lift Off Test

# Labrum Injury - O'brian test

# AC joint pathology -

# Cross Arm ADDuction Test

# Shoulder Dislocation

**Have YOU ever reduced a  
shoulder dislocation in the  
urgent care?**

**YES**

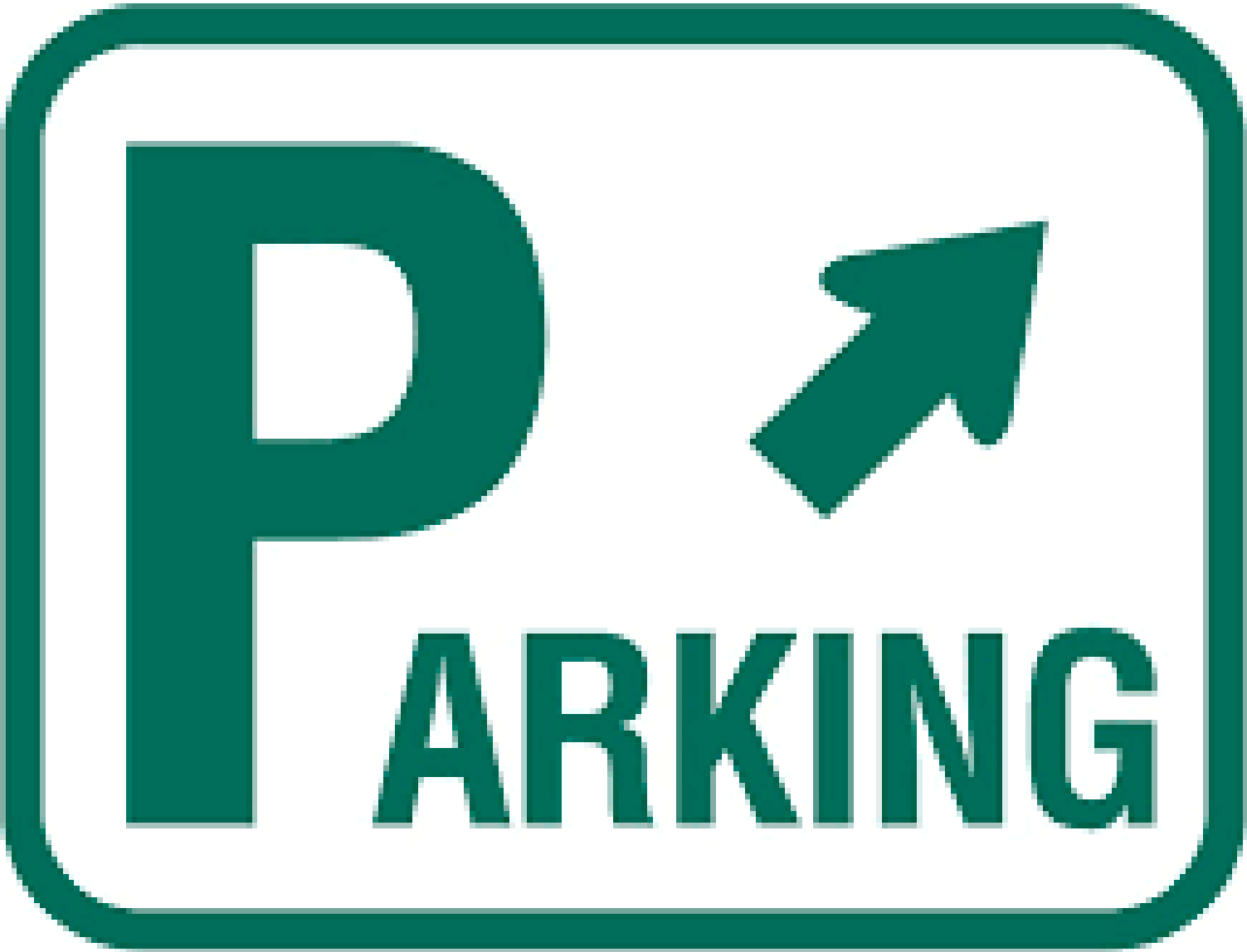**NO**



# Contraindications

- Associated Fracture of the humeral neck - through the third decade of life, < 1% chance of associated fracture
- Associated nerve injury/deficit (don't forget the Axillary nerve!)
- Suspected Major Vascular Injury
- Chronic Dislocation > 48 hours (low chance of success, refer to ER for evaluation if unsuccessful reduction)
- Exposed joint - open dislocation

# Park Maneuver



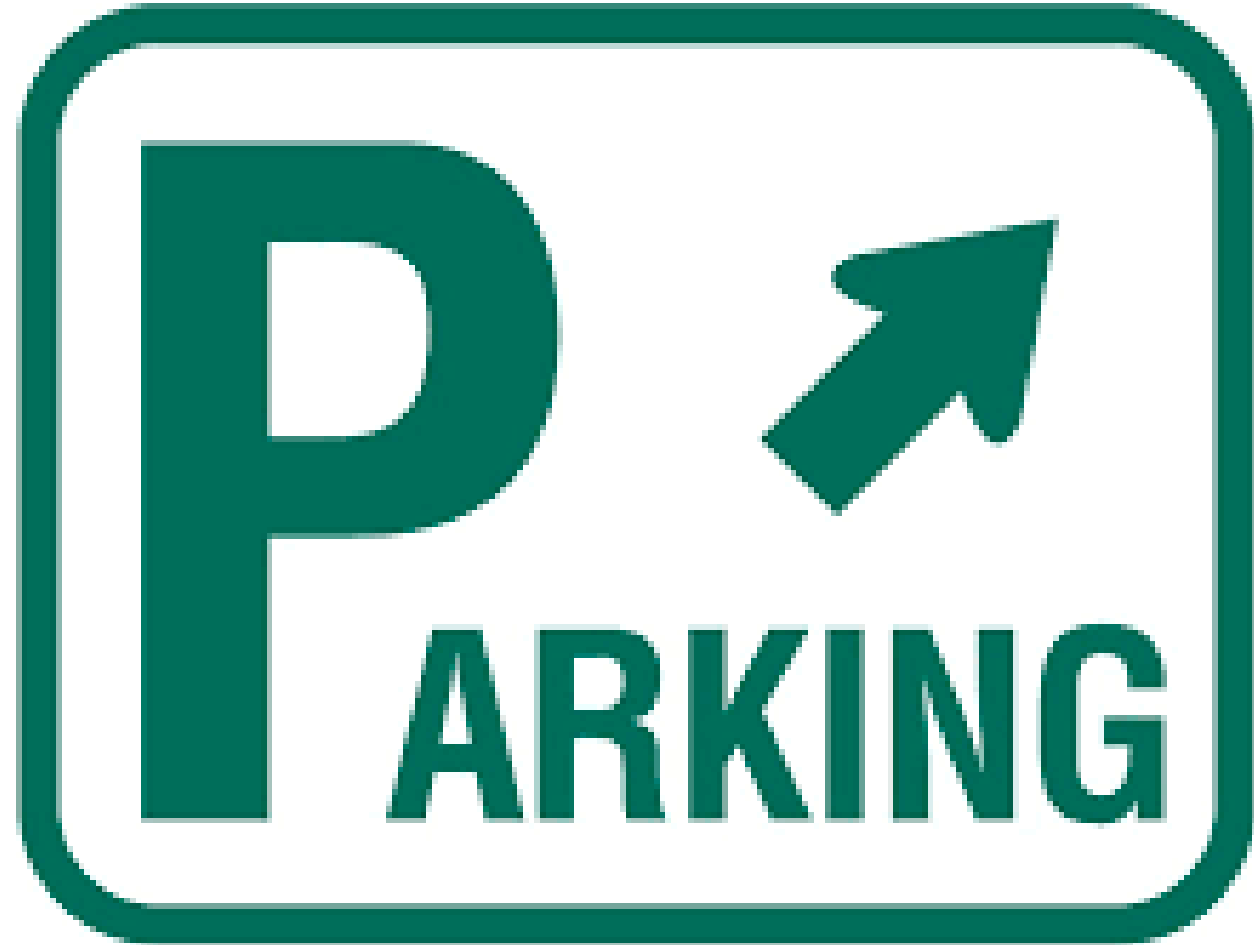HIPPO

# Park Maneuver



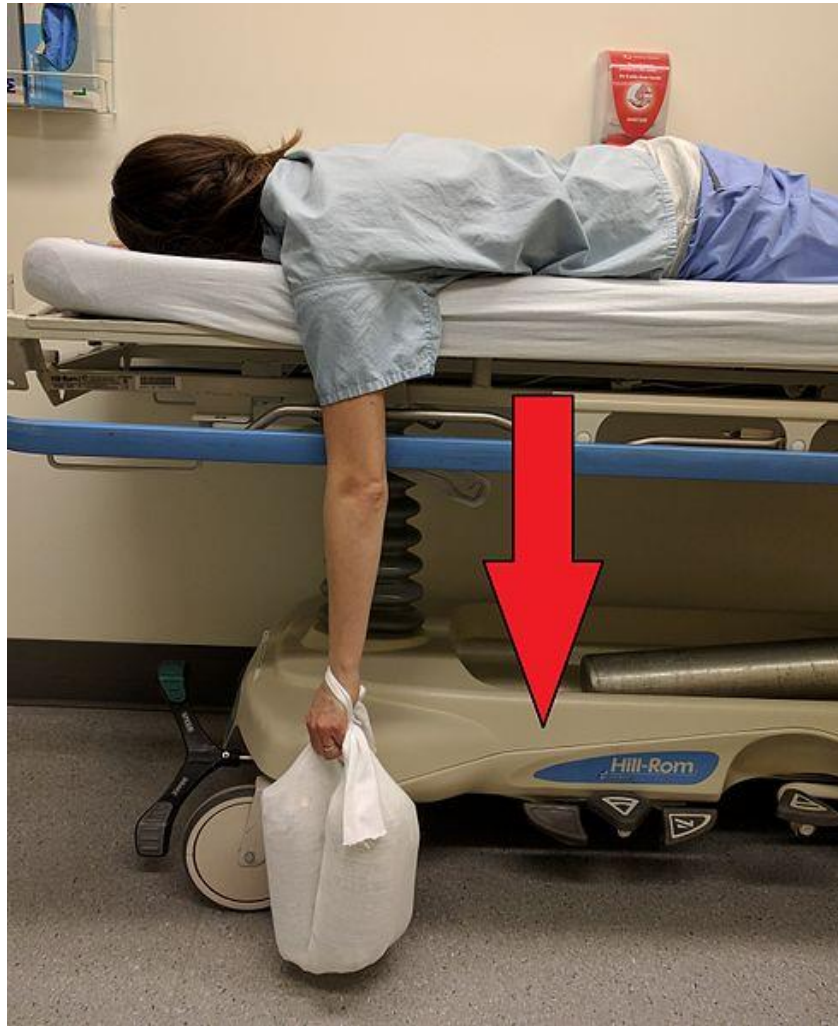# Park Maneuver

- Position Patient
- Fist in armpit
- Traction
- Adduct elbow
- Scapular manipulation



HIPPO

# Stimson Maneuver Shoulder Reduction Method



**Indications: anterior shoulder dislocation**

## Technique

- patient lays prone on exam table with affected arm hanging off the table
- perform pre-procedure neuro exam
- intra-articular analgesia
- with patient prone and secured hang weight from wrist
  - weight can be added gradually
- after about 30 minutes the muscle spasm shoulder relax enough to allow the humeral head to reduce
- scapular massage (with weights in place) may be beneficial if reduction does not occur

# Post-Reduction Take Home

## Points

- Thorough neurovascular exam post-reduction
- Sling
- Orthopedic surgery follow-up
- Reduction manages most of the pain
- Physical Therapy



## How You Can Drive Change:

- Perform a neurovascular exam BEFORE and AFTER reduction, be vigilant for neurovascular injury.
- You may need to use multiple techniques and that's ok.

DRIVING **CHANGE2023**

Questions?

# Session Evaluation

- Your feedback is valuable, take a moment to complete the survey for this session.
- To claim CME, you must complete a separate survey available after the convention.

\* How likely are you to recommend this **content** to a colleague?

Not likely at all                      Neutral                      Extremely likely

0   1   2   3   4   5   6   7   8   9   10

What did you find most valuable about this **content**?

What would have made this **content** better?