

DRIVING **CHANGE 2023**
THE URGENT CARE CONVENTION

Going From Good To Great


UCA URGENT CARE
ASSOCIATION®



Presented by UCA Affiliate


HIPPO
EDUCATION











D

E

J

K

N

M

LETTERS

F

G

I

L

H

RUBE GOLDBERGER





Temporarily

CLOSED

due to COVID-19 pandemic

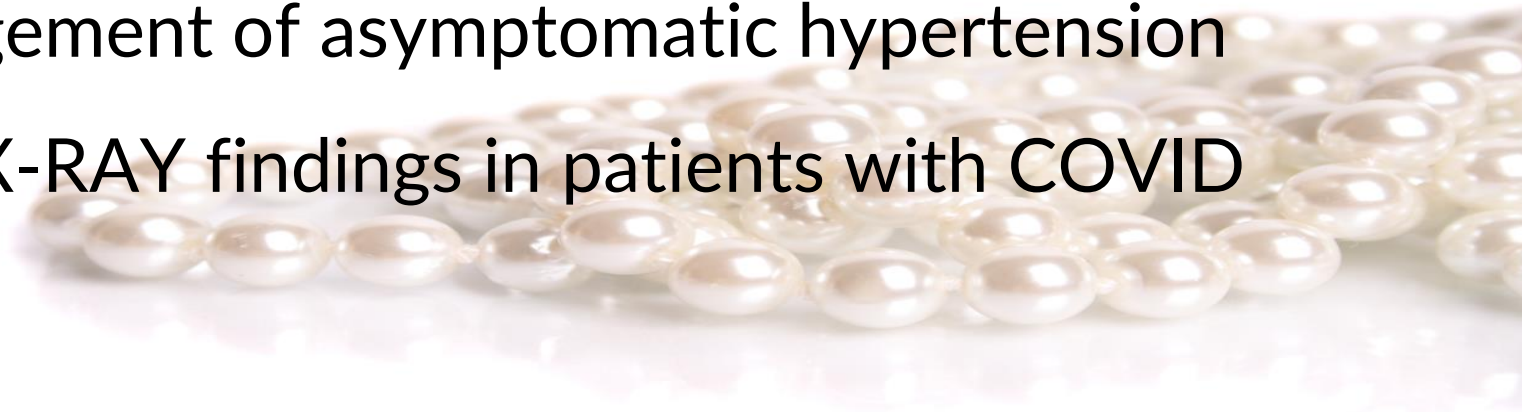
Urgent Care








- How to get a non-invasive pediatric urine sample and abscess drainage tips in kids.
- Partial Fingertip Amputations
- Management of asymptomatic hypertension
- Chest X-RAY findings in patients with COVID

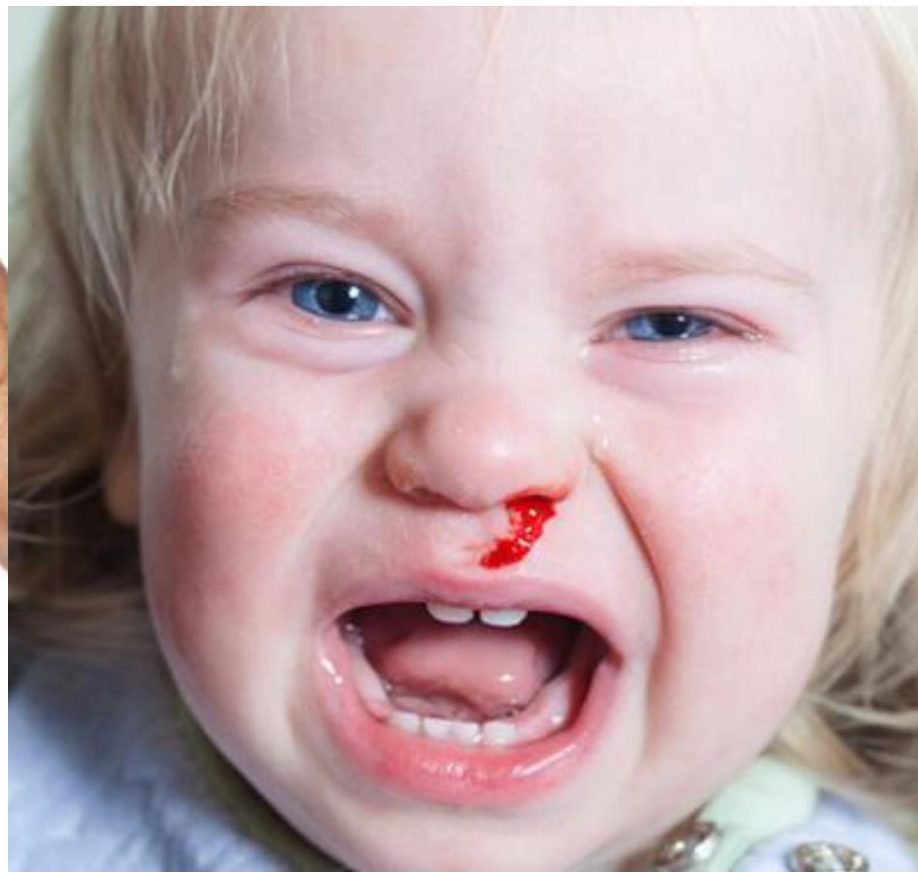
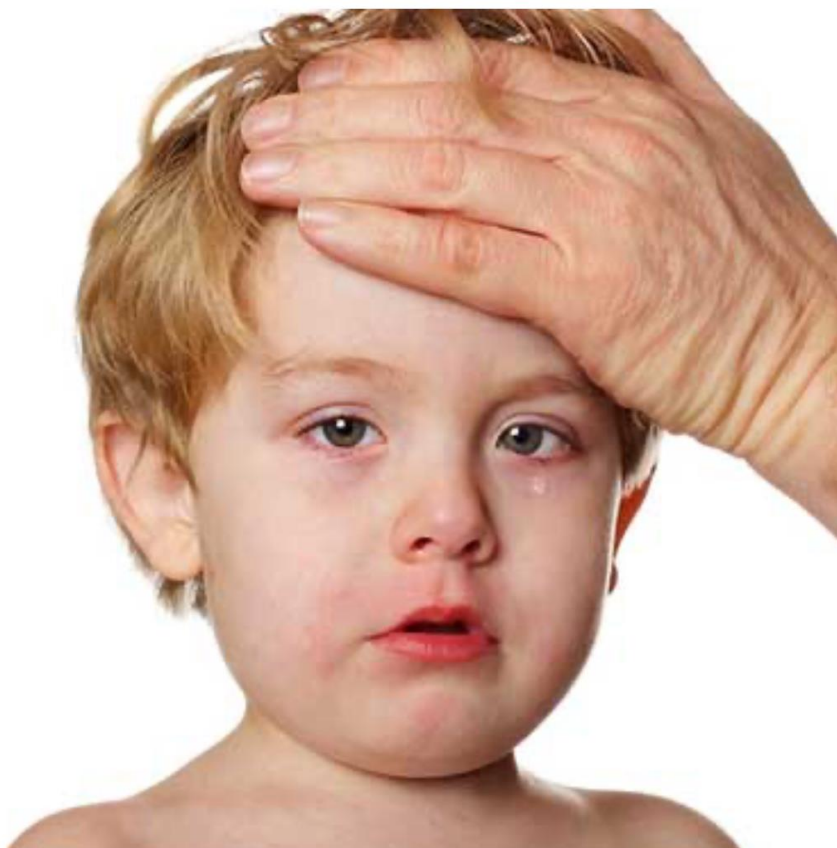
Urgent Care



Pediatric Tips and Tricks






UC

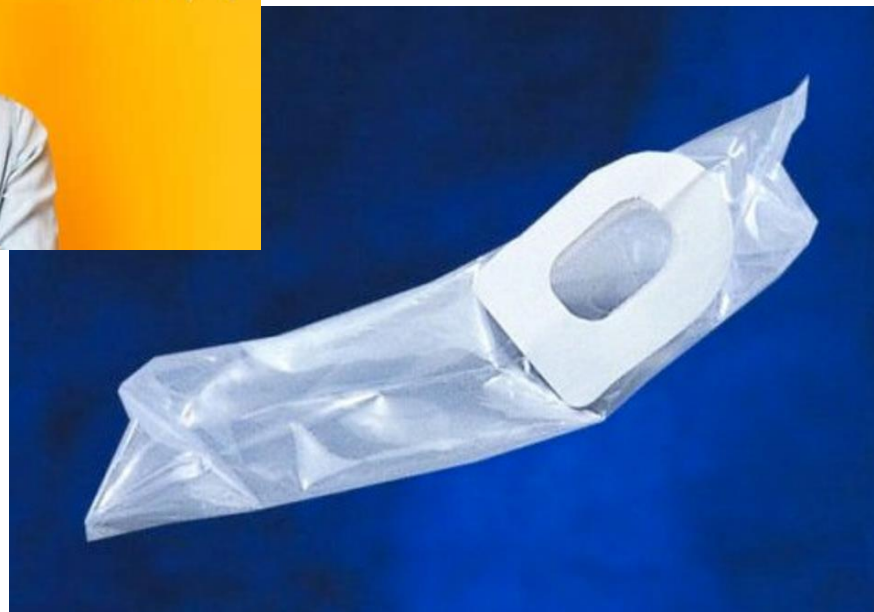vs.

ER



Pediatric Tips and Tricks



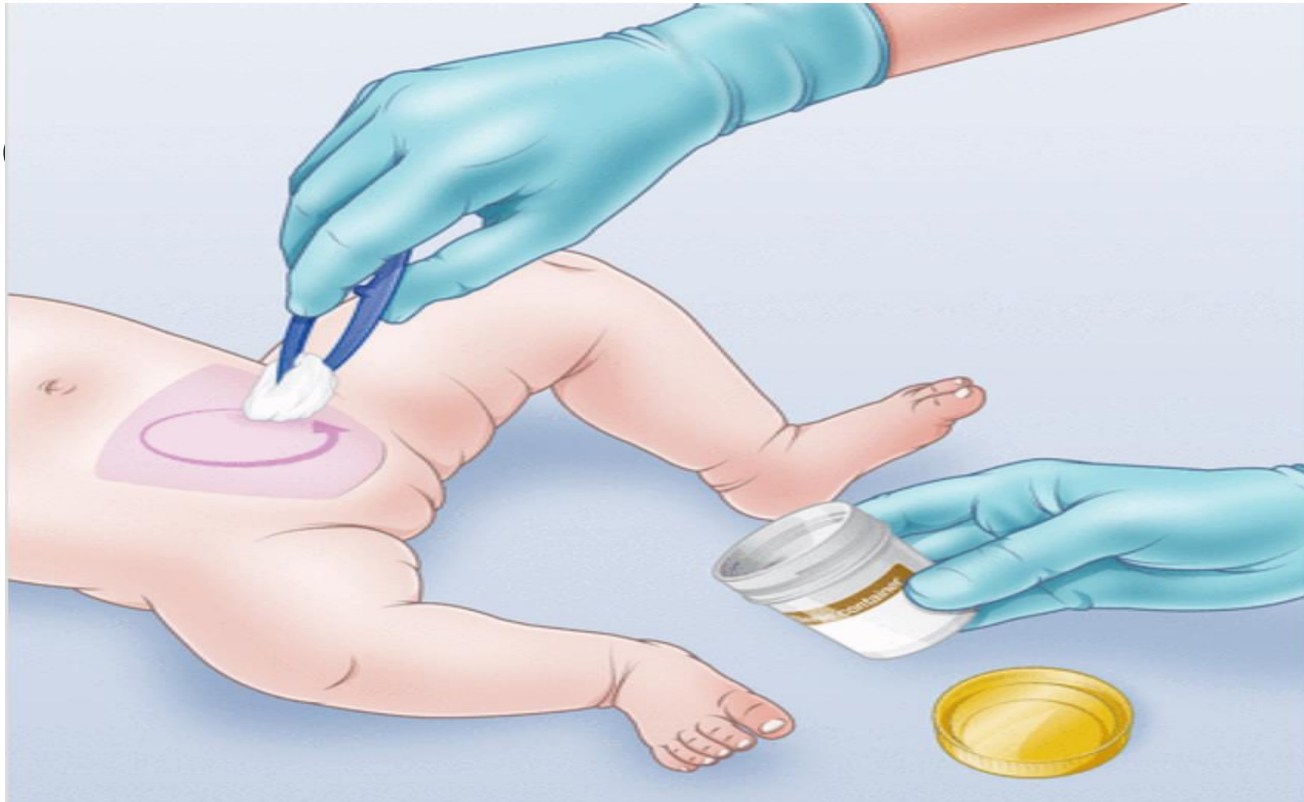

A photograph of a man in a dark t-shirt lifting a young child into the air. The child is wearing a blue and white patterned outfit and a red headband with a bow. They are outdoors with palm trees and a cloudy sky in the background. A white banner with black text is at the bottom.

Bladder Stimulation Technique

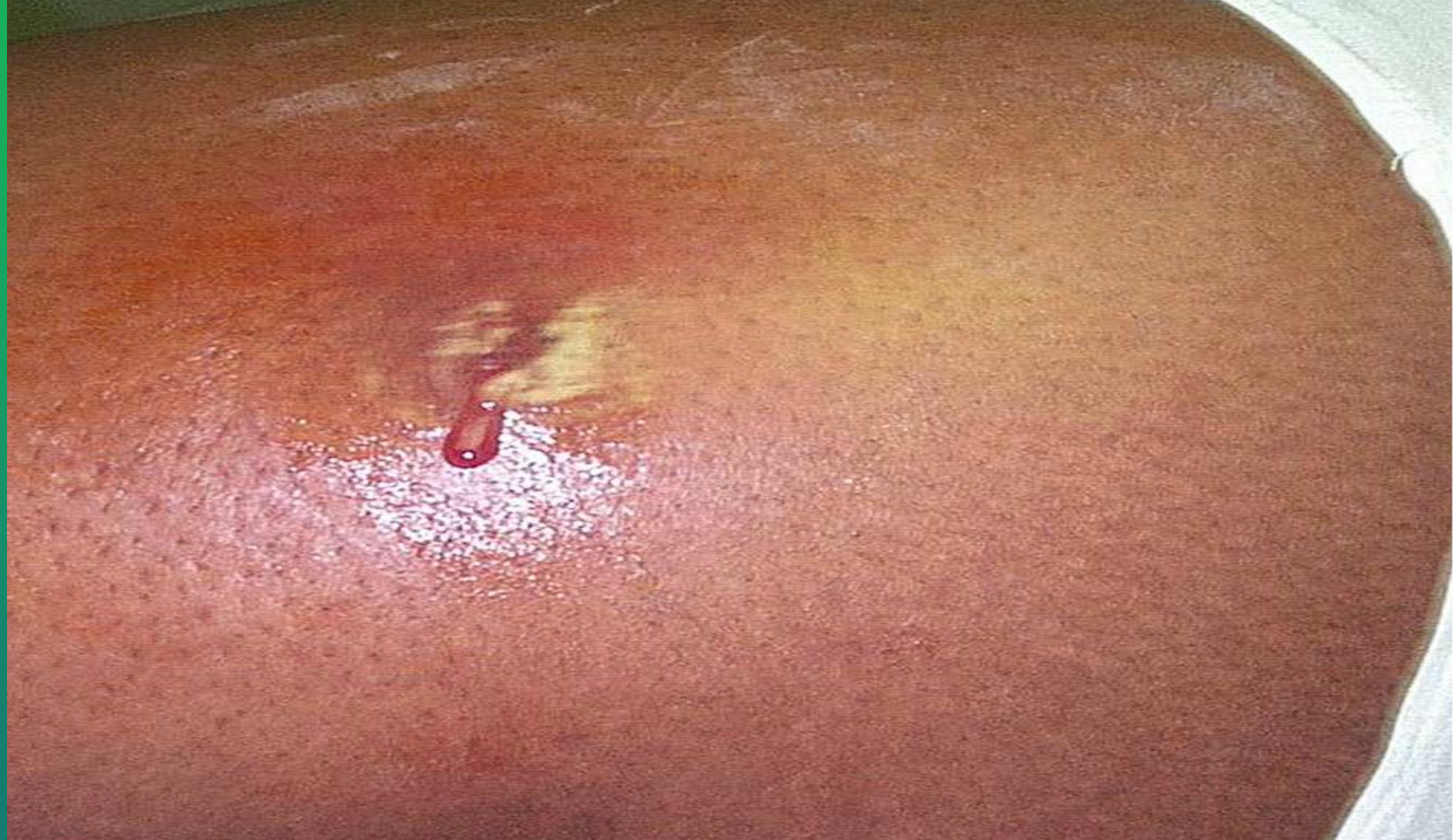Quick-Wee Method

Replac



Pediatric Tips and Tricks

Abscess Drainage



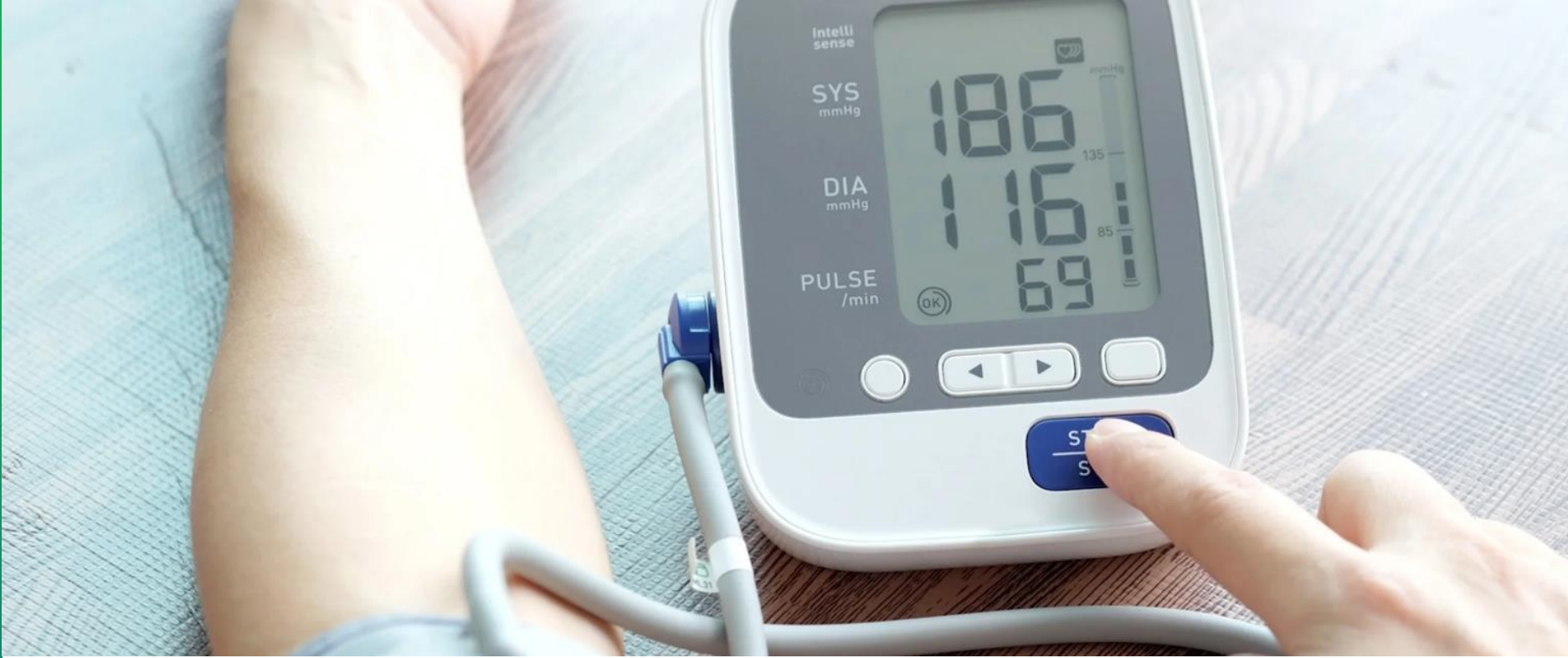

**25% Spontaneous
drainage**

The image shows two traditional wooden buckets. The bucket on the left is lying on its side, revealing its octagonal wooden base. The bucket on the right is upright and features a black metal handle. Both buckets are made of light-colored wood and have black metal bands around their bodies. The background is a dark, patterned fabric. A solid green vertical bar is on the far left edge of the image.

ER

UC



Asymptomatic Elevated Blood Pressure








A close-up photograph of a red train door. The door is the central focus, with a blurred grey and blue area to the left. At the bottom of the frame, a yellow safety strip is painted on the ground, featuring the text "MIND THE GAP" in bold, yellow, sans-serif capital letters. The strip is bordered by a thin white line above and a thin red line below. The overall scene is brightly lit, suggesting an outdoor or well-lit indoor station environment.

MIND THE GAP

Globally, only 1 of every 7 people has their hypertension under control


Unaware that they have high BP



Aware but untreated



Treated but not controlled



UNCONTROLLED BLOOD PRESSURE

CONTROLLED

Urgency

vs

Emergency

Traditionally used for SBP
>180/120 mmHg

Does **not** portend an acute
risk

ACEP: “**asymptomatic
markedly elevated blood
pressure**” (BP \geq 160/110
mmHg)

Target organ injury in
the setting of
markedly elevated BP

Urgency

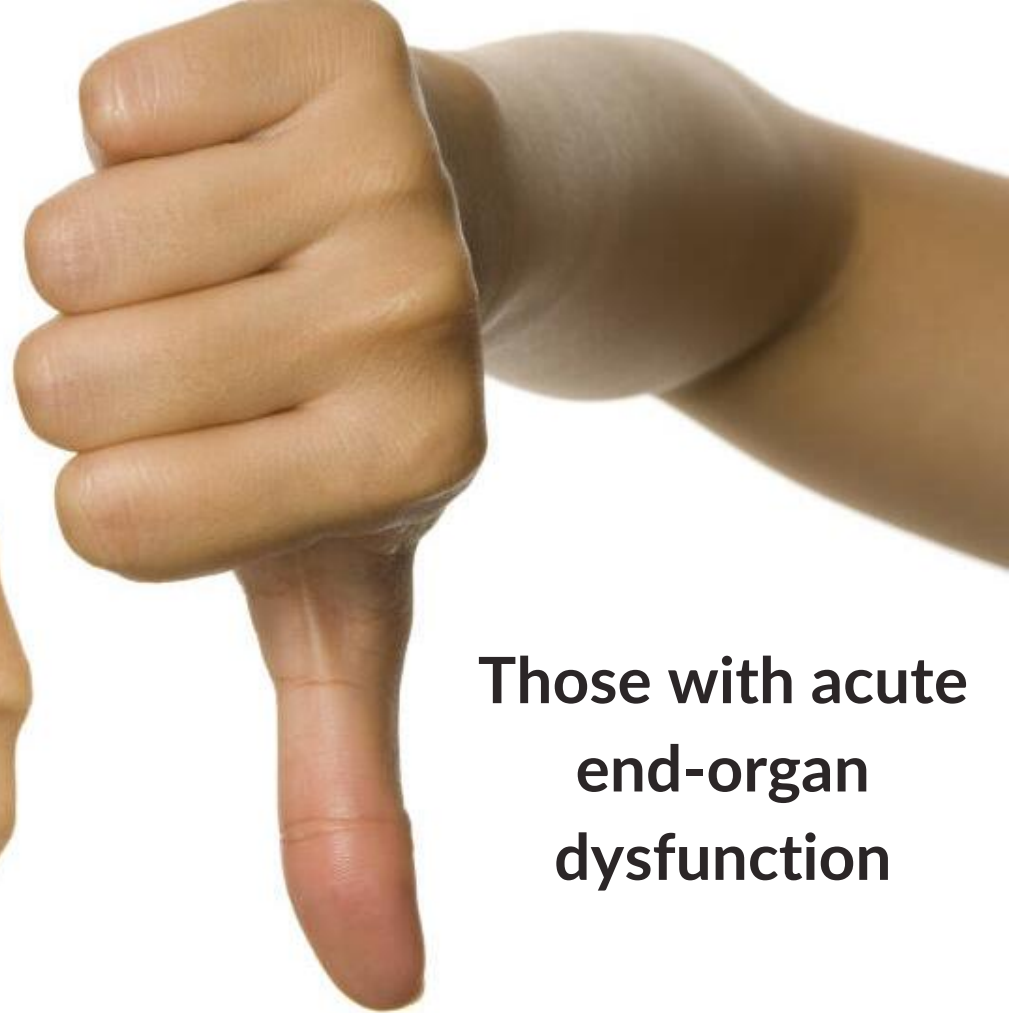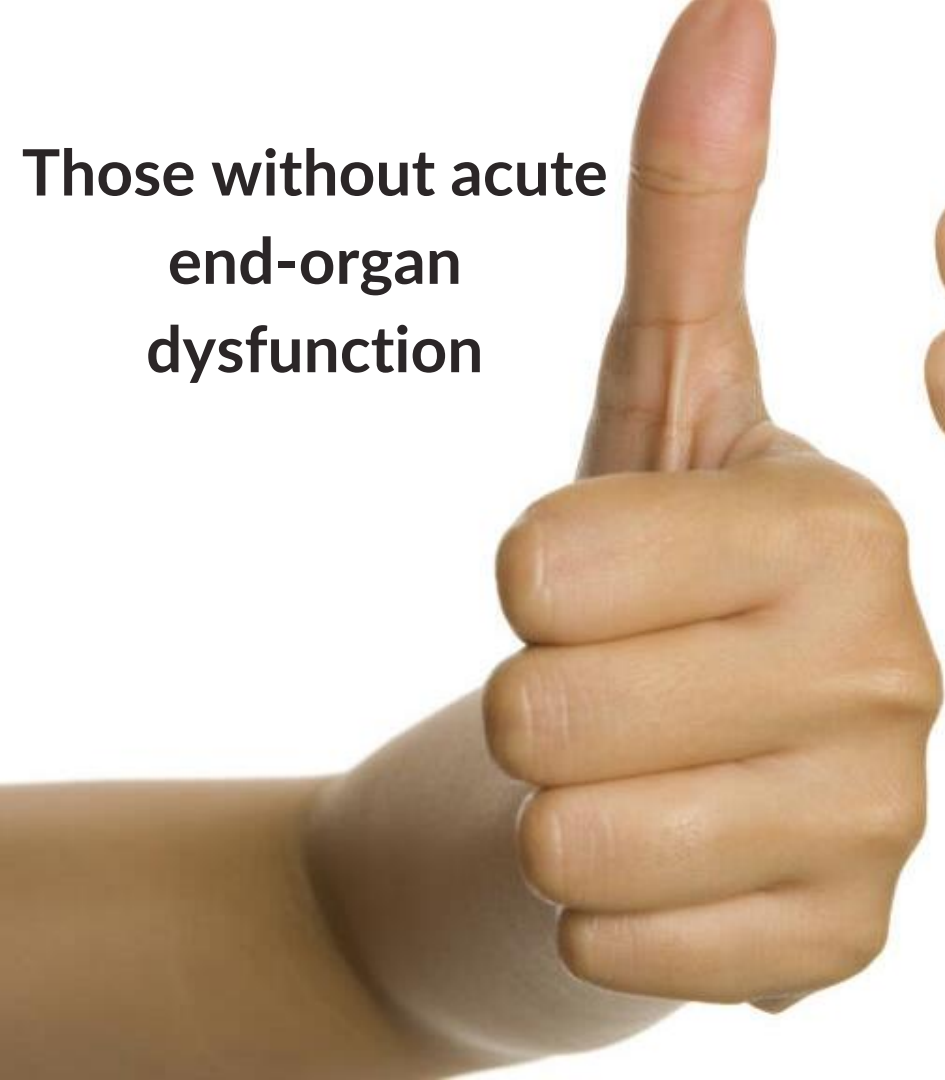vs

Emergency

The “urgency” in hypertensive urgency is the urgency for a rapid, thorough history and exam as well as counseling to patient, rather than acutely lowering the blood pressure.


Target organ injury in the setting of markedly elevated BP

**Those without acute
end-organ
dysfunction**




**Those with acute
end-organ
dysfunction**

BP \geq 160/110 mmHg





Two white speech bubbles with black outlines are mounted on thin grey sticks. The background is a gradient of yellow and orange. The bubble on the left contains the text 'What is driving their elevated BP?'. The bubble on the right contains the text 'Identifying red flags for acute end-organ damage'.

What is driving
their elevated BP?

Identifying red flags
for acute end-organ
damage



Chest pain

Palpitations

Respiratory distress

Severe headache

Vision disturbances

Weakness

Numbness/tingling

Oliguria

Abnormal physical exam

??? ← No

Yes → ED



Acute end-organ
dysfunction?

BP \geq 160/110 mmHg

Guideline	Recommendation
2013 ACEP	<ul style="list-style-type: none">● Routine ED medical intervention is not required● In select patient populations...may treat markedly elevated blood pressure and/or initiate therapy for long-term control● Refer for outpatient follow-up
2013 ESH/ESC Arterial Hypertension	<ul style="list-style-type: none">● Reinstatement or intensification of existing antihypertensive regimen
2017 ACC/AHA	No indication for immediate reduction of blood pressure in emergency department or hospitalization

No ED ← No

Yes → ED



Acute end-organ
dysfunction?

BP \geq 160/110 mmHg

NORTHGANG



“When it comes to asymptomatic hypertension, one of the teachings has been based on a twist of an old adage—**don't just do something, stand there.**”

Guideline	Recommendation
2013 ACEP	<ul style="list-style-type: none">● Routine ED medical intervention is not required● In select patient populations...may treat markedly elevated blood pressure and/or initiate therapy for long-term control● Refer for outpatient follow-up
2013 ESH/ESC Arterial Hypertension	<ul style="list-style-type: none">● Reinstate or intensify existing antihypertensive regimen
2017 ACC/AHA	No indication for immediate reduction of blood pressure in emergency department or hospitalization



↓SBP 10-20 mmHg
following 30 min of
rest



Home > Hypertension > Vol. 71, No. 6 > 2017 ACC/AHA/AAPA/ABC/ACPM/AGS/APhA/ASH/ASPC/NMA/PCNA Guideline f...

 FREE ACCESS

REVIEW ARTICLE

 PDF/EPUB

 Tools  Share

Jump to

Table of Contents

Preamble

2017

ACC/AHA/AAPA/ABC/ACPM/AGS/APhA/ASH/ASP C/NMA/PCNA Guideline for the Prevention, Detection, Evaluation, and Management of High Blood Pressure in Adults: A Report of the American College of Cardiology/American Heart Association Task Force on Clinical Practice Guidelines

Paul K. Whelton, Robert M. Carey, Wilbert S. Aronow, Donald E. Casey Jr,
Karen J. Collins, Cheryl Dennison Himmelfarb, Sondra M. DePalma,

 Details

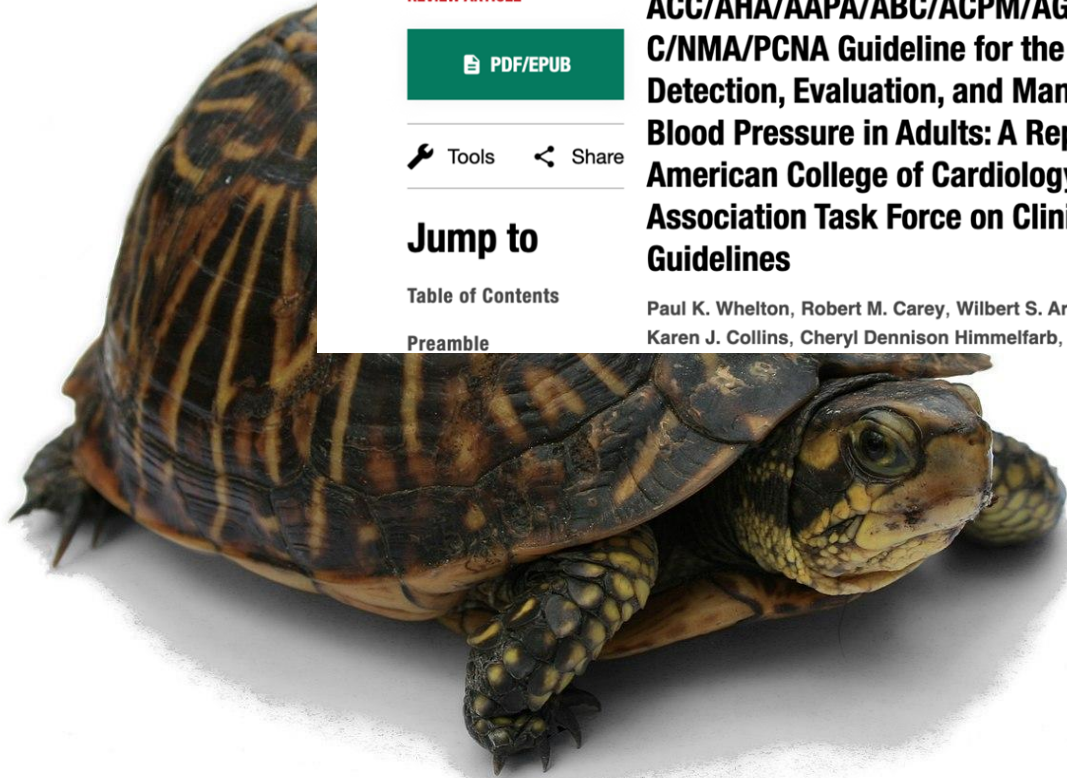
 Related

 References

 Figures



June 2018
Vol 71, Issue 6





Home > Hypertension > Vol. 71, No. 6 > 2017 ACC/AHA/AAPA/ABC/ACPM/AGS/APhA/ASH/ASPC/NMA/PCNA Guideline f...

 FREE ACCESS

REVIEW ARTICLE

 PDF/EPUB

 Tools  Share

Jump to

Table of Contents

Preamble

2017

ACC/AHA/AAPA/ABC/ACPM/AGS/APhA/ASH/ASP C/NMA/PCNA Guideline for the Prevention, Detection, Evaluation, and Management of High Blood Pressure in Adults: A Report of the American College of Cardiology/American Heart Association Task Force on Clinical Practice Guidelines

Paul K. Whelton, Robert M. Carey, Wilbert S. Aronow, Donald E. Casey Jr,
Karen J. Collins, Cheryl Dennison Himmelfarb, Sondra M. DePalma,

 Details

 Related

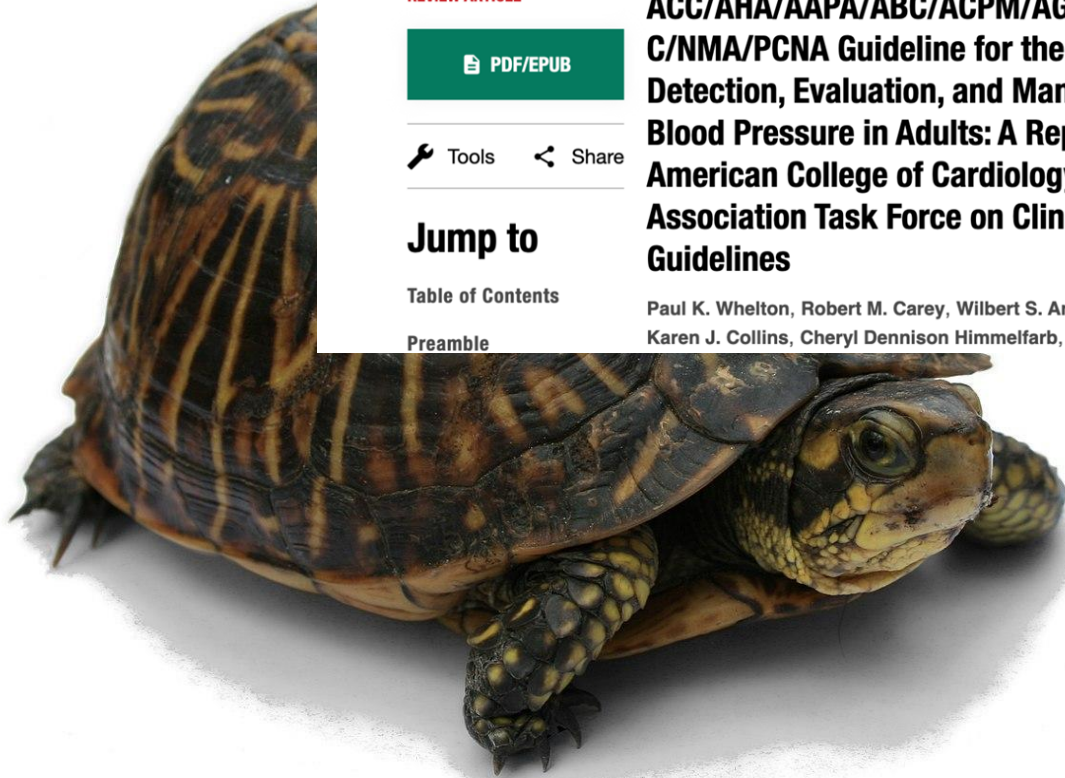
 References

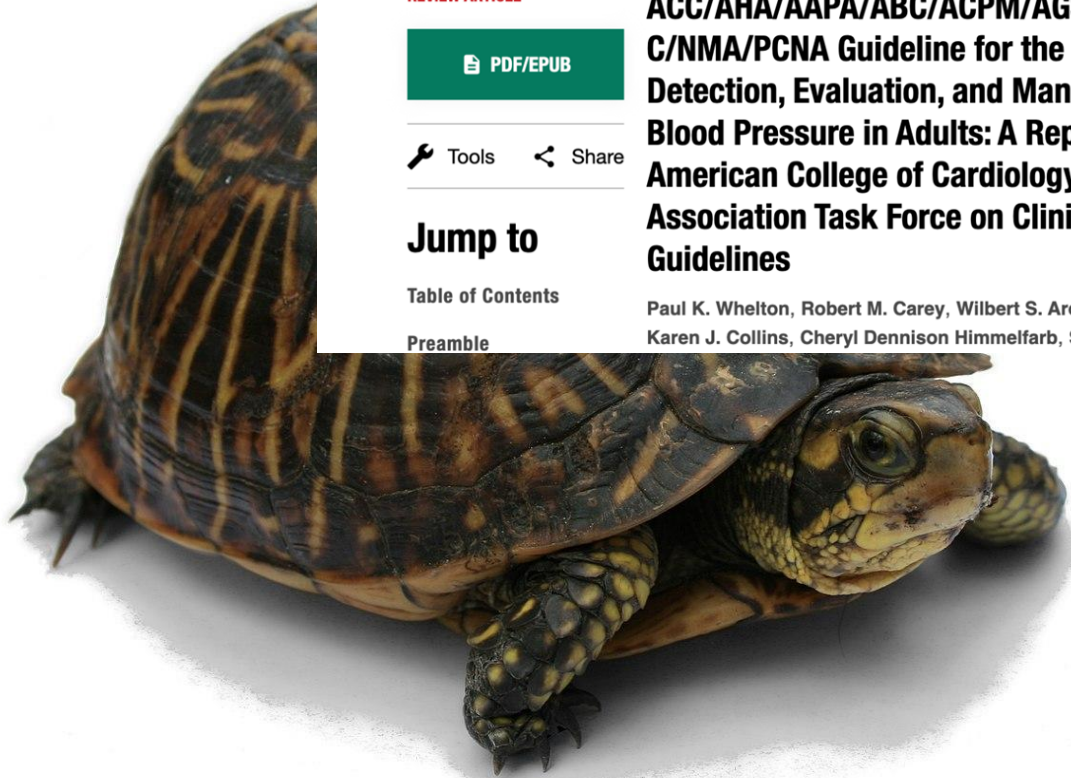
 Figures



June 2018
Vol 71, Issue 6

Non-pharmacologic
interventions







[Home](#) > [Hypertension](#) > [Vol. 71, No. 6](#) > [2017 ACC/AHA/AAPA/ABC/ACPM/AGS/APhA/ASH/ASPC/NMA/PCNA Guideline f...](#)

 **FREE ACCESS**

REVIEW ARTICLE

 **PDF/EPUB**

 Tools  Share

Jump to

[Table of Contents](#)

[Preamble](#)

2017

ACC/AHA/AAPA/ABC/ACPM/AGS/APhA/ASH/ASP C/NMA/PCNA Guideline for the Prevention, Detection, Evaluation, and Management of High Blood Pressure in Adults: A Report of the American College of Cardiology/American Heart Association Task Force on Clinical Practice Guidelines

Paul K. Whelton, Robert M. Carey, Wilbert S. Aronow, Donald E. Casey Jr,
Karen J. Collins, Cheryl Dennison Himmelfarb, Sondra M. DePalma,

 **Details**

 **Related**

 **References**

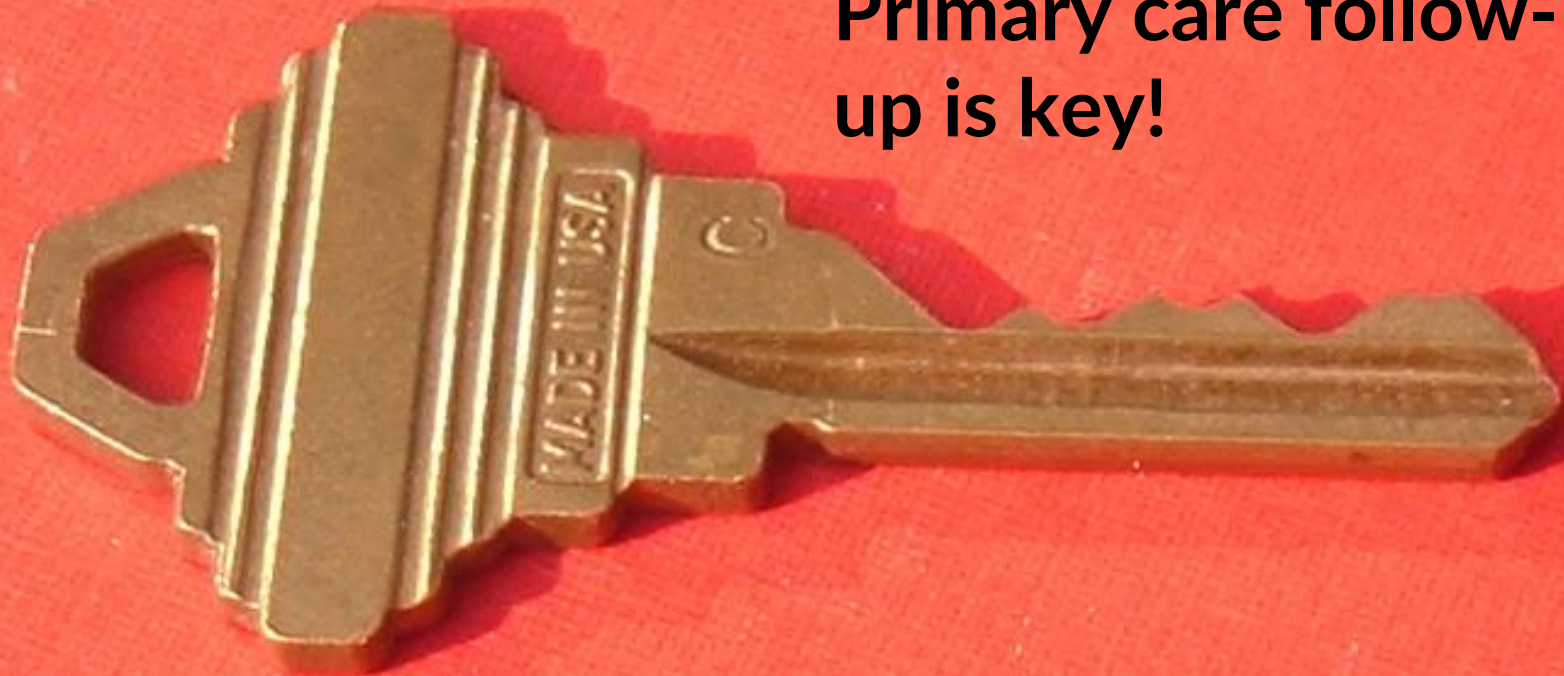 **Figures**



**June 2018
Vol 71, Issue 6**

Medications

Thiazide
CCB
ACE/ARB



Primary care follow-up is key!

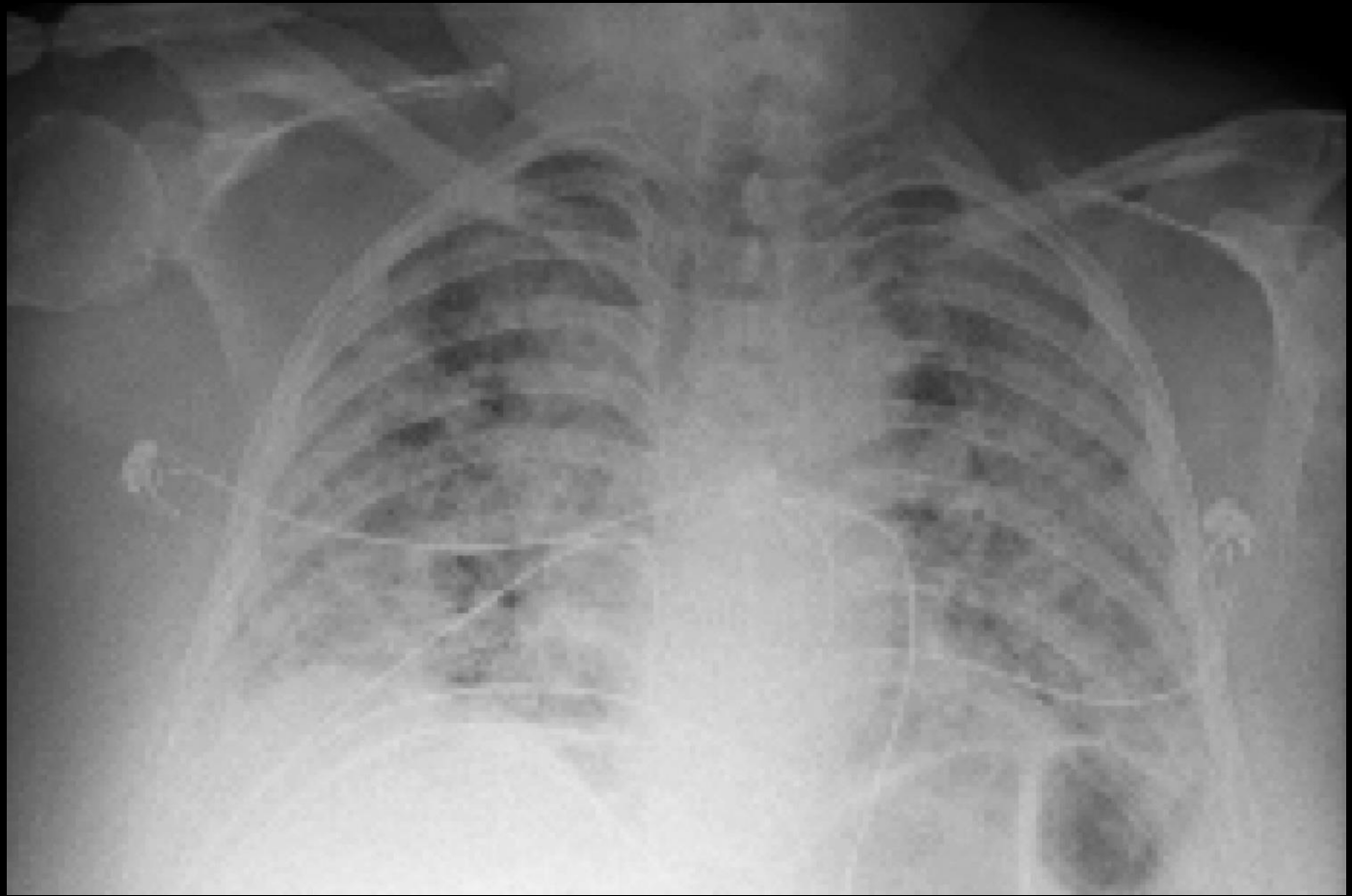
A close-up photograph of a red train door. The door is the central focus, with a blurred grey and blue area to the left. At the bottom of the frame, a yellow safety strip is painted on the ground, featuring the text "MIND THE GAP" in bold, yellow, sans-serif capital letters. The strip is bordered by a thin white line above and a thin red line below. The overall scene is brightly lit, suggesting an outdoor or well-lit indoor station environment.

MIND THE GAP



2023
2022
2021
2020
2019









Temporarily

CLOSED

due to COVID-19 pandemic

Original Research

CME: This article is offered for AMA PRA Category 1 Credit.™
See **CME Quiz Questions** on page 8.

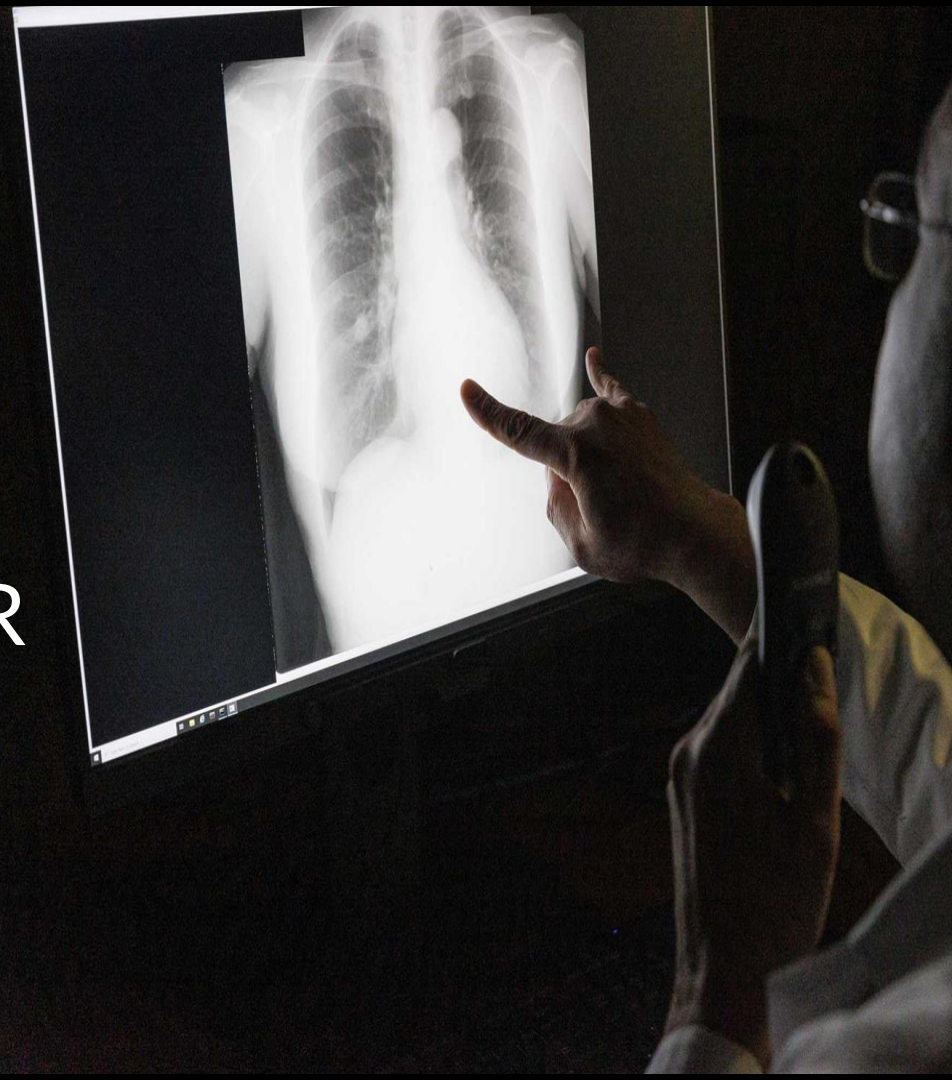


Chest X-Ray Findings in 636 Ambulatory Patients with COVID-19 Presenting to an Urgent Care Center: A Normal Chest X-Ray Is no Guarantee

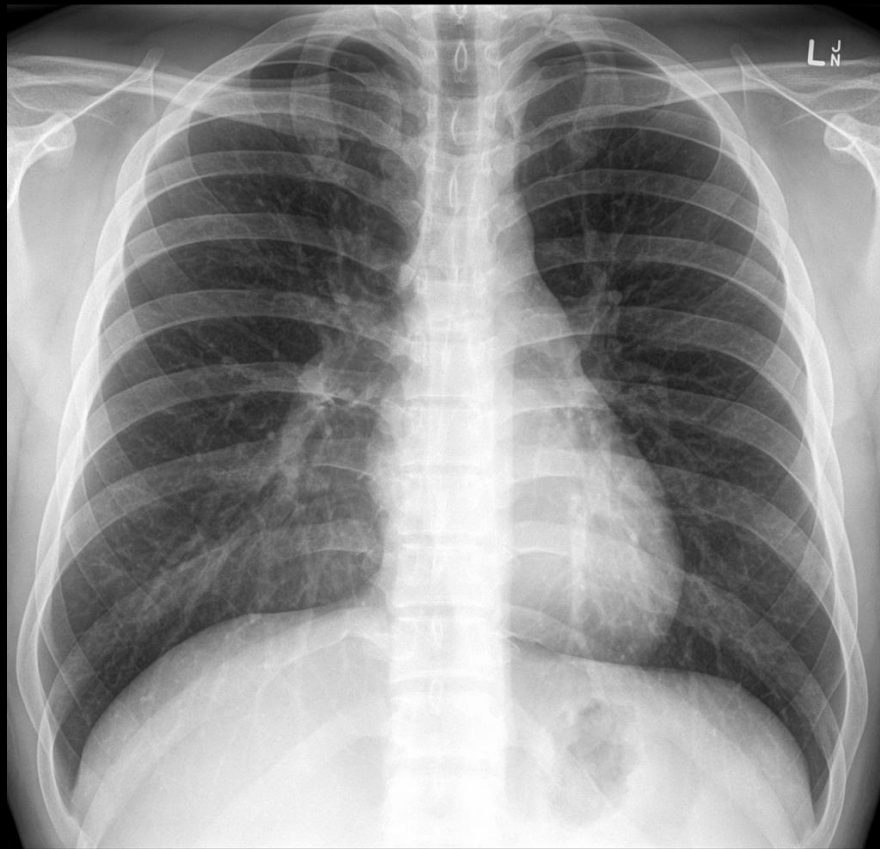
MICHAEL B. WEINSTOCK, MD, ANA ECHENIQUE, MD, DABR, JOSHUA W. RUSSELL, MD, MSC, FACEP, ARI LEIB, MD,
JORDAN A. MILLER, DO, DAVID J. COHEN, MD, STEPHEN WAITE, MD, ALLEN FRYE, NP and
FRANK A. ILLUZZI, MD, FACEP



- 100 Urgent Cares
- 636 patients
 - + COVID with CXR
- 12 Radiologists



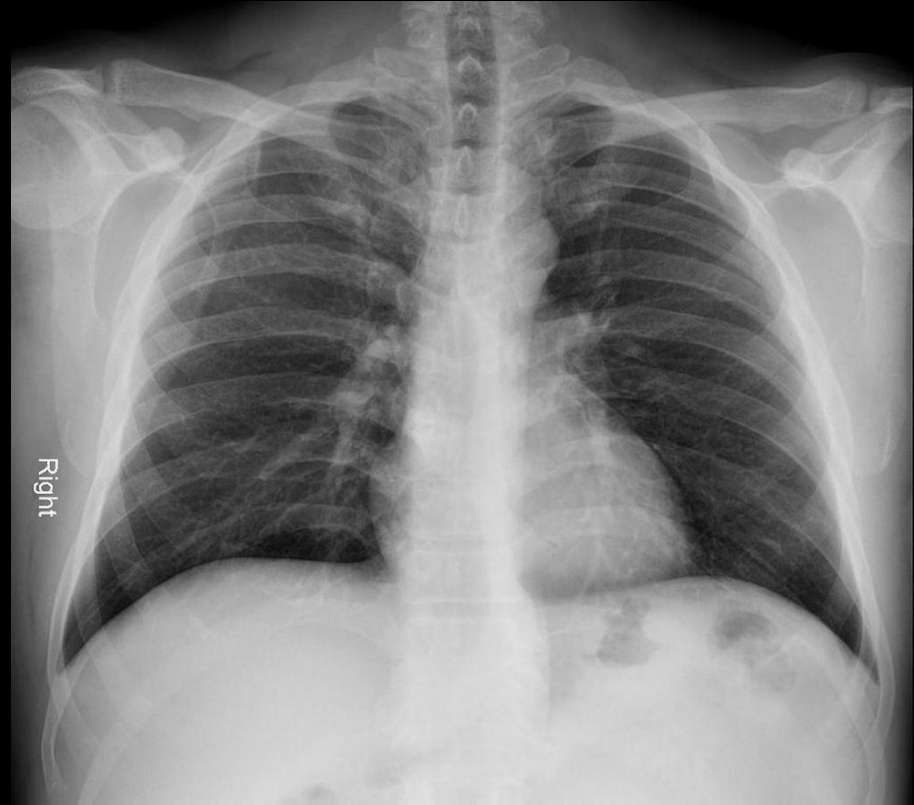
58.3%



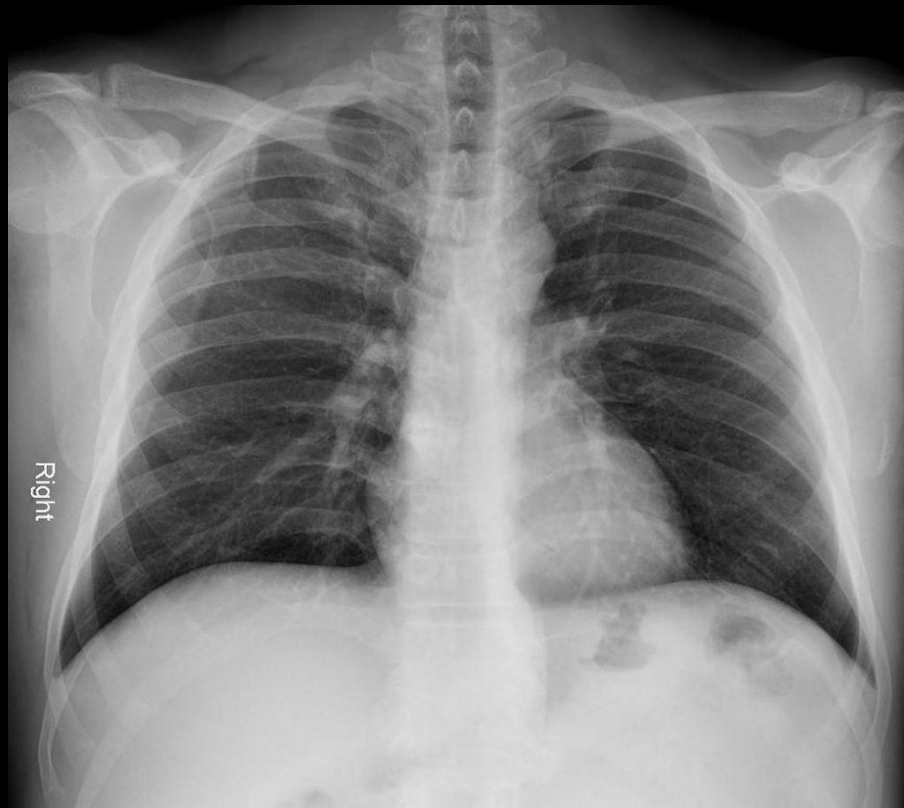
~74%= Mild

~25%= Moderate


~1.8% = Severe



89%







D

E

J

K

N

M

LETTERS

F

G

I

L

H

RUBE GOLDBERGER

Partial Fingertip Amputations







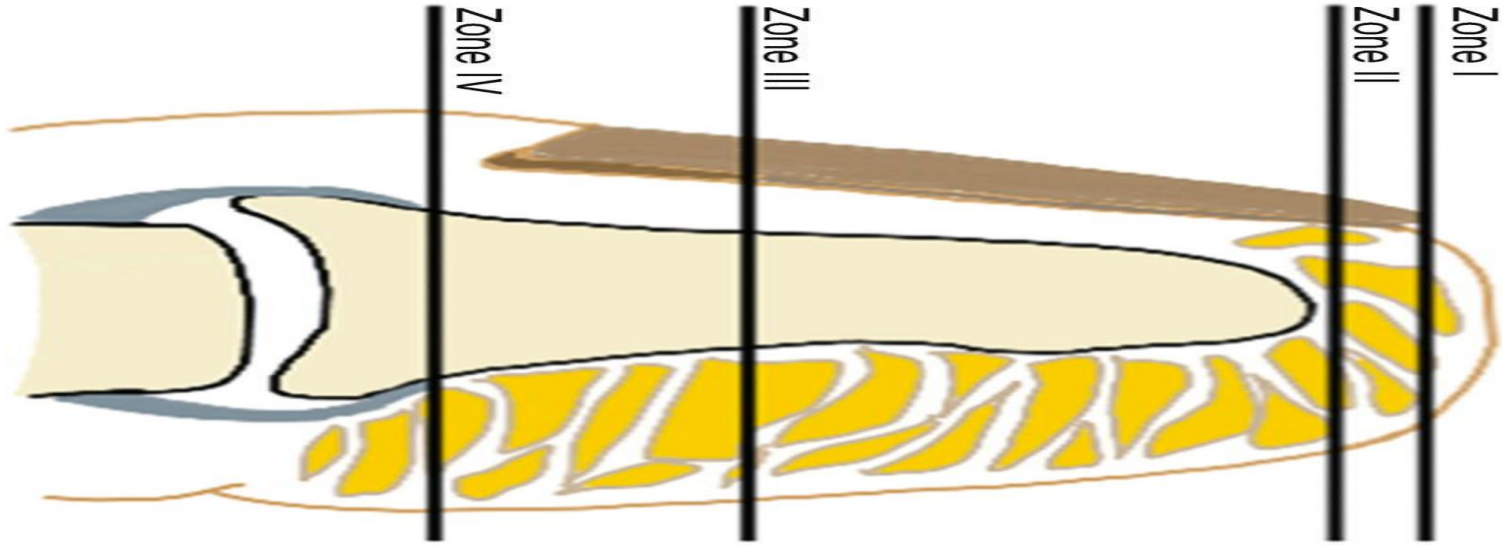
- 111 Hospitals
 - 77% “elective hand surgery”
 - 55% “basic emergency hand services”
 - 18% “occasional hand specialist coverage”
 - 7% “24/7 hand specialist coverage”

A wooden cutting board with numerous slices of light-colored sausages scattered across its surface. The background is a soft-focus white surface.

15,360 injuries

18% re-implanted





- Zone 1: Distal to nail bed
- Zone 2: Distal to distal phalanx
- Zone 3: Distal to lunula
- Zone 4: Distal to DIP joint

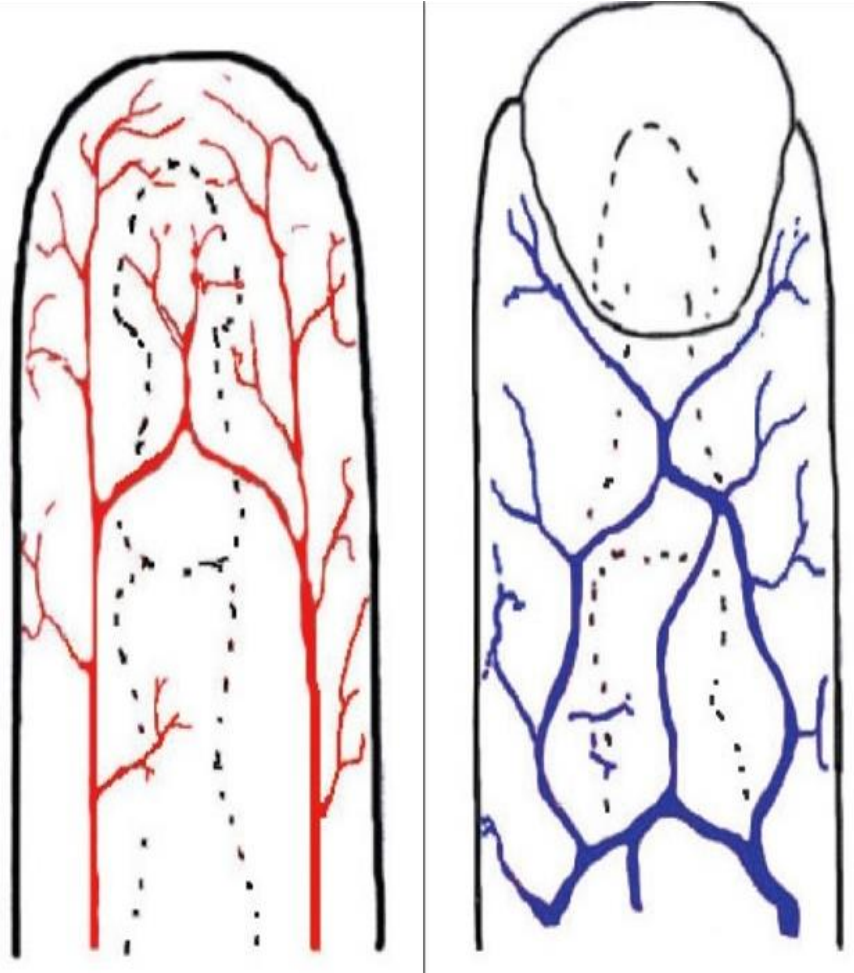
lunula

lunula





- 1 Artery and 1 vein
- Good tissue







MADE
IN
ENGLAND



Zone 4
Thumb/Index
Clean Cut
"Hand Experts"

Less is More?



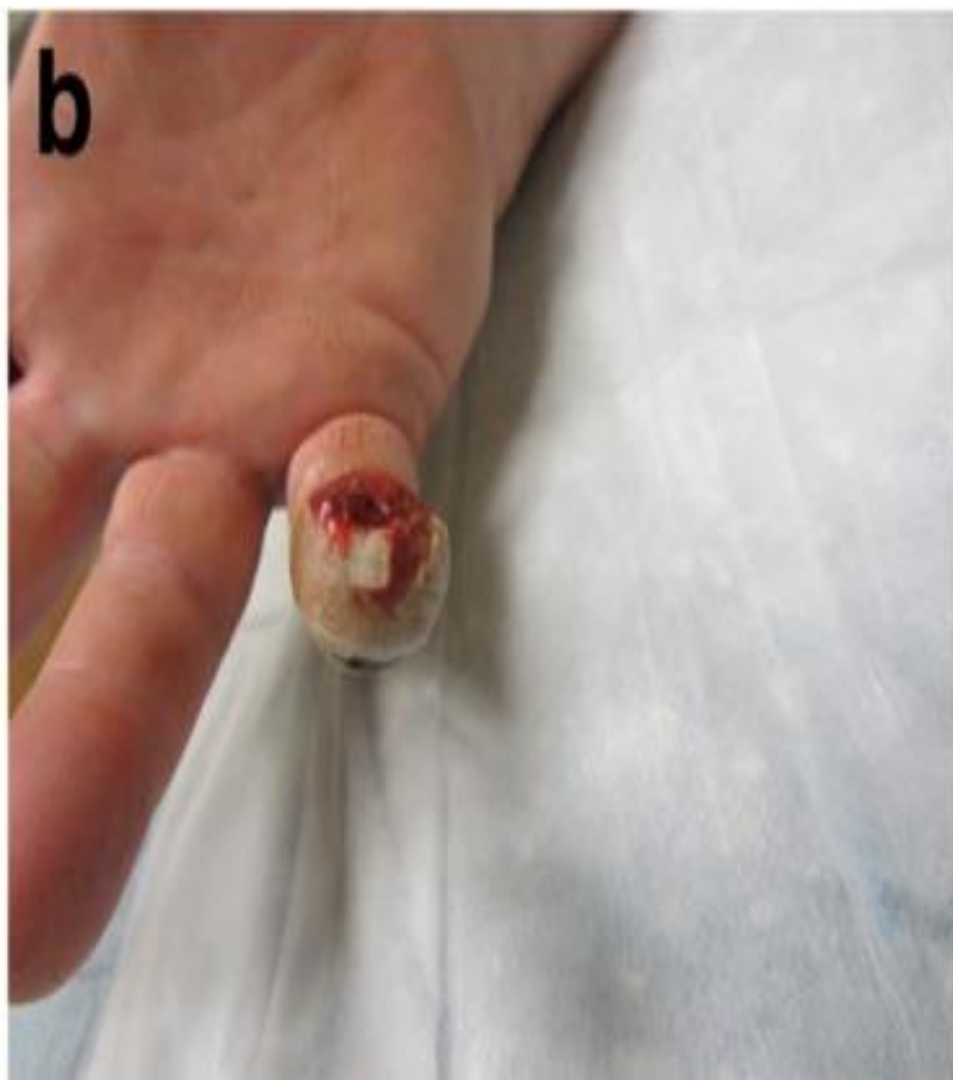
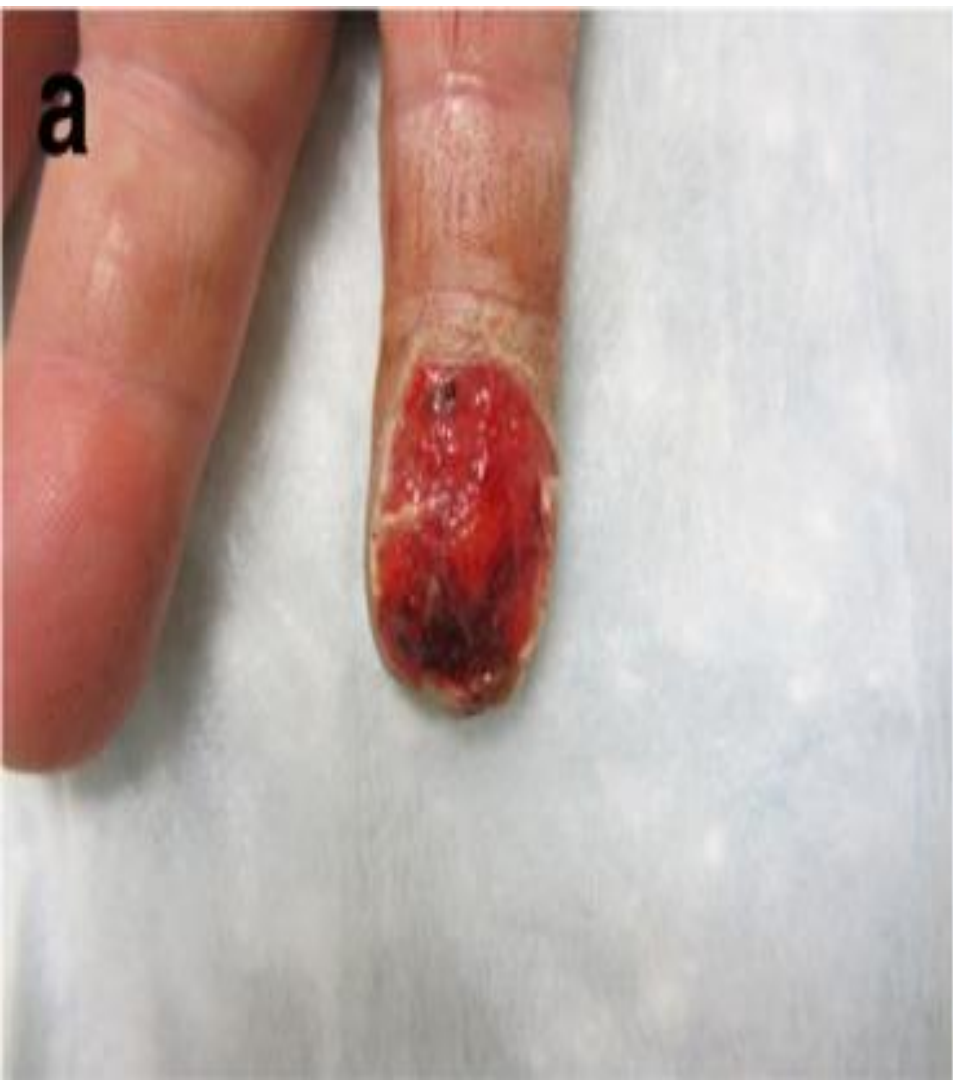


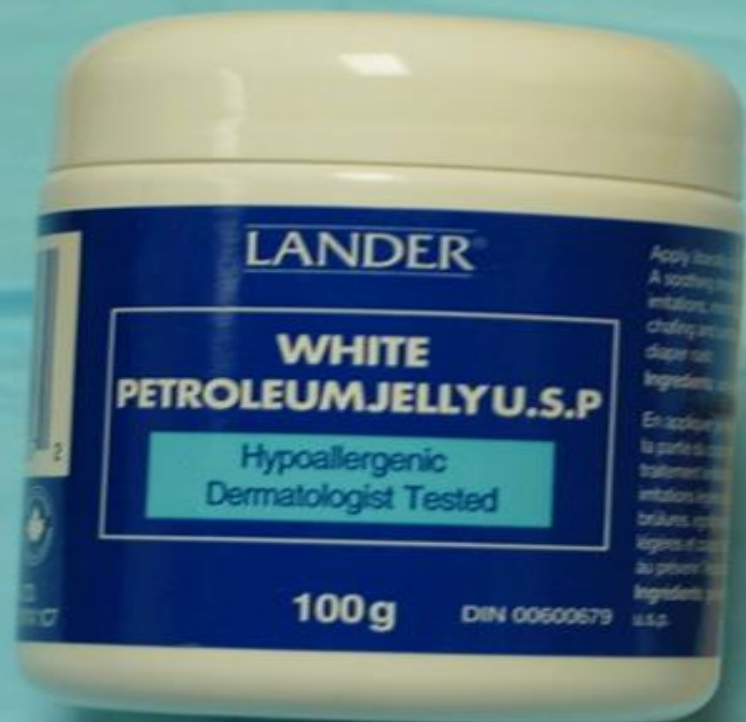
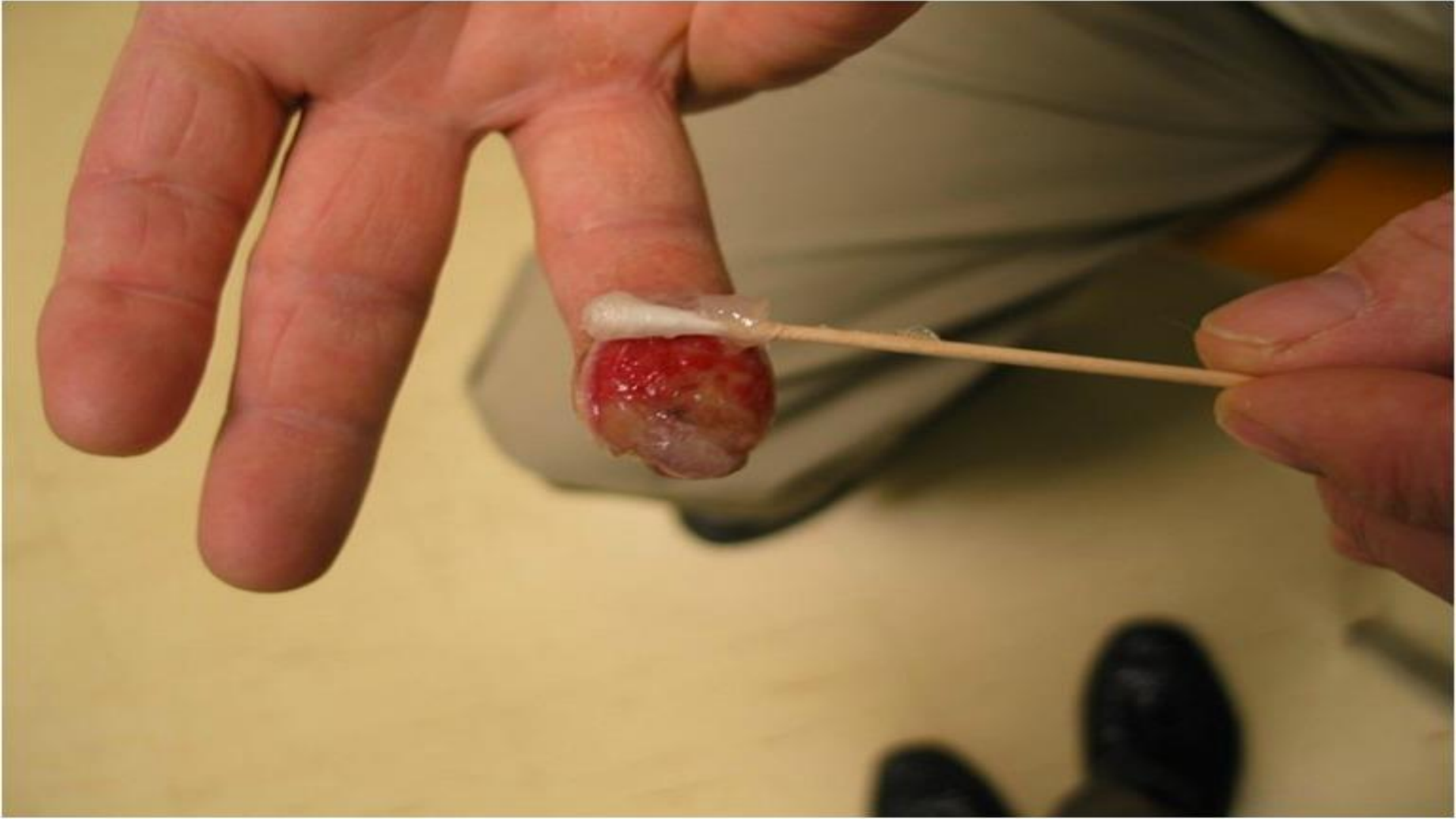~66%

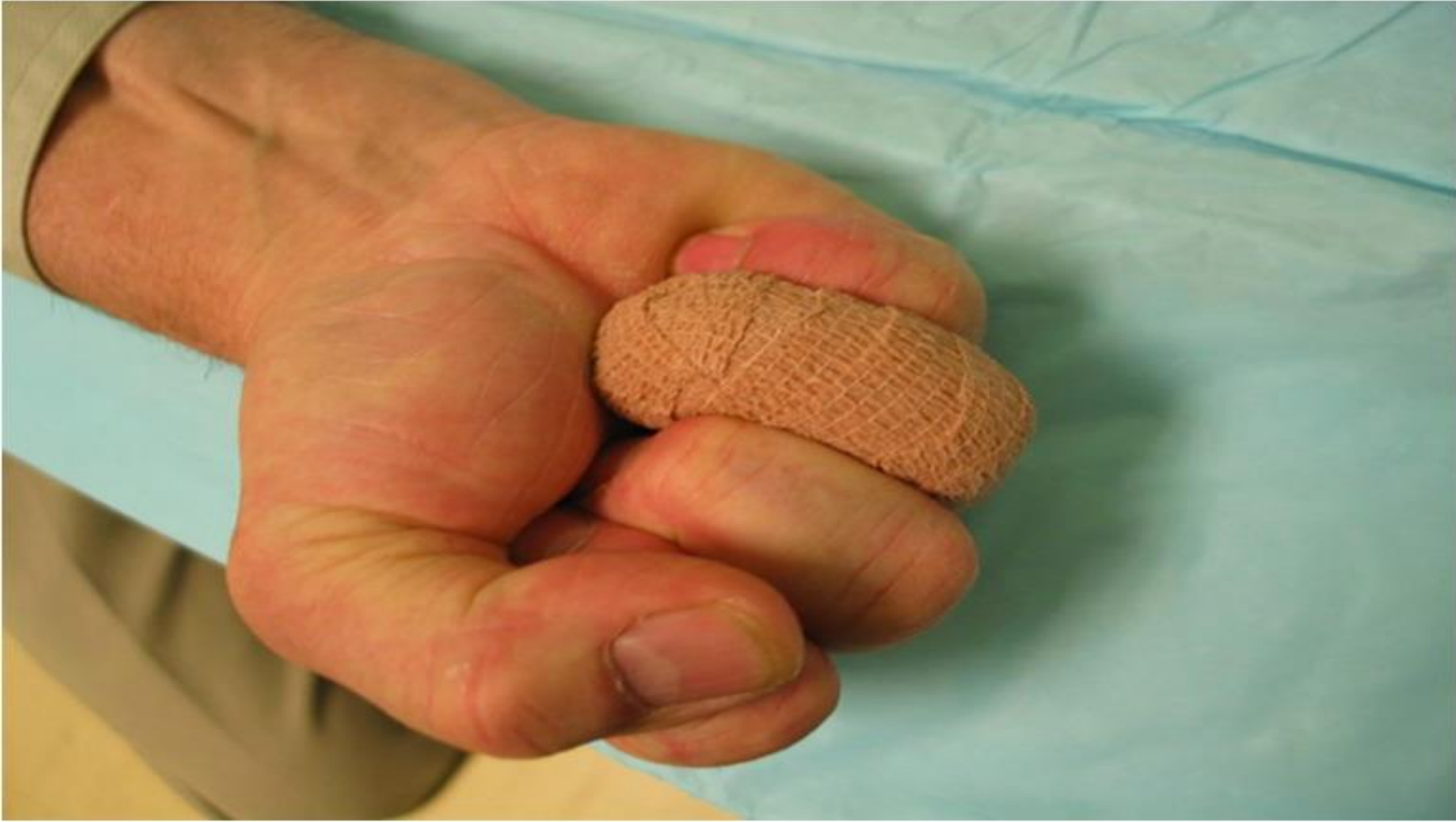<5mm is
acceptable

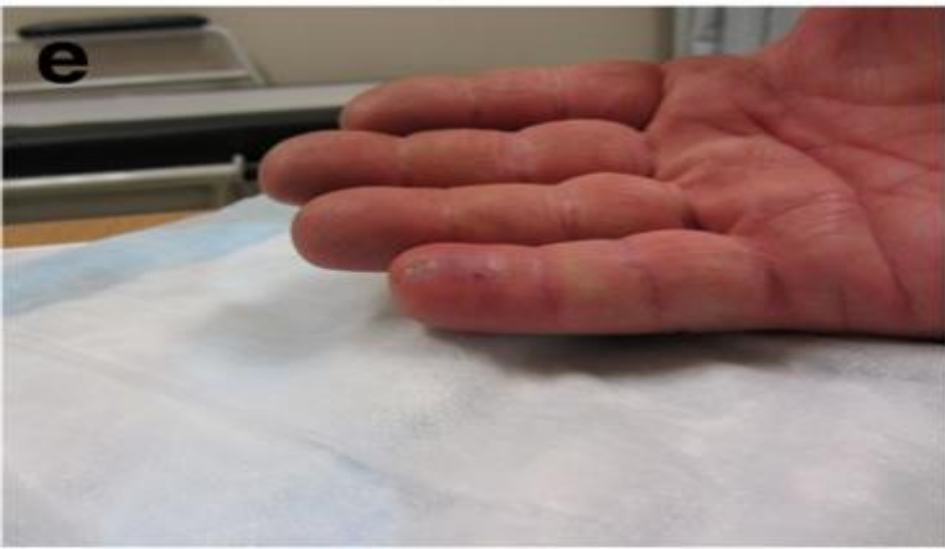
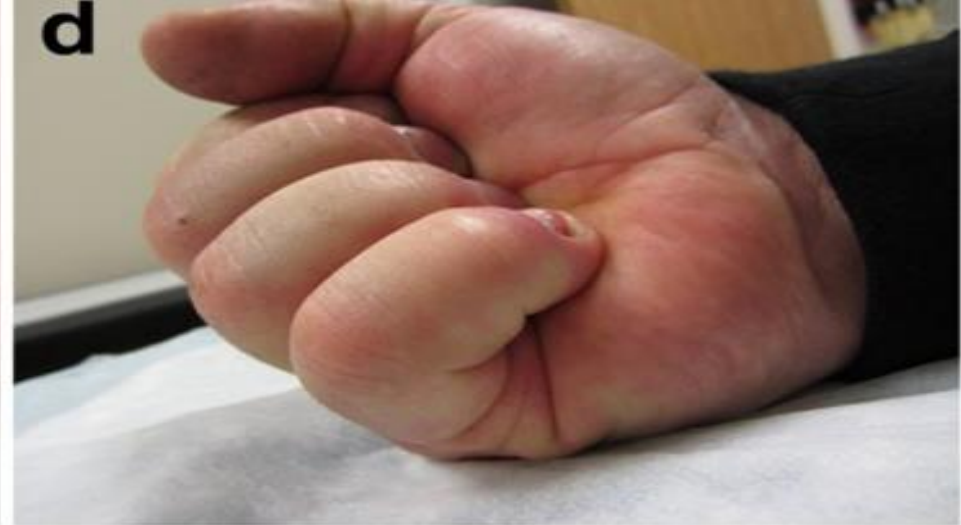
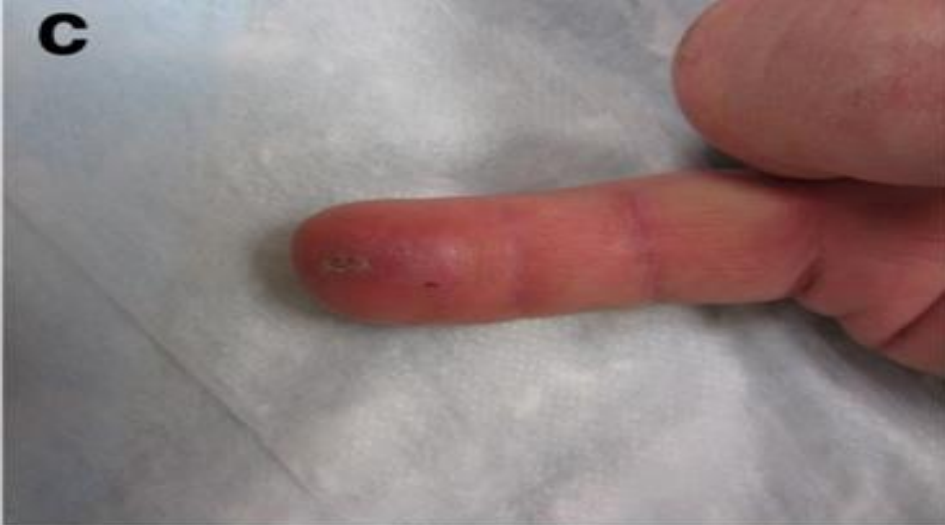








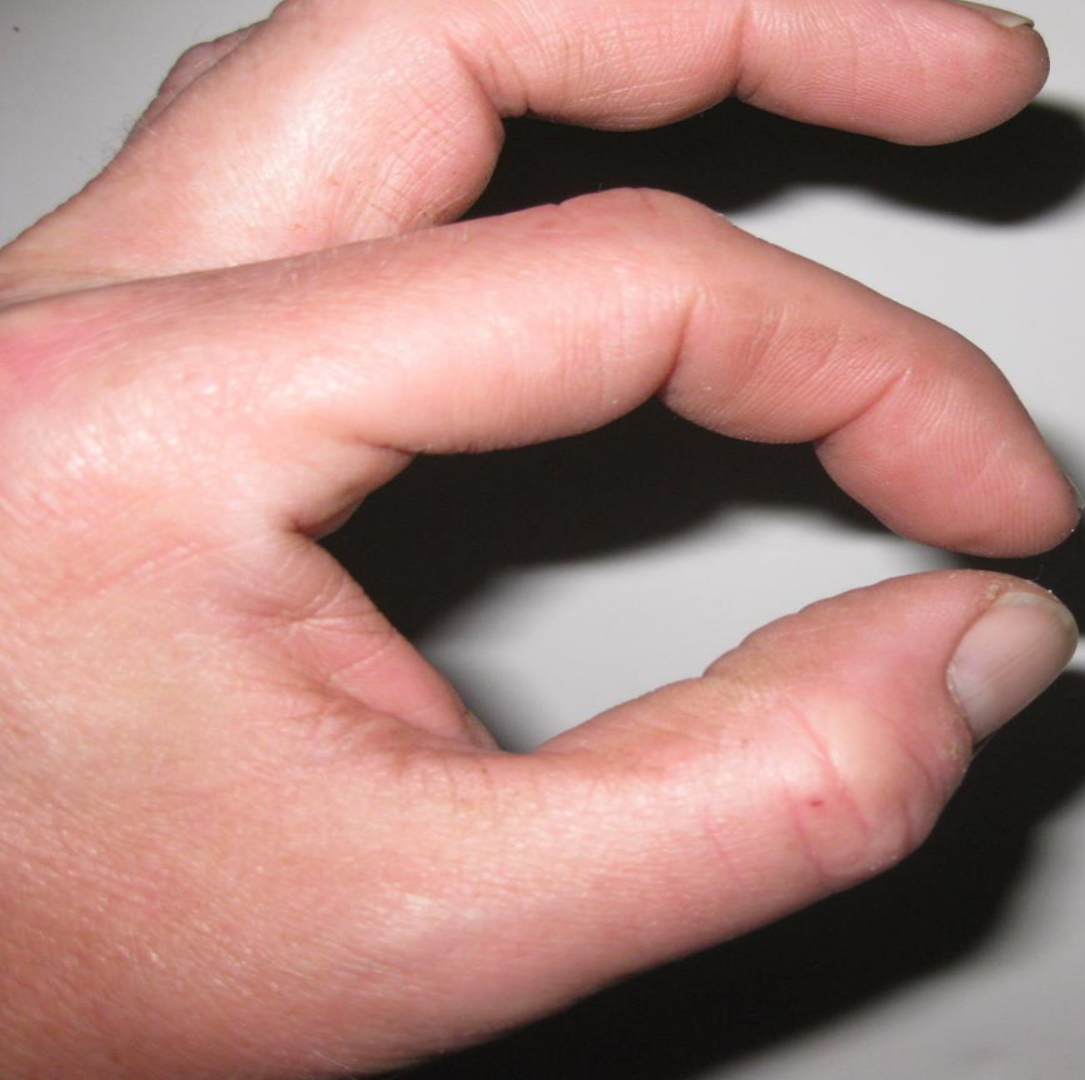
A close-up, high-angle shot of a man with a beard and glasses, wearing a dark blue shirt. He is looking down at a smartphone held in his right hand. His left hand is positioned near a white electrical outlet on a light-colored wall. The background is slightly blurred, showing a white surface and a circular hole in the wall. The overall scene suggests a professional or technical setting.

~1

month

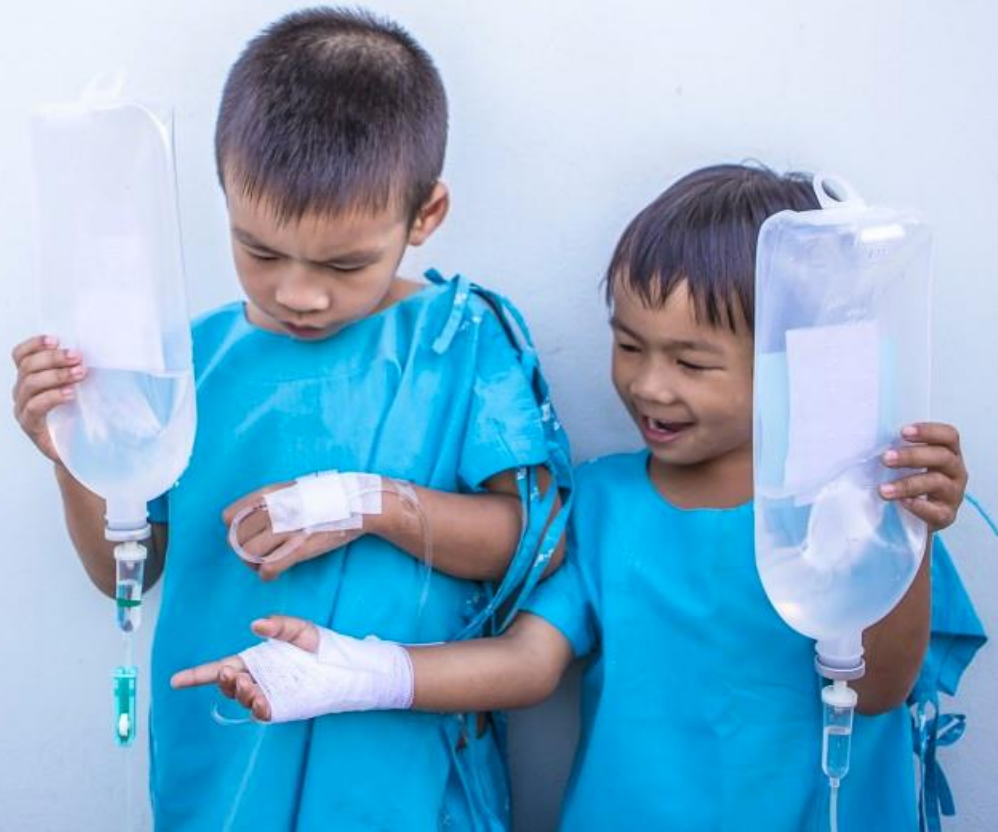


~6%



~ 86%





A photograph of a crowd of people at a concert or event. The scene is dark, with warm, golden light from stage lights illuminating the crowd. Many people have their hands raised in the air, some with fingers spread. The background is mostly black, with some blurred lights and the silhouettes of people. The overall atmosphere is energetic and celebratory.

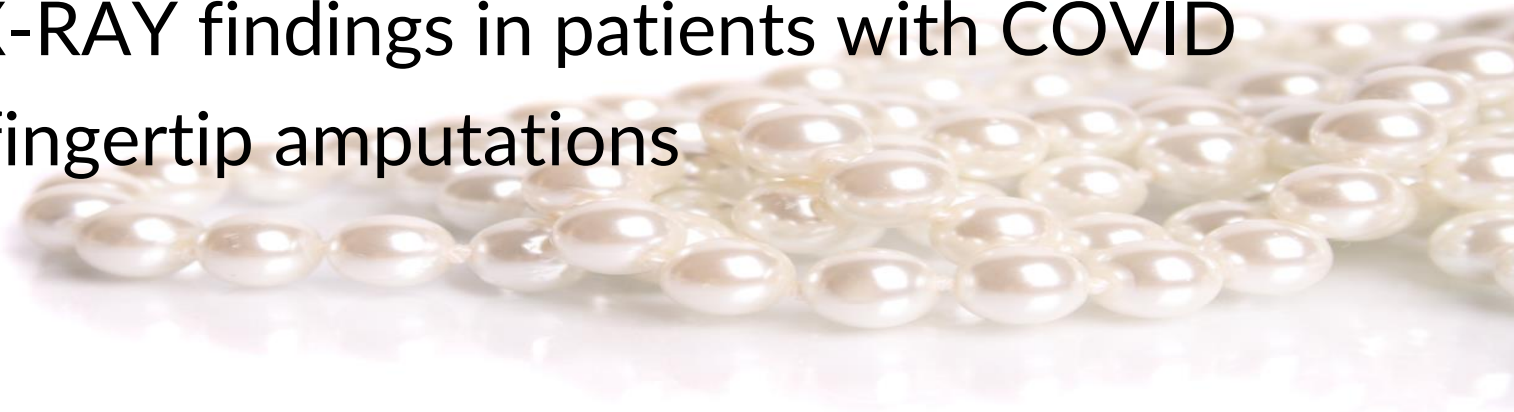1400 Patients

13 Infections

No cases of Osteomyelitis



- How to get a non-invasive pediatric urine sample and abscess drainage tips in kids.
- Management of asymptomatic hypertension
- Chest X-RAY findings in patients with COVID
- Partial fingertip amputations



DRIVING **CHANGE 2023**
THE URGENT CARE CONVENTION

Meet the team...

UCA URGENT CARE
ASSOCIATION®



Presented by UCA Affiliate

HIPPO
EDUCATION

Session Evaluation

- Your feedback is valuable, take a moment to complete the survey for this session.
- To claim CME, you must complete a separate survey available after the convention.

* How likely are you to recommend this **content** to a colleague?

Not likely at all Neutral Extremely likely

0 1 2 3 4 5 6 7 8 9 10

What did you find most valuable about this **content**?

What would have made this **content** better?