

# Pediatric Foreign Body Removal: Ears, Noses and Fish Hooks...Oh My!

Richard Bruckner, M.D.



The Pediatric Urgent  
Care Conference



# Disclosure

- I have no financial disclosures

The Pediatric Urgent  
Care Conference



# Outline

- Background/Epidemiology
- Tools
- Foreign Bodies
  - Nasal
  - Otic
  - Fish Hooks!!!
- Skills Stations



The Pediatric Urgent  
Care Conference



DRIVING **CHANGE 2023**  
THE URGENT CARE CONVENTION

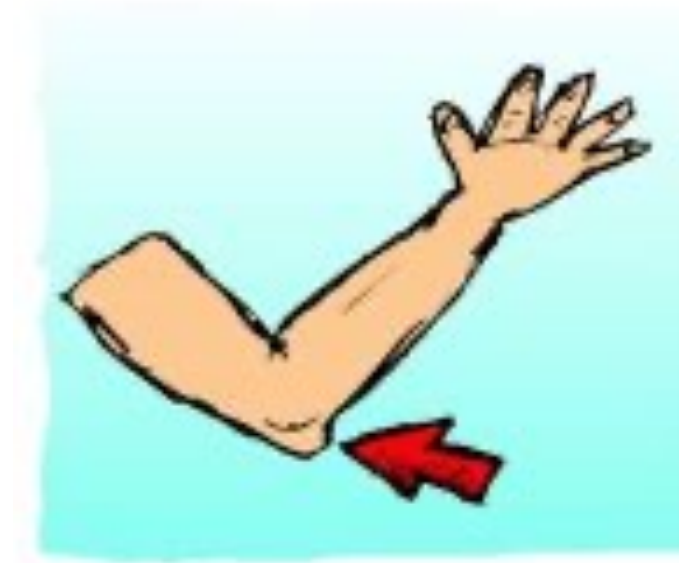
# Background/Epidemiology

The Pediatric Urgent  
Care Conference

**PUCC** @ UCA  
By **PM** Pediatric  
Care

# “Nothing smaller than an elbow”

- Children put objects in places that they shouldn't
- Most nasal/otic foreign bodies in children aged 2 to 8 years
  - Less likely under 9 months
  - Males > Females
  - Cognitively/Behaviorally Delayed
  - Lower Socio-economic Status
- Right side more common
- **Always re-examine after removal**
  - Children may insert multiple objects!!!



# Foreign Body Material Matters

- Range of material is limitless
- Classification
  - Animal
  - Vegetable
    - Paper, seeds, cotton swab
    - May swell if moist
    - **Seeds may sprout!**
  - Inorganic
    - Beads, erasers, toys
    - Magnets and Batteries!



# Magnets and Batteries

- Magnets
  - Only an issue in multiple
  - When 2 or more magnets attract across tissue planes, pressure necrosis can occur
- Button Batteries
  - Thermal burns from current
  - Leakage of alkaline contents can cause liquefactive necrosis
  - Lead to septal perforation within 4-6 hours



The Pediatric Urgent  
Care Conference



# Emergent versus elective

- Risk of leaving versus removing

- Damage to surrounding structures

- Local irritation → Pressure necrosis → Mucosal ulceration → Erosion → Epistaxis

- Inflammation → Sinus drainage obstruction → Sinusitis

- Nasal foreign bodies can be aspirated

- Sprouting risk (if seeds)



The Pediatric Urgent  
Care Conference



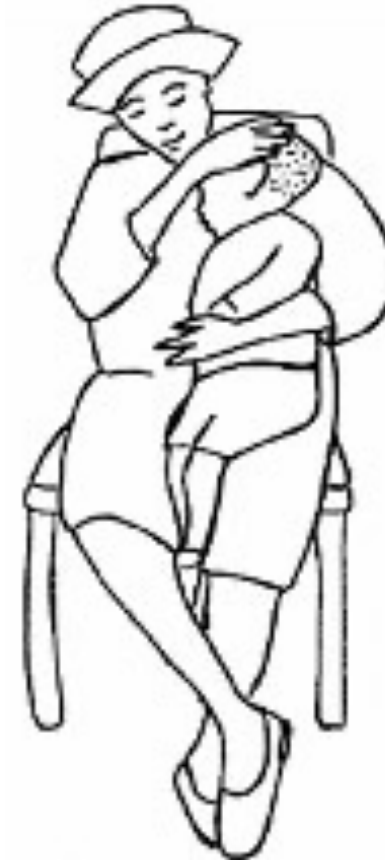# The Approach

- First attempt is likely to be most successful
- “Unsuccessful attempts jeopardizes subsequent effort”
  - Bleeding
  - Obstruction
  - Anxiety and Pain!
- Therefore, choose your most likely successful technique first!



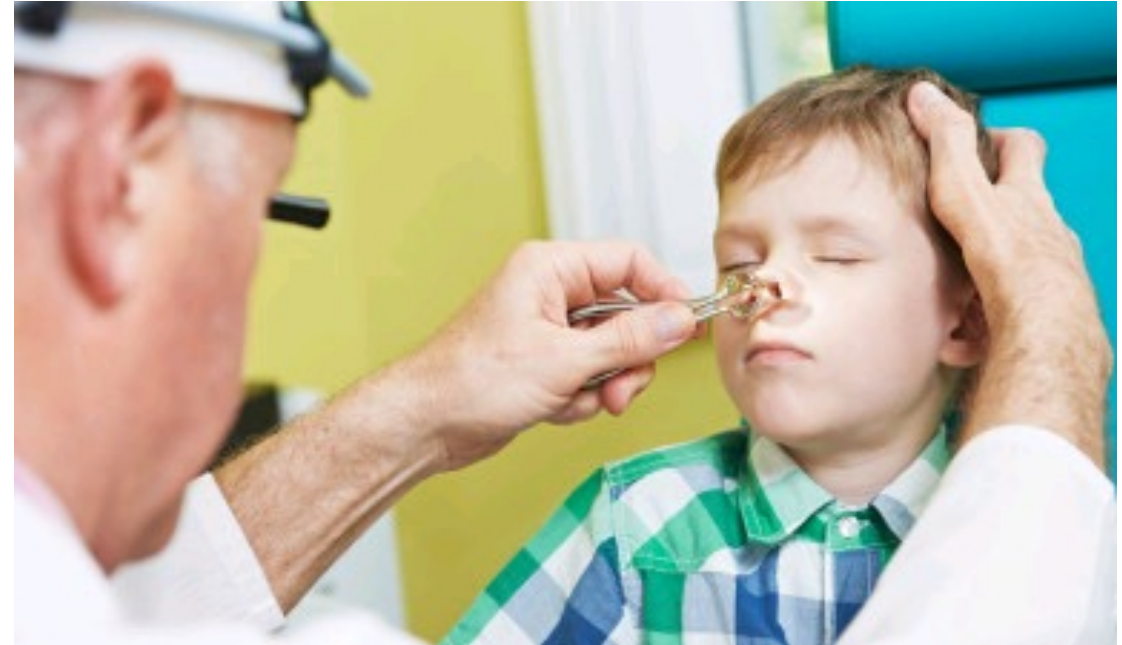# Minimizing Anxiety/Pain

- Involvement of parents
  - Explaining the procedure
  - Positioning
  - Distraction
- Intranasal medications
- Restraint if necessary



# Visualization

- Traditional Otoscope
  - Inability to insert instrument/remove material
- ENT speculum with Headlamp
  - Hands free and able to use tools
  - Can use magnifying loopes



The Pediatric Urgent  
Care Conference



DRIVING **CHANGE 2023**  
THE URGENT CARE CONVENTION

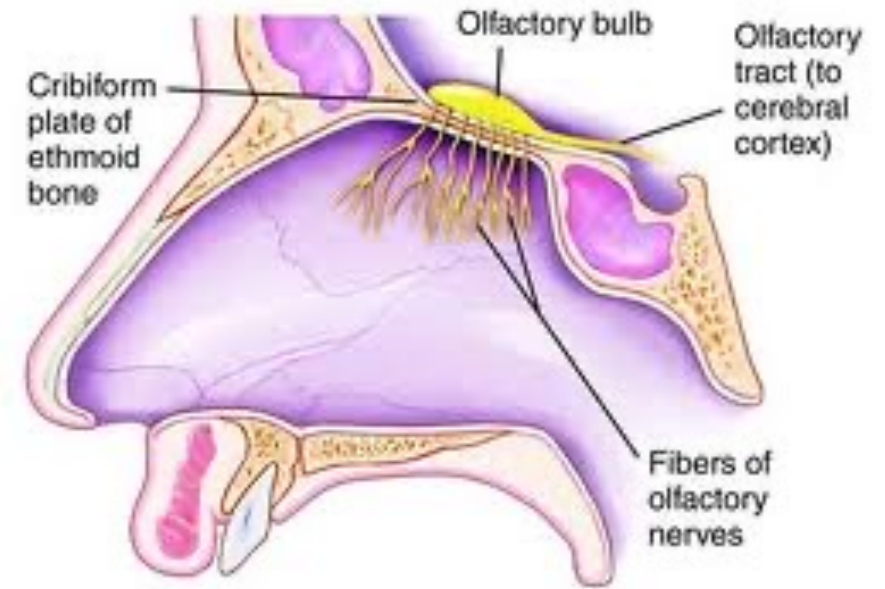
# Nasal Foreign Bodies

The Pediatric Urgent  
Care Conference

**PUCC** @ UCA  
By **PM** Pediatric  
Care

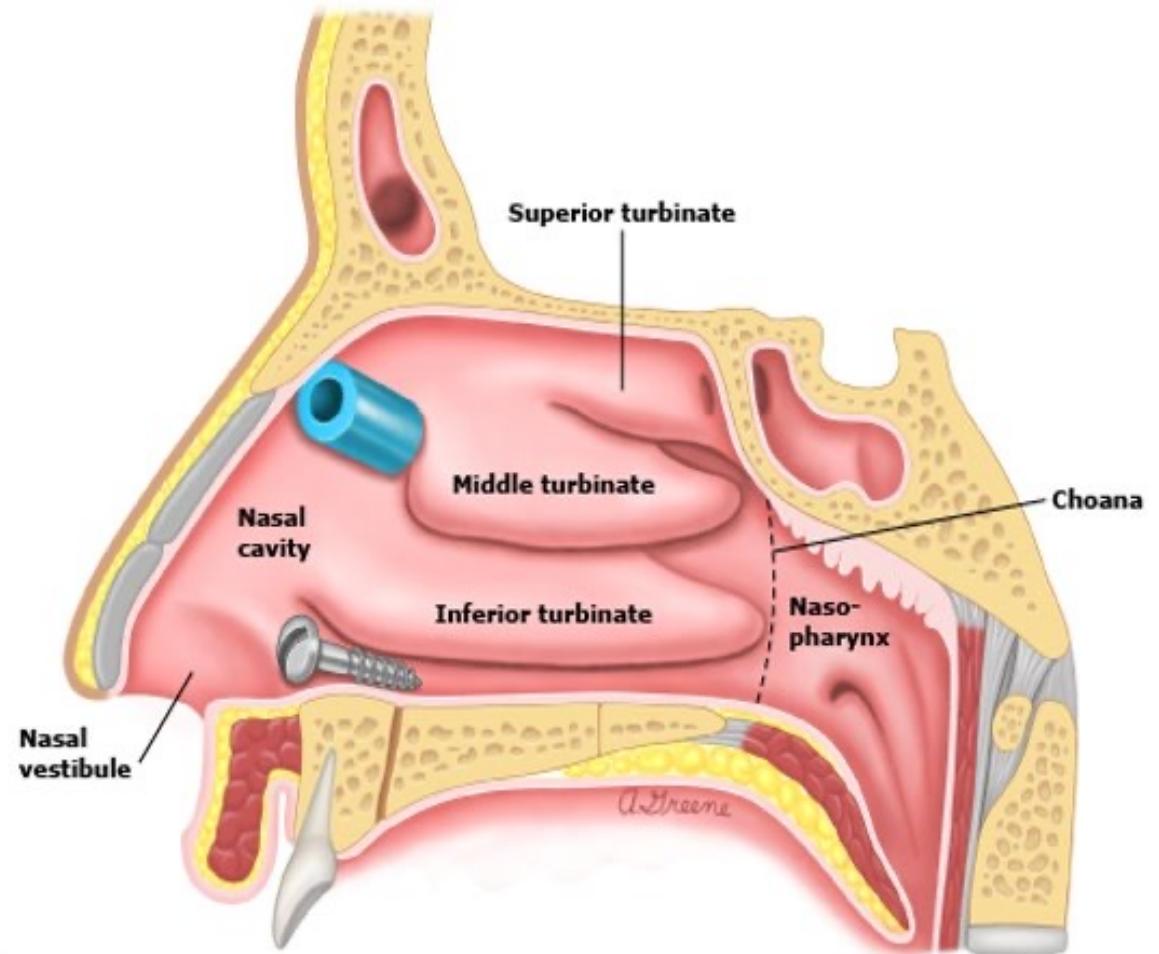
# Nasal Foreign Body Removal

- Anatomic landmarks
  - Aim straight back to ear on same side
  - Instrumentation superior and medial may hit cribriform plate
- Topical analgesic and vasoconstrictors
  - Anesthetize
  - Minimize bleeding -> better visualization



# Nasal Foreign Body Removal

- Usual location of nasal foreign bodies
  - Floor of nasal passage near inferior turbinate
  - Superiorly just anterior to the middle turbinate



# Nasal Foreign Body Removal Risks

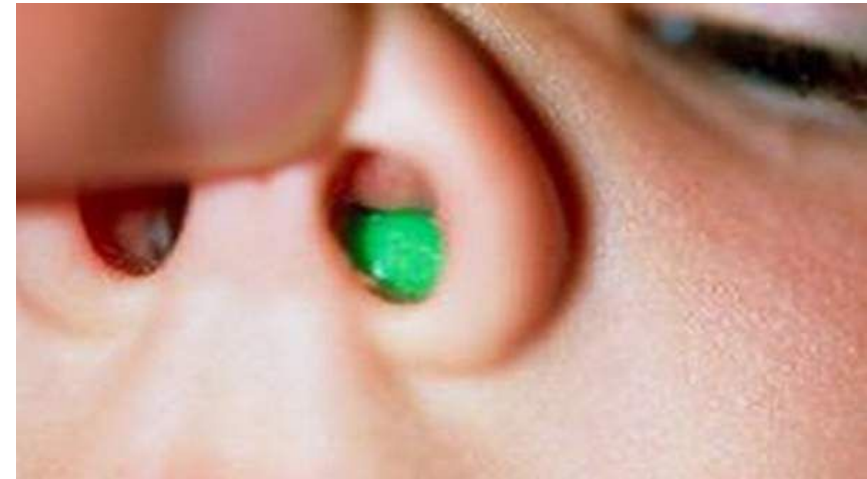- **Aspiration**

- Position patient head elevated/upright

- Bleeding

- Discomfort

- Posterior displacement

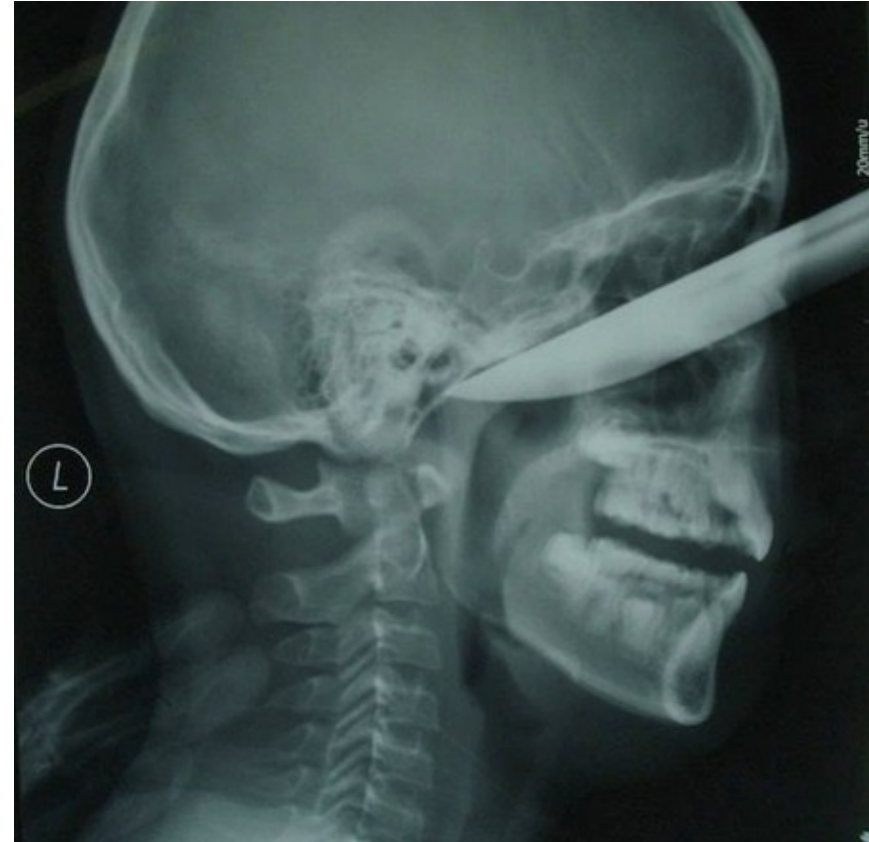

The Pediatric Urgent  
Care Conference



# Nasal Foreign Body Referral

- Embedded
- Unable to visualize
- Superior-medial placement
- Penetrating injuries
- Respiratory distress
- Bleeding diathesis



The Pediatric Urgent  
Care Conference



DRIVING **CHANGE 2023**  
THE URGENT CARE CONVENTION

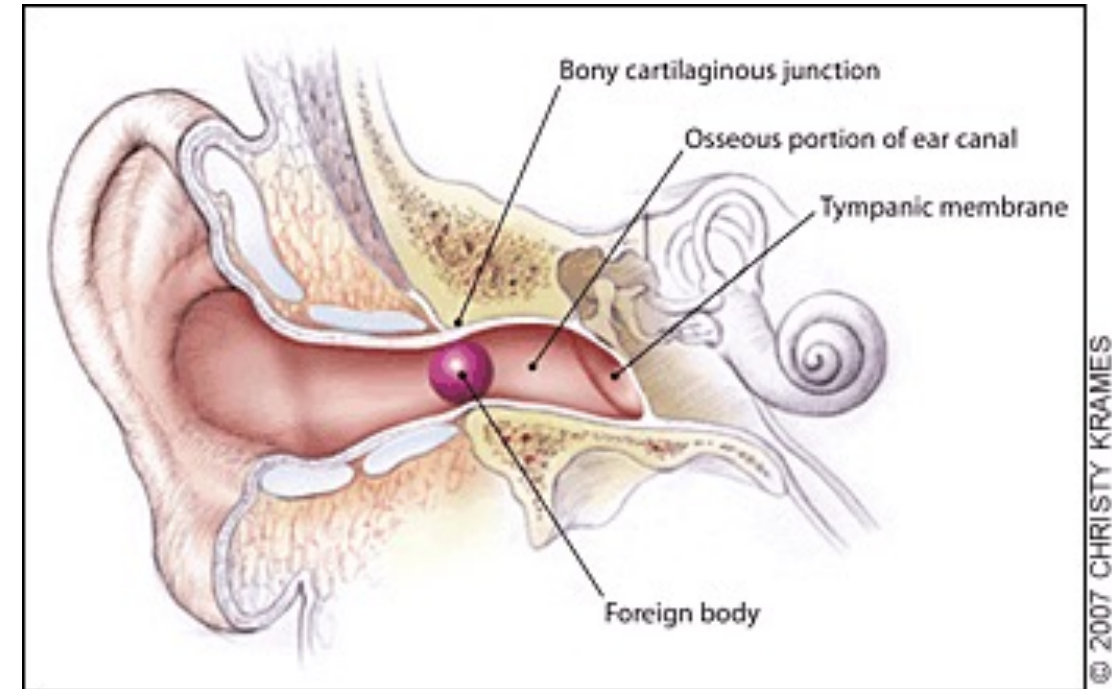
# Otic Foreign Bodies

The Pediatric Urgent  
Care Conference

**PUCC** @ UCA  
By **PM** Pediatric  
Care

# Otic Foreign Bodies

- Anatomy
  - Tight, hard, sensitive spot
- Topical anesthesia less effective
- Bleeding risk
- Consider limited number of attempts

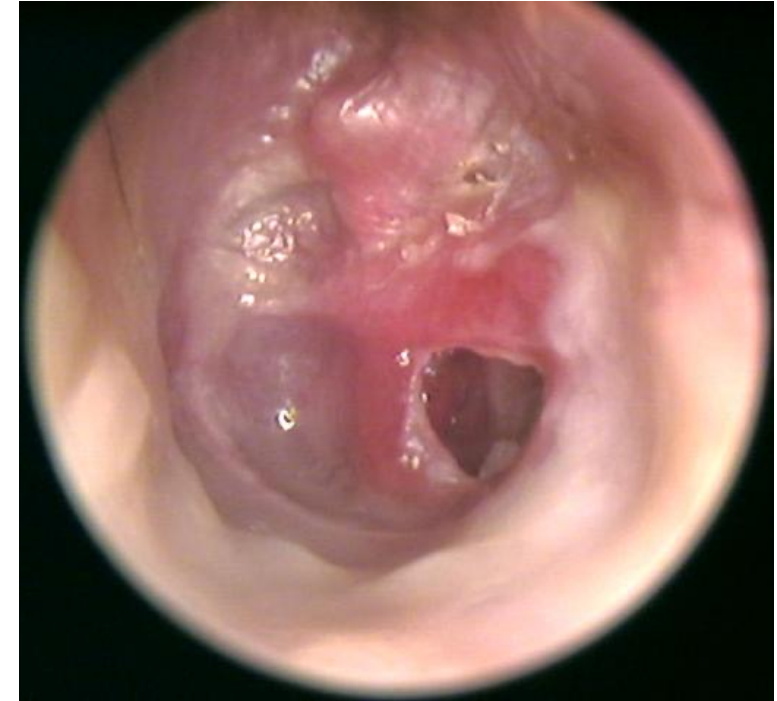

The Pediatric Urgent  
Care Conference



# Otic Foreign Body Removal Risks

- Bleeding
- Discomfort
- Posterior displacement
- Tympanic membrane perforation

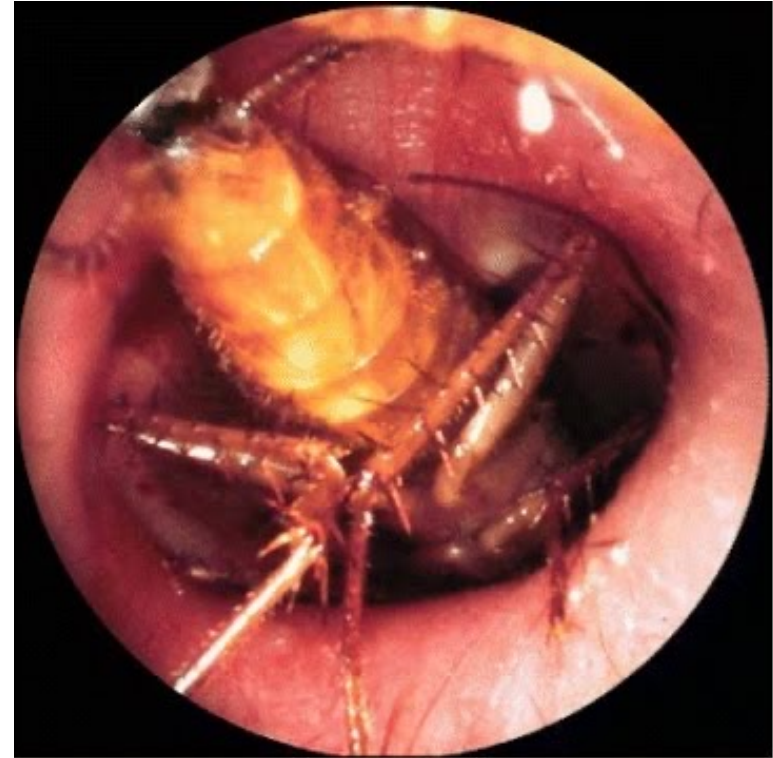

The Pediatric Urgent  
Care Conference



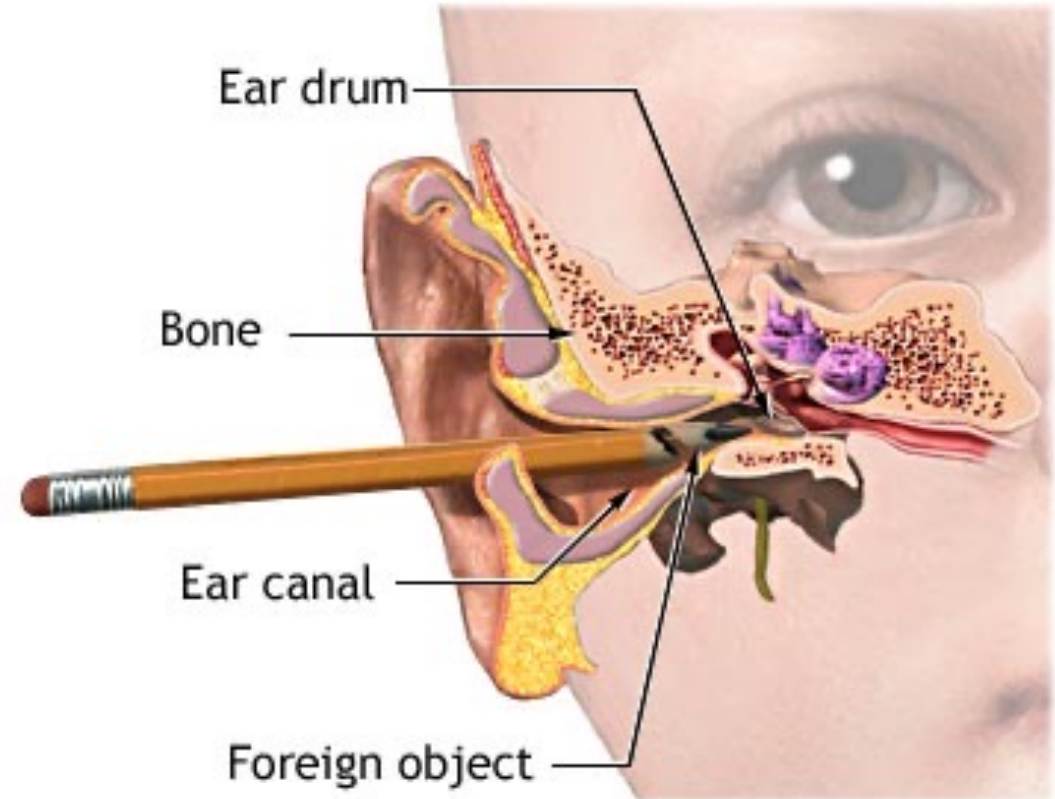
# Insects

- Insects lodged in ears are **VERY painful**
- Kill the insect first
  - Viscous lidocaine
  - Mineral oil
- Remove with forceps
  - Goal to remove intact
- Irrigate after removal to ensure all pieces are gone



# Otic Foreign Body Referral

- Unable to remove
- Resting against tympanic membrane
- Perforation of tympanic membrane



DRIVING **CHANGE 2023**  
THE URGENT CARE CONVENTION

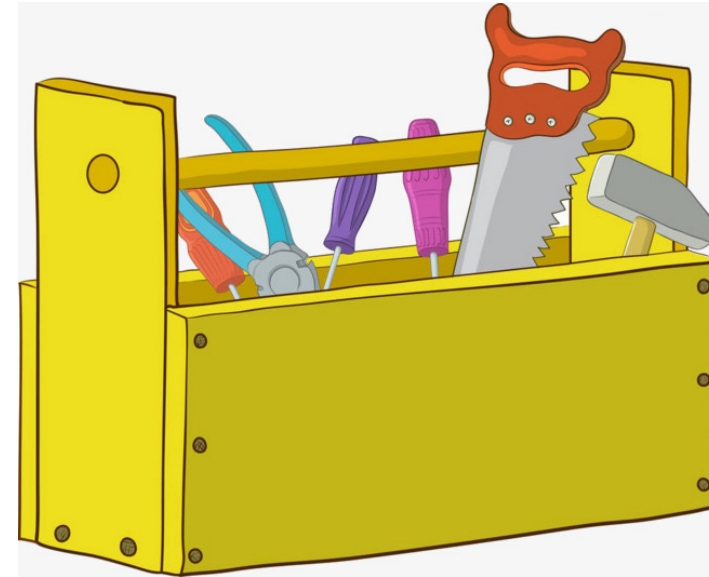
# Tools

The Pediatric Urgent  
Care Conference

**PUCC** @ UCA  
By **PM** Pediatric  
Care

# Foreign Body Removal Techniques

- Indirect
  - Irrigation
  - Pressure
  - Catheter
- Direct
  - Instruments
  - Glue

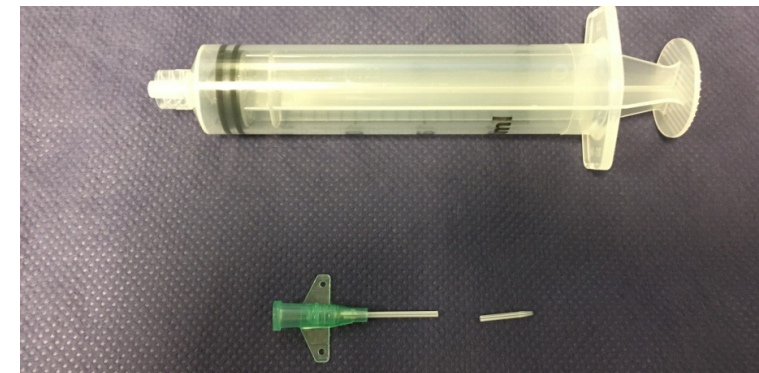


# Irrigation

- Useful for small objects close to the tympanic membrane
- Not indicated for nasal foreign bodies
  - May cause posterior displacement and aspiration
- Water or normal saline
  - Body temperature
- Contraindication
  - Tympanic membrane perforation
  - Vegetable material/sponge that may swell
  - Button batteries

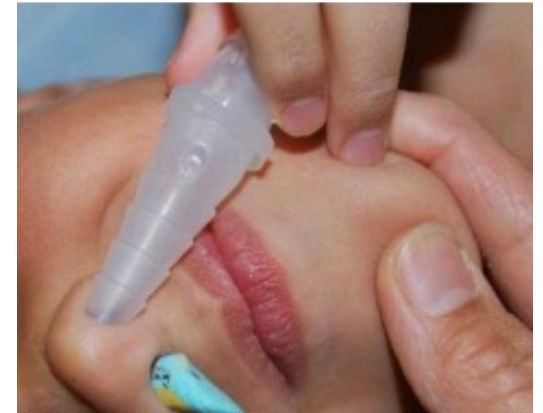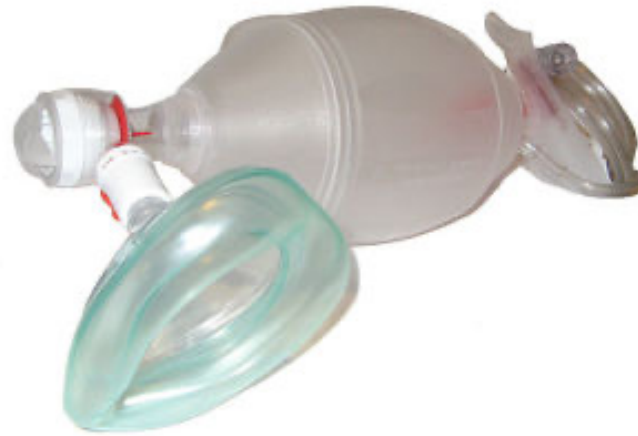# Irrigation Technique

- Cut off end of “butterfly cannula” vs. the “Elephant”
- 20ml syringe attach to 14 gauge cannula
  - Develops 60mm Hg pressure
- Direct water at superior portion of ear canal





# Positive Pressure

- Nasal foreign body
- Occlude **unaffected** nares
- Give positive pressure
  - Bag Valve Mask
  - Maternal “kiss”
  - Modified air tubing
- Works best for large, fully occlusive objects
- One case report of barotrauma



# Negative Pressure (suction)

- Works best for round, smooth objects which are difficult to grasp
- Needs to provide 100-140 mmHg with a solid seal
  - Thin metal suction catheter (Frazier tip with soft tip)
  - Most other catheters not thin enough to reach object with enough pressure
  - Hognose Otoscope



# Glue

- Most effective for smooth, round objects that are difficult to grasp
- Foreign body must be **dry** and **easily visualized**
- Wound adhesive is not strong enough
- Risk of accidental contact with mucosa or tympanic membrane



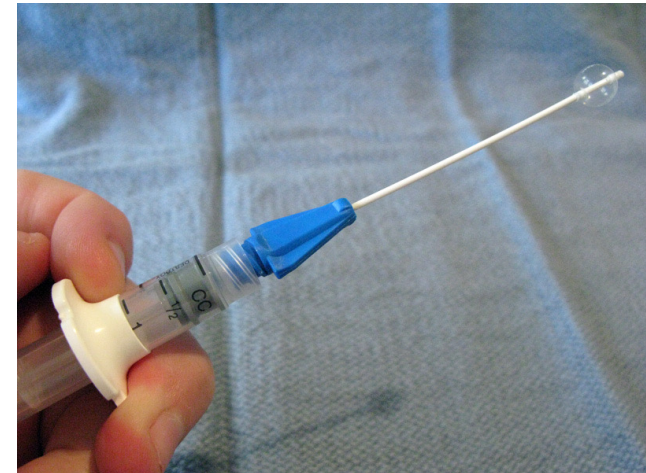
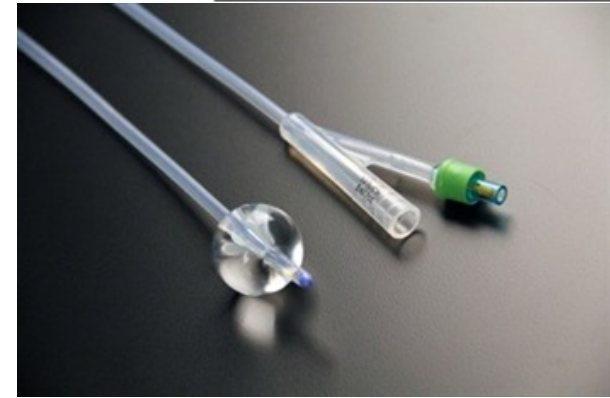
The Pediatric Urgent  
Care Conference



By **PM** Pediatric  
Care

# Catheter Techniques

- Foley catheter/Balloon (Katz<sup>®</sup>) Extractor
  - Slide uninflated balloon past the foreign body laterally
  - Inflate balloon
  - Withdraw catheter gently
- Most effective in nasal foreign body
- Preferred approach when foreign body is posterior



The Pediatric Urgent  
Care Conference



by **PM** Pediatric  
Care

# Instruments

- Graspable objects

- Forceps
- Alligator clamps

- Round objects

- Curette
- Hooked needle

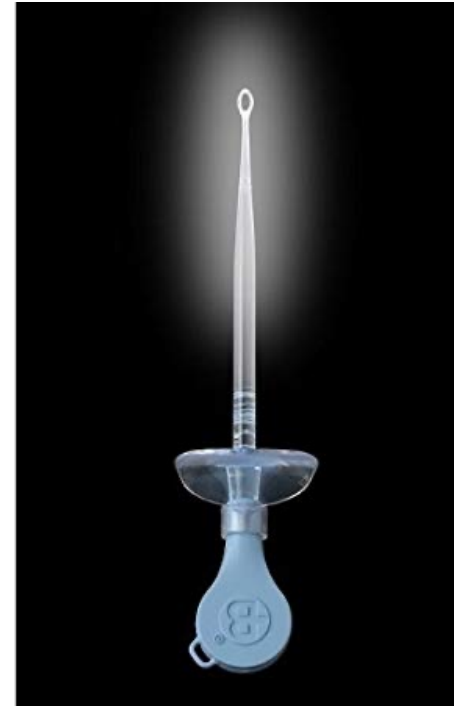- Less useful with friable objects

- Risk abrasion/perforation



# Curette


- Useful for small superficial foreign bodies
- Stabilize hand on patient's head
- May be plastic, metal or lighted!



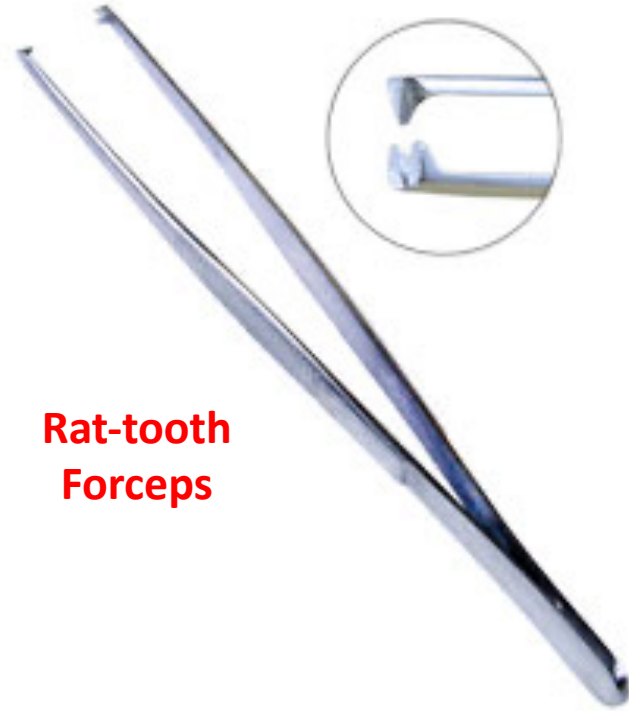
The Pediatric Urgent  
Care Conference



# Right-angle Hook



# Tools of the trade!



**Rat-tooth  
Forceps**



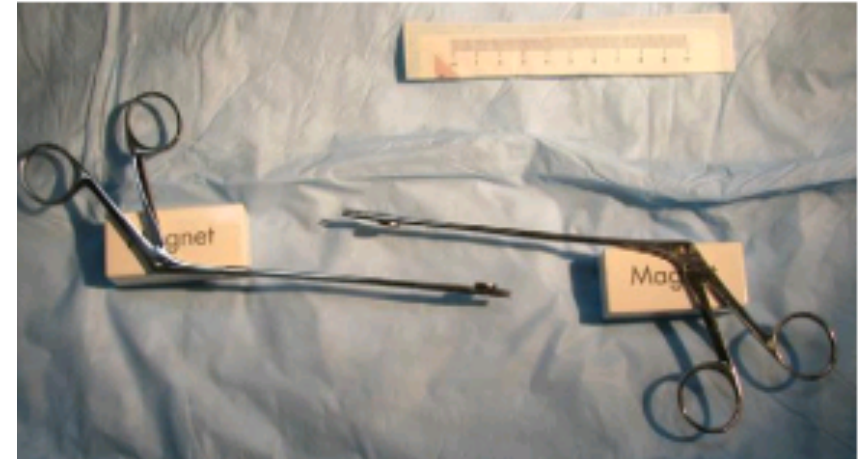
**Fine-tip Alligator Clamp**

The Pediatric Urgent  
Care Conference



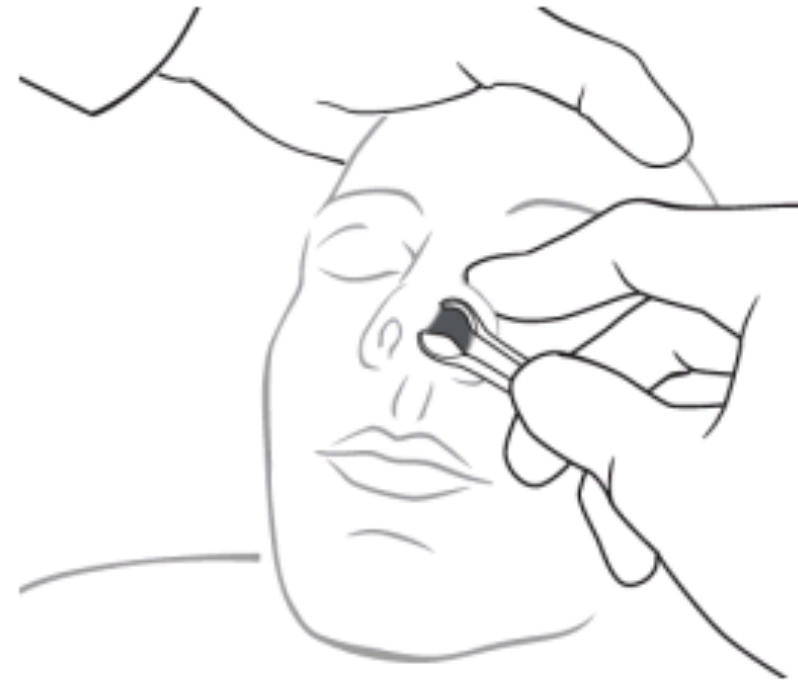# Magnets as tools!

- May trial for removal of metal objects
- Mechanics pick-up tools
- Strong “rare-earth” magnets
  - May be used to magnetize a metal tool
- Insert magnetized tool tip into nose or ear to retrieve object



# Post Removal

- Always inspect for additional foreign bodies
- Examine for trauma and consider prophylactic antibiotic drops



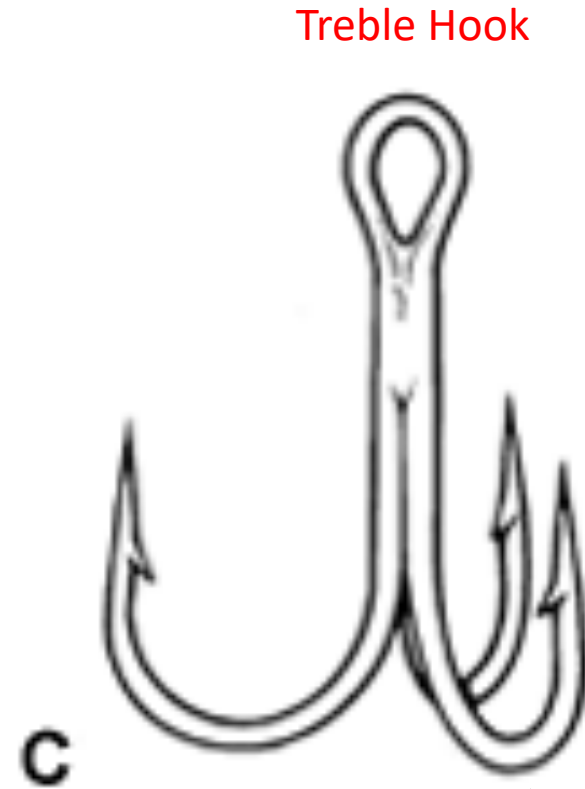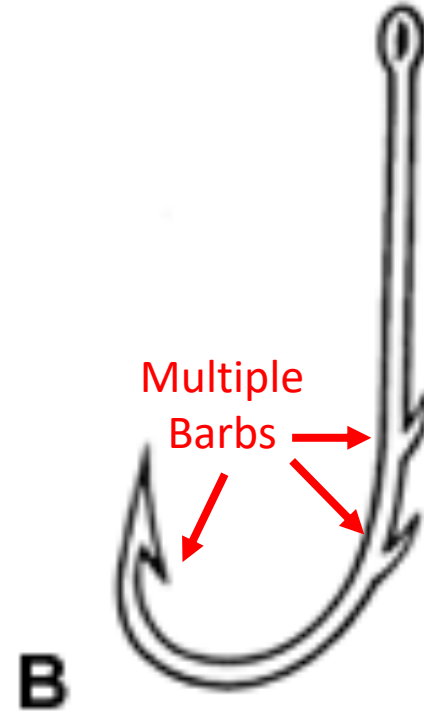
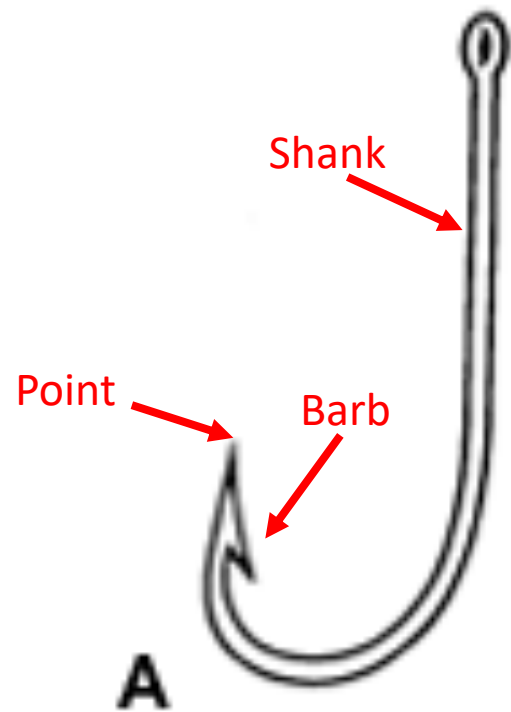
DRIVING **CHANGE 2023**  
THE URGENT CARE CONVENTION

Fish Hooks!!

The Pediatric Urgent  
Care Conference

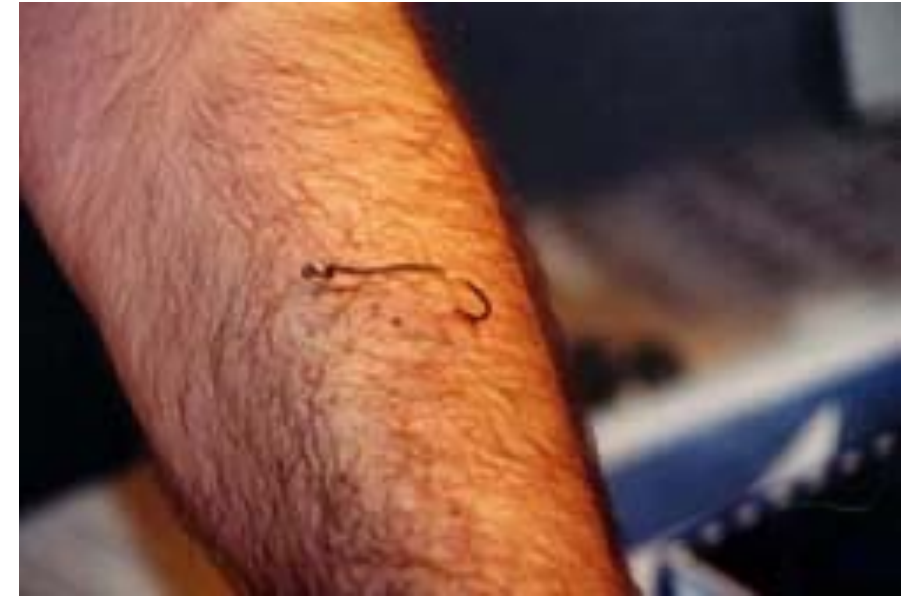**PUCC** @ UCA  
By **PM** Pediatric  
Care

# Fish Hook Anatomy



# Fish Hook Removal

- Most commonly foot or finger
- Barb prevents easy removal
  - “Disengagement” of barb essential
- No trial to compare methods
- Preparation
  - Remove multiple hooks/lure
  - Sterilize skin

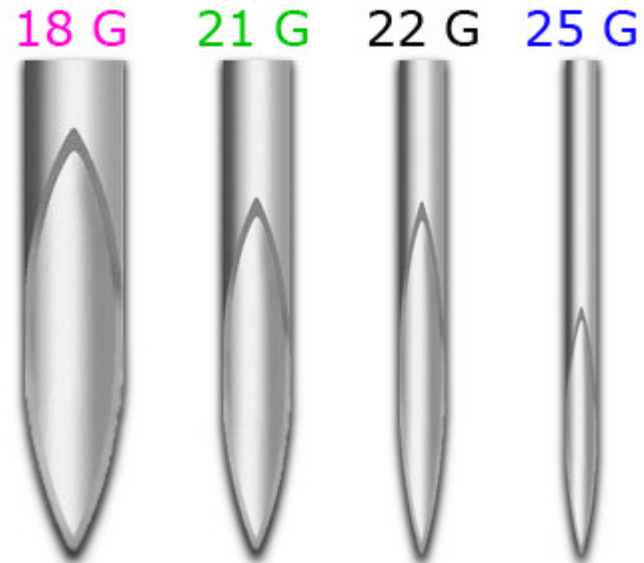


The Pediatric Urgent  
Care Conference



# Fish Hooks Removal Tools

- Wire cutter
  - Bolt-cutter if heavier gauge
- Line
- Needle



# Fish Hook Removal Techniques

- Push-through
- String technique
- Needle technique

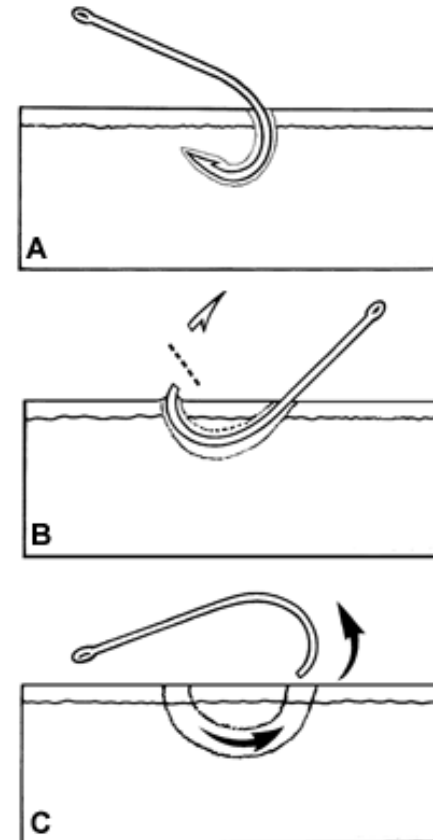


The Pediatric Urgent  
Care Conference



# Push-through Hook Removal

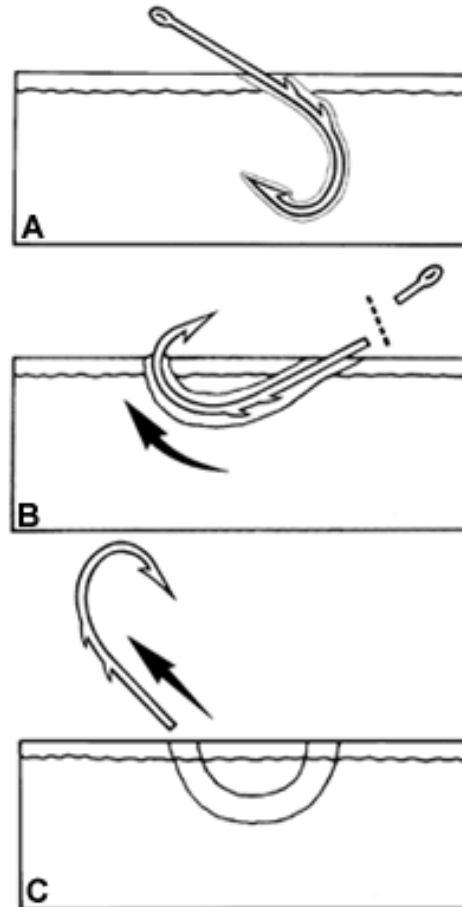
- Effective **when hook point near surface**
  - Significant tissue injury if deep
- Anesthesia
  - Digital block
  - Local infiltration around point of hook
- Advance point of hook through skin
- Clip off barb
- Back out hook through entry point



The Pediatric Urgent  
Care Conference



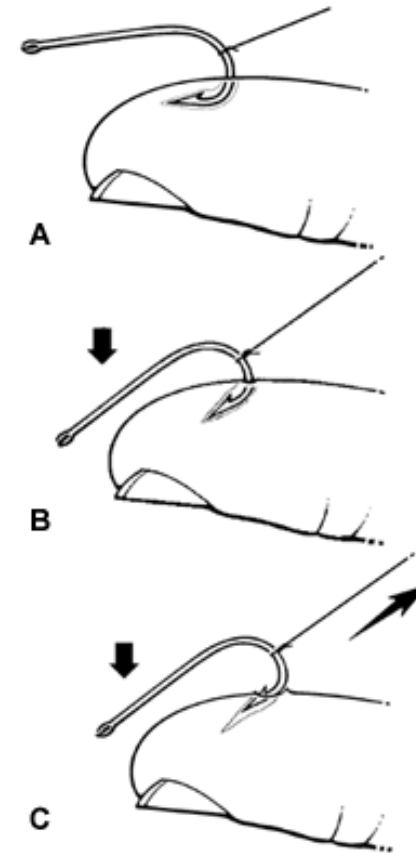
# Modified Push-through Barbed Hooks



← Backing out hook with the barbs would cause more damage!

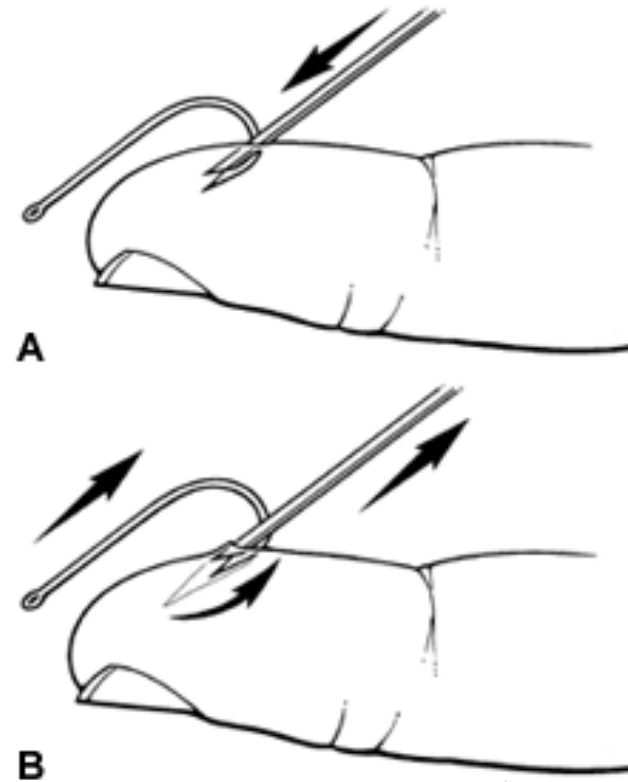
# String Technique

- **Deeply embedded hooks**
- Field technique
  - Rapid
  - Painless
  - Lack of specialized tools
- No anesthesia needed
- Secure the body part
- Take care, hook may fly!



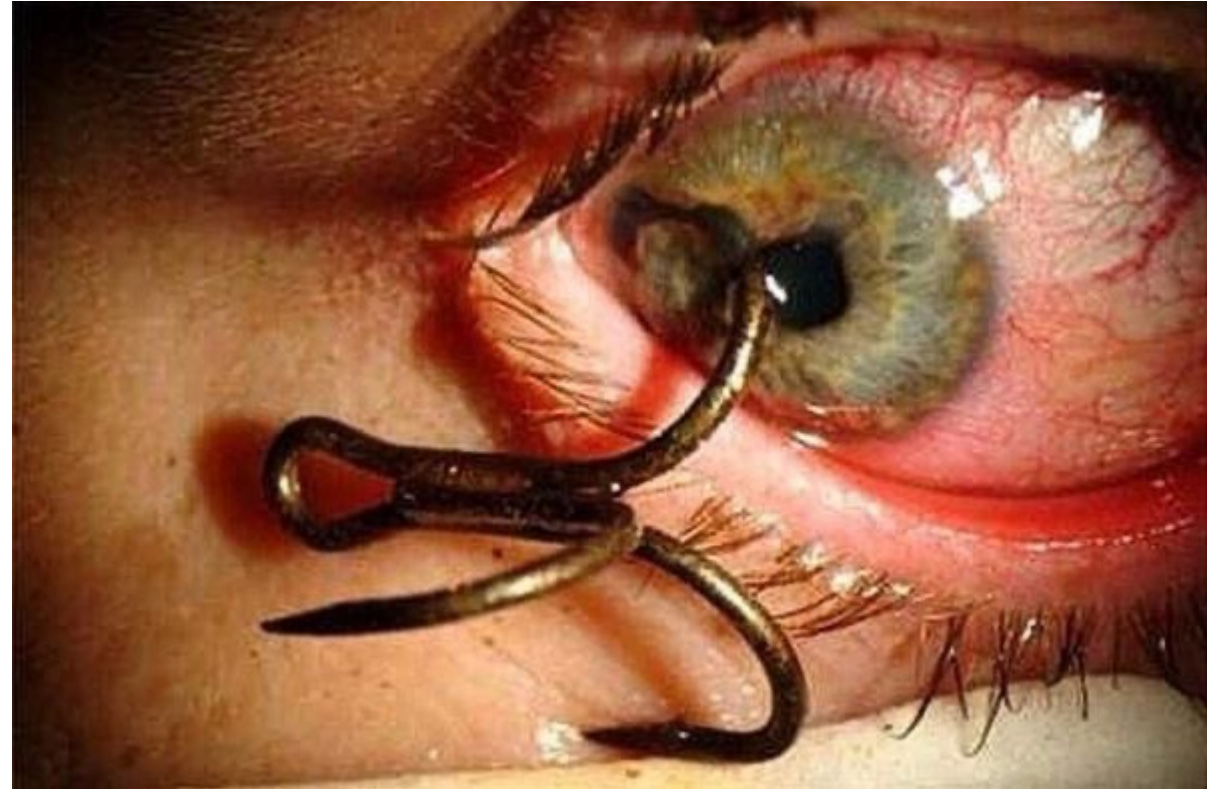# Needle Technique

- Useful in medical setting
- Superficial hooks
  - Difficulty to get onto barb if deep
- Anesthesia
  - Digital block
  - Local infiltration
- Use of 18-gauge needle to cover the barb and back out
- **Less commonly used technique**



# Fish Hook Removal –Refer

- Ocular
- Vascular areas
- Genitals



The Pediatric Urgent  
Care Conference



LET'S PRACTICE

DRIVING **CHANGE2023**  
THE URGENT CARE CONVENTION



The Pediatric Urgent  
Care Conference

**PUCC** @ UCA  
by **PM** Pediatric  
Care

DRIVING **CHANGE2023**  
THE URGENT CARE CONVENTION

# Skills Stations

The Pediatric Urgent  
Care Conference

**PUCC** @ UCA  
By **PM** Pediatric  
Care

## How you can drive change:

- Always **re-examine** for a second foreign body!
- Choose **most-likely** successful technique first
- Consider **aspiration risk** in nasal foreign bodies

DRIVING **CHANGE2023**

# Session Evaluation

- Your feedback is valuable, take a moment to complete the survey for this session.
- To claim CME, you must complete a separate survey available after the convention.

\* How likely are you to recommend this **content** to a colleague?

Not likely at all                      Neutral                      Extremely likely

0   1   2   3   4   5   6   7   8   9   10

What did you find most valuable about this **content**?

What would have made this **content** better?

# Thank you!

- Richard Bruckner, M.D.
- [rbruckner@pmpediatrics.com](mailto:rbruckner@pmpediatrics.com)

The Pediatric Urgent  
Care Conference

